

## Radiologic imaging of acute pancreatitis

Mojca Glušič, Erika Brenčič, Peter Popovič

*Clinical Radiology Institute, University Clinical Centre Ljubljana, Slovenia*

---

**Background.** Acute pancreatitis comprises a broad spectrum of inflammatory changes in the gland and has a variety of causes. The most common are alcoholism and biliary tract disease.

This paper discusses the current concepts of diagnosis and the relationship between morphology as depicted by imaging, pancreatic function tests and treatment planning.

**Conclusions.** Our understanding of the morphologic changes produced by the inflammatory process has expanded in the last decade as more sophisticated imaging techniques have been used for evaluation.

*Key words:* pancreatitis - radiography; acute disease

---

### Introduction

Pancreatitis is defined and classified according to clinical, morphologic and histological criteria. Acute pancreatitis is defined as an acute inflammatory process of the pancreas, caused by activation of the proteolytic enzymes within the gland.<sup>1</sup>

The most common etiologic factors of acute pancreatitis are cholelithiasis and alcohol abuse, the others are rarer (trauma, surgery, ERCP, viral and bacterial infections, pancreatic tumours, drugs, hyperlipoproteinemia, primary hyperparathyroidism, idiopathic).

Received 3 November 2004

Accepted 17 November 2004

Correspondence to: Mojca Glušič, MD, Clinical Radiology Institute, University Clinical Centre Ljubljana, Slovenia, SI-1525 Ljubljana, Slovenia; Phone: +386 1 522 85 30.

The clinical spectrum of acute pancreatitis varies from mild to severe disease.

Mild acute pancreatitis is the most common form of the disease, and is characterized macroscopically by interstitial - oedematous inflammation of the gland. Microscopic findings include infiltration of the interstitial space with leukocytes, occasional small scattered foci of acinar cell necrosis, and both intra- and peripancreatic fat necrosis. Patients with mild pancreatitis typically present with sudden abdominal pain and tenderness. Fever and leukocytosis may be present.

Patients with severe acute pancreatitis may initially experience symptoms similar to those in mild disease, but often the pain is worse and they often show additional clinical and laboratory evidence of systemic dysfunction and multisystem failure. The length of hospitalization is longer and may be complicated by hypotension, pulmonary insufficiency, renal failure, gastrointestinal bleeding,

metabolic acidosis, hypocalcaemia, disseminated intravascular coagulation, and sepsis.<sup>1,2</sup>

### Clinical diagnosis

The clinical diagnosis of acute pancreatitis is straightforward when patients present with appropriate symptoms and when laboratory findings are confirmatory. Diagnostic difficulties arise when patients present with non-specific symptoms that mimic other acute abdominal conditions or when laboratory tests are non-diagnostic. Serum amylase and lipase levels represent the most commonly used laboratory tests to diagnose pancreatitis. These test values are imperfect disease indicators, however, because they may be normal in up to 10% of patients. Serum amylase increase is not specific for acute pancreatitis, the height of serum amylase and/or lipase does not correlate with the severity of pancreatitis.<sup>2,3</sup>

Objective assessment of the severity of an acute attack of pancreatitis is critical to patient management, because the clinician must be able to differentiate mild acute (interstitial) pancreatitis from severe acute (necrotizing) pancreatitis. Approximately 50% of patients present with mild acute pancreatitis and require only minimal supportive therapy and limited hospitalization. Mortality is rare in this group unless a serious complication occurs or the disease evolves into a more severe form. Patients with severe acute pancreatitis have mortality rates of 10-20%, with death often due to shock associated with early respiratory and renal failure or sepsis.

High-risk patients who may benefit from aggressive clinical and surgical management must therefore be identified.

Disease severity can be evaluated objectively using the Ranson criteria:

- At admission:

Age over 55 years

White cells over 16000/ mm<sup>3</sup>

Blood glucose over 11 mmol/l

LDH over 5.83ukat/l (350UI/l)

AST over 2.0 ukat/l (250UI/l)

- During initial 48h:

Hematocrit decrease over 10%

Blood urea increase over 5 mg/100 ml

Calcium less than 8 mg/100 ml (2 mmol/l)

PO<sub>2</sub> less than 8 kPa (60 mm Hg)

Base deficit over 4 mmol/l (mEq/l)

Fluid deficit over 6000 ml

Three or more Ranson criteria depicted during first 48 hours indicate severe acute pancreatitis. Patient with six or more Ranson criteria is very likely to die.

### Radiologic diagnosis

The primary roles of radiologic imaging in patients with suspected pancreatitis are:

- to confirm or exclude the clinical diagnosis of acute pancreatitis,
- to determine, if possible, the cause of the disease,
- to stage disease severity,
- to detect complications,
- to provide imaging guidance for percutaneous therapy.

Contrast-enhanced CT is the imaging modality of choice for evaluating patients with acute pancreatitis.<sup>2-5</sup> It can accurately diagnose and stage the disease as well as provide the necessary information for percutaneous management. Sonography, endoscopic retrograde cholangiopancreatography, and angiography play secondary roles. Ultrasound is primarily used to detect biliary stones and to follow the size of pancreatic fluid collections and pseudocysts. Diagnostic endoscopic retrograde cholangiopancreatography is seldom performed during acute attacks of pancreatitis, because it may exacerbate the disease or introduce infection. Endoscopic retrograde cholangiopancreatog-

raphy with sphincterotomy may be performed to alter the course of disease in patients with suspected biliary pancreatitis. Angiography is reserved for diagnosis and treatment of vascular complications.<sup>4</sup>

The value of MRI in acute pancreatitis remains to be established. Thus far, it has not been widely applied in the care of patients with acute pancreatitis, though it can be used in patients unable to receive iodinated contrast media.<sup>6,8</sup>

On conventional SE and GRE T1-weighted images, the normal pancreas is approximately isointense with the liver. On T2-weighted images the normal pancreas is moderately hyperintense compared with the liver. T1-weighted breath hold images after bolus injection of extracellular contrast agent (gadolinium) show intense parenchymal enhancement which peaks before the arrival of contrast in the superior mesenteric vein, and fades fairly quickly. The liver-specific contrast medium manganese-DPDP is also taken up by the pancreatic exocrine tissue, where it produces an increase in signal intensity on T1-weighted images.

Oedema of the pancreas causes diffuse signal reduction on T1-weighted images and reduced enhancement after intravenous contrast agent. In more severe cases unenhanced gradient echo T1-weighted images may show peripancreatic oedema as areas of low signal extending into the fat surrounding the gland. Dynamic post-contrast acquisition is a sensitive method for demonstrating the presence and extent of pancreatic necrosis, shown as areas of diminished or absent parenchymal enhancement. Exudate and fluid collections within or around the pancreas can be seen on T1, but are also well shown on T2-weighted images, where they appear as areas of high signal intensity. T2-weighted images also give a clear distinction between the fluid and solid components of localized exudates and pseudocysts. This is important in patients who are candidates for percutaneous

drainage of pancreatic collections, which often appear as areas of homogeneous low attenuation on computed tomography even when the collection is mostly solid. Because of the high sensitivity of gradient echo images to susceptibility effects produced by fresh bleeding, the presence of a hemorrhagic component in acute pancreatitis is probably detectable more readily and over a longer time course by MR than by CT, although the clinical value of this finding is still uncertain.

#### *MRCP - MR cholangiopancreatography*

MRCP provides a non-invasive alternative to diagnostic ERCP, particularly useful in patients in whom ERCP is technically difficult or unsuccessful (e.g. following gastric or pancreatic surgery, or in patients with tight strictures of the main duct).

MRCP relies on extreme T2 weighting which effectively eliminates signal from all tissues except stationary free water protons, so that the images display only those structures containing localized fluid collections. With careful selection of the imaging volume, a demonstration of the pancreatic duct and the main bile ducts can be obtained.

MRCP has the advantage of being completely non-invasive, however it does not offer the opportunity to carry out therapeutic procedures, it is also contraindicated in patients with metallic clips or stents, with exception of titanium, relatively lower resolution also limits the demonstration of branch ducts, except when they are evidently dilated.

CT should be performed at the peak of pancreatic arterial perfusion using thin-section (5 mm or less) scanning.

CT finding of mild acute pancreatitis is a slight to moderate increase in the size of the pancreas. Although pancreatic enlargement is typically diffuse with associated contour irregularity, it can be segmental, most commonly involving the head. As disease severity increases, evidence of peripancreatic inflam-

matory stranding is seen, manifesting as increased density to the surrounding fatty tissue, thickening of the peripancreatic fascial planes, and heterogeneity of the pancreatic parenchyma. Rupture of the secondary pancreatic ductules leads to both intra- and extravasation of pancreatic secretions. In such cases, CT reveals both intrapancreatic and peripancreatic fluid collections. They are composed of blood, pancreatic enzymes, fluid, and debris. Acute collections have fluid density, lack an inflammatory capsule or wall, and are confined by the anatomic space in which they form. They are most commonly seen adjacent to the pancreas in the anterior pararenal space and the lesser sac. Extensive collections may spread throughout the peritoneal cavity, and may dissect as far as the neck, pericardium, pleura, mediastinum, and groin. Solid organ involvement within the hilar regions of the spleen, kidneys, and liver can also occur.

Pancreatic necrosis is defined as focal or diffuse areas of unenhancing, nonviable pancreatic parenchyma. Regions of necrosis show no or diminished enhancement. In a large series of patients who underwent both CT and surgery, Berger et al. showed CT to have an overall accuracy of 87% in diagnosing necrosis. CT specificity was 100% when necrosis involved more than 30% of the gland. A 21% false-negative rate was seen in patients with minor (less than one third) necrosis, which fell to 11% in those patients with major (greater than 50%) necrosis.<sup>4</sup>

#### *Local complications of acute pancreatitis*

Acute fluid collections may be seen in 40 - 50% of patients with acute pancreatitis. Approximately 50% are small and resolve spontaneously. Collections which persist may evolve into pancreatic pseudocysts, a process requiring at least 4 weeks.

Pseudocysts are encapsulated collections which appear marginated on CT because of a

nonepithelialized inflammatory fibrous wall or capsule. Approximately half of all pseudocysts resolve spontaneously, especially uninfected pseudocysts less than 5 cm in diameter. Those which do not may either stabilize or decrease slightly in size, remaining clinically asymptomatic, or they may enlarge and cause complications. Major pseudocyst complications shown by CT include arterial pseudoaneurysm formation, with or without cyst hemorrhage, superinfection (suggested by air within the cyst), venous occlusion (suggested by perigastric and mesenteric varices), biliary and gastrointestinal tract obstruction, and solid organ invasion.

#### *Local septic complications*

Sterile necrosis, defined as pancreatic necrosis without infection, must be differentiated from both infected necrosis and pancreatic abscess. The mortality of infected necrosis (39-67%) is significantly greater than that associated with sterile necrosis (13-14%) These entities may be distinguished if evidence of bacterial infection is obtained by CT-guided fine-needle aspiration.<sup>9</sup> Accurate differentiation of infected pancreatic necrosis from pancreatic abscess is also essential. Infected necrosis carries a much higher morbidity and mortality than does pancreatic abscess.<sup>9</sup>

Pancreatic abscess is a localized collection of pus located near the pancreas. In contrast to infected necrosis, which can develop at any time during the course of acute pancreatitis, pancreatic abscesses typically present 4 weeks or more after the onset of symptoms. A pancreatic abscess may be diagnosed by CT if a fluid collection containing liquid pus is identified adjacent to a normally enhancing pancreas.

Pancreatic ascites presents as free intraperitoneal fluid containing high amylase levels. It is usually seen in more severe forms of pancreatitis, only rarely in association with a normal-appearing pancreas.

Pancreatic haemorrhage may be seen in cases of traumatic pancreatitis, as well as in cases of severe acute pancreatitis where significant hemorrhagic had necrotizing components coexist.

Besides local complications severe forms of acute pancreatitis are often accompanied by systemic complications - hypotension, pulmonary insufficiency, renal failure, gastrointestinal bleeding, metabolic acidosis, hypocalcaemia, disseminated intravascular coagulation, sepsis.

*Staging of acute pancreatitis<sup>2-5,9</sup>*

CT scan provides important information in accordance with the Balthazar-Ranson criteria of severity, where inflammatory process and gland necrosis are separately graded.

Inflammatory process (a):		
Grade A Normal pancreas		0
Grade B Focal or diffuse enlargement of pancreas		1
Grade C Pancreatic and peripancreatic inflammatory changes		2
Grade D Single fluid collection		3
Grade E Two or more fluid collections and/or the presence of gas in/or adjacent to pancreas		4

Gland necrosis (b):	
No necrosis	0
Less than 30%	2
30-50%	4
Greater than 50%	6

CT severity index (CTSI): a+b.

Patients with a CTSI of 0-3 show a 3% mortality rate and an 8% morbidity rate, whereas in patients with a CTSI of 7-10, mortality and morbidity rates are 17 and 92% (Figure 1).

CT retains a disadvantage of exposure to x rays, which is of importance in younger patients and in patients in whom CT examination is repeated.

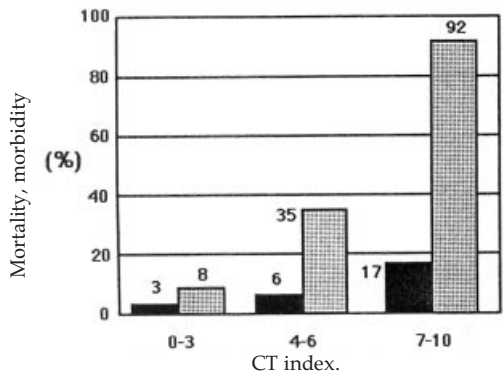
Value of CT examination is limited in patients, in whom intravenous contrast agent is contraindicated, due to severe renal insufficiency or allergy.

In patients with suspected severe acute pancreatitis, early CT study is suggested by many authors for confirmation of the diagnosis and detection of severity of disease. It should be done within 24-48 hours from the beginning of the disease. CT should be repeated in 7-8 days, or earlier in case of clinical deterioration.

**Conclusions**

Pancreatic necrosis, depicted by CT scan, and peripancreatic inflammatory collections are the two prognostic indicators of severity of acute pancreatitis. The most serious complications develop in patients with peripancreatic collections and some of these patients die. Such complications occur mostly in individuals with associated early or late pancreatic necrosis. In most individuals fluid collections tend to resolve spontaneously if the pancreas maintains its integrity.

The limitations of the early CT examination are related to potential development of complications in patients with a normal pancreas, as well as to the development of late pancreatic necrosis in these individuals. For these reasons, patients with peripancreatic



**Figure 1.** Mortality, morbidity according to CT index.

fluid collections, pancreatic necrosis, or both should undergo follow-up CT examination in 7-8 days or earlier if their clinical condition deteriorates.

To improve the prognostic accuracy of the initial CT examination, a CT severity index, based on combined assessments of peripancreatic inflammatory collections and degree of pancreatic necrosis, was developed.

Patients with a high CT severity index (7 to 10 points) showed a 92% morbidity and a 17% mortality, whereas those with a low severity index (0 to 3 points) had 3% morbidity and no mortality.

Detection of pancreatic necrosis, either at the first examination or at follow-up study, or a high CT severity index at the initial CT examination are ominous predictive indicators of severe pancreatitis, which enable the radiologist to identify a group of patients in whom most life-threatening complications will occur.

### References

1. Kocijančič A, Mrevlje F. *Interna medicina*. Ljubljana: DZS; 1993. p. 408-10.
2. Banks PA. Practice guidelines in acute pancreatitis. *Am J Gastroenterol* 1997; **92**: 377-83.
3. Balthazar EJ, Robinson DL, Megibow AJ, et al. Acute pancreatitis: Value of CT in establishing prognosis. *Radiology* 1990; **174**: 331-6.
4. Balthazar EJ, Freeny PC, van Sonnenberg E. Imaging and intervention in acute pancreatitis. *Radiology* 1994; **193**: 297-306.
5. Elmas N. The role of diagnostic radiology in pancreatitis. *Eur J Radiol* 2001; **38**: 120-32.
6. Semelka RC, Ascher SM. MR imaging of the pancreas. *Radiology* 1993; **188**: 593-602.
7. Kumbasar B, Acunas B. Interventional radiology in inflammatory pancreatic disease. *Eur J Radiol* 2001; **38**: 133-6.
8. Ito K, Koike S, Matsunaga N. MR imaging of pancreatic diseases. *Eur J Radiol* 2001; **38**: 78-93.
9. Birnbaum BA. *Imaging in acute pancreatitis. Radiology of the liver, biliary tract, and pancreas, categorical course syllabus American Roentgen Ray Society*. San Diego: 1996. p. 151-6.