

Anafilaktični šok po Ranitidinu – poročilo o primeru

Anaphylactic shock after Ranitidine – a Case report

Avtor / Author
Ustanova / Institute

Tadej Željko¹, Andreja Sinkovič^{2,3}

¹Univerzitetni klinični center Maribor, Klinika za interno medicino, Oddelek za kardiologijo in angiologijo, Maribor, Slovenija; ²Univerzitetni klinični center Maribor, Klinika za interno medicino, Oddelek za intenzivno interno medicino, Maribor, Slovenija;

³Univerza v Maribor, Medicinska fakulteta, Maribor, Slovenija

¹University Clinical Centre Maribor, Department of cardiology and angiology, Maribor, Slovenia; ²University Clinical Centre Maribor, Clinic for Internal Medicine, Department of Intensive Care Medicine, Maribor, Slovenia; ³University of Maribor, Faculty of Medicine, Maribor, Slovenia

Ključne besede:
anafilaksa, ranitidin, anafilaktični šok, alergija.

Key words:
anaphylaxis, ranitidine, anaphylactic shock, allergy

Članek prispel / Received
18.11.2009

Članek sprejet / Accepted
15.03.2010

**Naslov za dopisovanje /
Correspondence**

Tadej Željko
Univerzitetni klinični center Maribor,
Oddelek za kardiologijo in angiologijo,
Ljubljanska 5, SI–2000, Maribor,
Slovenija
Telefon +386 41377158
E-pošta: tadejzeljko@yahoo.com

Izvleček

Namen: Anafilaktični šok je huda, nepričakovana, potencialno življenjsko nevarna sistemska preobčutljivo-stna reakcija. Najpogostejši vzročni alergeni so določena hrana, piki žuželk in zdravila. Ranitidin je varno zdravilo in se uporablja v anafilaksi za zmanjšanje kožnih sprememb, v redkih primerih pa lahko ranitidin povzroča celo anafilakso in anafilaktični šok.

Poročilo o primeru: Predstavljamo primer 30-letne bolnice, zdravljen z enim odmerkom ranitidina iv. zaradi bolečin v trebuhu. Že v nekaj minutah je prišlo do simptomov in znakov anafilaktičnega šoka. Takojšnje zdravljenje z iv. injekcijo adrenalina, infuzijo tekočin, iv. hidrokortizonom in iv. klemastinom se je pričelo že na terenu. Po sprejemu v enoto intenzivne terapije se je zdravljenje nadaljevalo, vključevalo

Abstract

Purpose: Anaphylactic shock is a severe, unexpected, life-threatening generalized hypersensitivity reaction that is usually triggered by antigens such as food, venom or drugs. Among drugs, ranitidine is considered safe and is even used in allergic reactions to decrease skin rash. However, in rare cases, ranitidine can provoke anaphylaxis or even anaphylactic shock.

Case report: We present the case of a 30-year-old woman with abdominal pain, treated with i.v. bolus of ranitidine after previous occasional oral ranitidine ingestion. Within minutes, she developed symptoms and signs of anaphylactic shock. Immediate treatment was initiated with i.v. adrenaline, fluid infusion, and i.v. hydrocortisone and clemastine. After admission to the intensive care unit, treatment was continued, including

pa je tudi vazopresorje. Zaradi respiracijske insuficience sta bila potrebna intubacija in umetno predihavanje. Po 2 dneh se je stanje popolnoma popravilo, po odstranitvi tubusa pa je oseba spontano zadihala, ni imela potreb po dodatku kisika in je bila odpuščena domov v nekaj dneh brez kakršnih koli posledic.

Zaključek: Zaključujemo, da lahko celo ranitidin, ki se že leta uporablja kot varno, preizkušeno in vsem dostopno zdravilo, sproži anafilakso in/ali anafilaktični šok. Takrat je za rešitev bolnika potrebno ukrepati z vazopresorji, intubacijo in umetnim predihavanjem.

i.v. vasopressors. Intubation and mechanical ventilation were needed because of acute respiratory failure. After 2 days, the situation resolved completely. After she was extubated, the patient could breathe spontaneously without the need for additional oxygen. She was discharged without any sequelae within a few days.

Conclusion: We conclude that even ranitidine, which has been used safely for many years, can trigger anaphylaxis and/or anaphylactic shock. In cases of anaphylactic shock, treatment with vasopressors, intubation and mechanical ventilation is needed to preserve life.

INTRODUCTION

Anaphylactic shock is a severe, unexpected, life-threatening generalized hypersensitivity reaction that is characterized by rapid airway, breathing and/or circulatory problems, associated with skin rash or mucosal changes. The most common triggers are food allergens, venom and drugs (1, 2). The drugs used for treatment of anaphylaxis are considered safe. However, they can also trigger anaphylaxis or even anaphylactic shock.

Ranitidine is among the most commonly used drugs. Upper gastrointestinal tract ulcer and reflux disease are the main indications for its use. It is also recommended for prolonged allergic reactions with skin rash, for which *i.v.* administration of ranitidine shortens disease duration (4). However, during recent years, ranitidine has been replaced in the majority of cases by proton pump inhibitors (PPIs). In spite of widespread use of PPIs, ranitidine is still used frequently because it is cheap, considered safe, and is available over the counter.

However, sporadic anaphylactic reactions to ranitidine have been reported. We present a patient with anaphylactic shock after *i.v.* administration of ranitidine.

Case report

A 30-year-old woman without a previous history of allergy was suffering from dyspepsia and abdomi-

nal pain for 3 weeks. Occasionally, she took oral ranitidine (150 mg Ranital; Lek). This treatment was unsuccessful. Therefore, she was treated regularly by esomeprazole (40 mg Nexium; AstraZeneca UK Limited) instead of ranitidine for 1 week (without combining the drugs), but dyspepsia and epigastric pain persisted. On the day of admission, she had an episode of abdominal pain that lasted for several hours, despite combined treatment with oral ranitidine and esomeprazole. As a consequence, *i.v.* ranitidine was given as a single bolus dose. Within minutes, the patient developed symptoms and signs of anaphylactic shock, which consisted of pallor, sweating, breathing difficulties, and hypotension. Finally, she collapsed. When the emergency medical team arrived on the scene, they started treatment with *i.v.* adrenalin (Suprarenin; Sanofi-Aventis), *i.v.* fluid infusion (crystalloids and colloids), hydrocortisone (Solucortef; Pfizer Luxemburg), histamine antagonist clemastine (Tavegil; Medis), and bronchodilators fenoterol bromide and ipratropium bromide (Berodual; Boehringer Ingelheim).

She was transferred to the emergency department, where her blood pressure was 70/50 mm Hg, and pulse oximetry showed hemoglobin saturation of 85% (receiving oxygen by Ohio mask). Treatment was continued with *i.v.* clemastine 4 mg, *i.v.* methylprednisolone 250 mg (Solu-Medrol; Pfizer Luxemburg), bronchodilator inhalation, and *i.v.* fluid infusion. She was admitted to the intensive care unit (ICU).

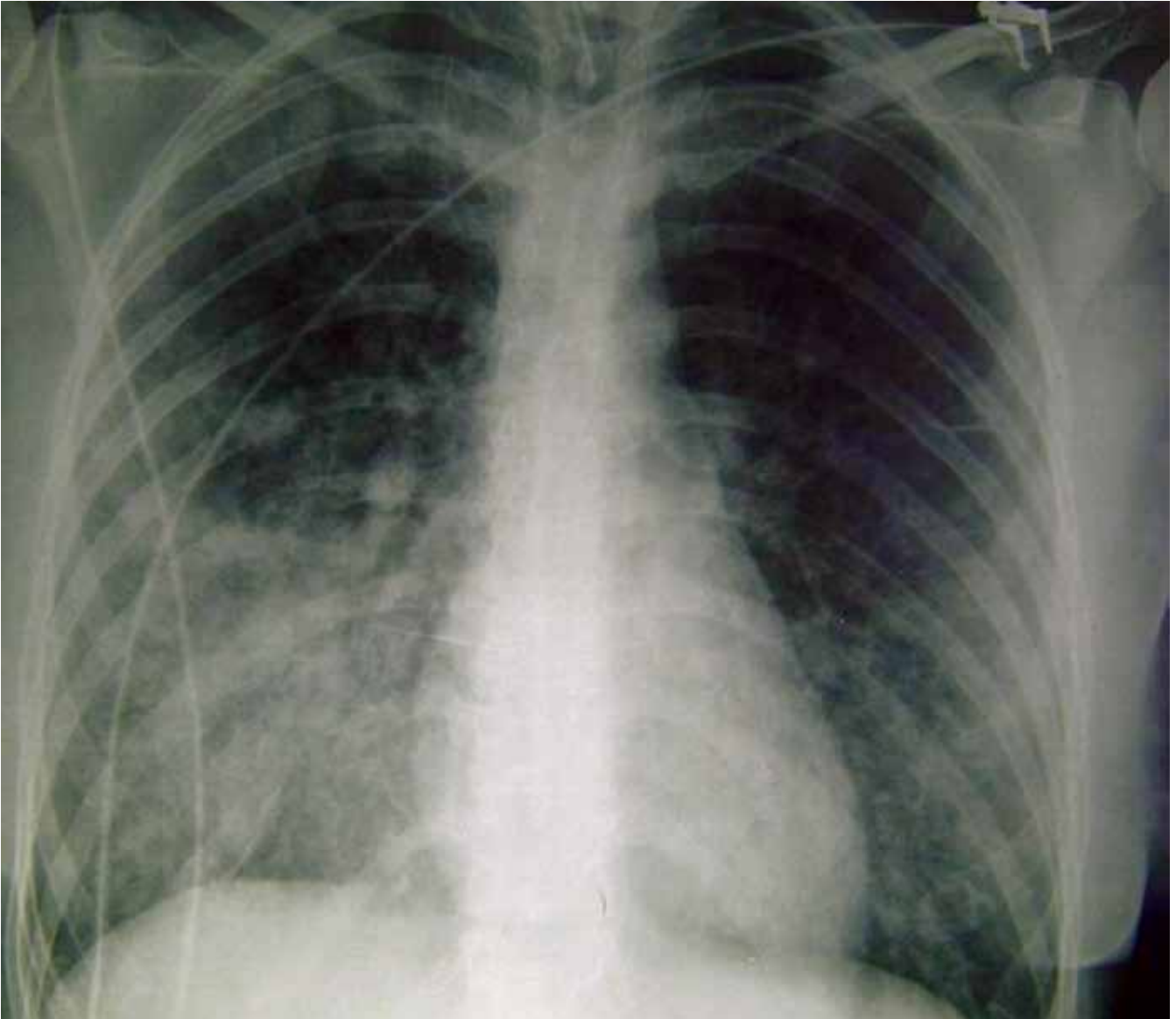


Figure 1. Chest radiography on admission to ICU.

On admission, noninvasive blood pressure was 90/? mm Hg, and pulse rate was 120/min. She was breathing spontaneously. Treatment was continued with i.v. fluids and noradrenaline (Arterenol; Sanofi-Aventis Deutschland GmbH), at a maximum dose of 0.74 µg/kg/min. In the first 24 h, she received 3000 ml crystalloids and 1500 ml colloids [1000 ml 6% Haes 130/0.4 and 500 ml poly (O-2-hydroxyethyl starch)].

ECG showed sinus tachycardia. Laboratory tests on admission were as follows: leukocytosis ($23.07 \times$

$10^9/l$; normal: 4×10^9 – $10 \times 10^9/l$), increased serum lactate (3.6 mmol/l; normal: 0.63–2.44 mmol/l), brain natriuretic peptide (BNP) (260 pmol/l; normal: ≤ 20 pmol/l), and C-reactive protein (21 mg/l; normal: 0–5 mg/l). Other tests were within normal limits.

After admission to ICU, the patient vomited and started to cough heavily. To protect the airway, she was intubated. Simultaneously, acute respiratory failure, with a respiratory index (pO_{a_2}/FiO_2) of 169

was observed. She was mechanically ventilated (FiO₂ 100%, positive end-expiratory pressure 10 cm H₂O, tidal volume 440 ml, respiratory rate 21 breaths/min, continuous mandatory ventilation). On chest radiography, bilateral lung congestion and alveolar edema were observed (Fig. 1). Unfortunately, echocardiography was not performed. In the following hours, the patient received i.v. pantoprazole (Controloc; Nycomed GmbH) to prevent stress ulceration due to known dyspepsia and gastric discomfort. Antibiotic therapy with amoxicillin and clavulanic acid (Amoksiklav; Lek) was started for suspected aspiration pneumonia. After 2 days, the patient was stable, and vasoactive therapy could be gradually discontinued. Respiratory failure improved. She was breathing spontaneously and was extubated.

Full recovery was observed within a week. She was discharged from hospital without any sequelae and unchanged performance status. Further outpatient gastroenterological evaluation was suggested, but refused by the patient until now.

DISCUSSION

Our case warns that anaphylactic shock is possible after administration of ranitidine in spite of previous uneventful sporadic oral treatment with the same medication.

Ranitidine, binding to H₂-receptors and competitively antagonizes the effects of histamine, and consequently, decreases gastric juice secretion, and is well tolerated. Side effects are rare and occur in only 1–2% of cases. Life-threatening side effects such as anaphylaxis and anaphylactic shock have been reported sporadically (5–8). In a large observational clinical study including 8304 patients during a 13-year period, only two cases of anaphylactic shock after ranitidine were observed (8).

What are the mechanisms for anaphylaxis in ranitidine? Previous case reports and studies have demonstrated that ranitidine stimulates the formation of serum-specific IgE antibody during previous exposure

to ranitidine (9). Repeated exposure to ranitidine results in mast cell and basophil degranulation and release of histamine, prostaglandins and interleukins, which all mediate vasodilatation, smooth muscle contraction, glandular secretion and increased capillary permeability. The result is a typical clinical picture of anaphylactic shock (9). The same course of events was seen in our patient, who took oral ranitidine occasionally some weeks before the event, which suggests prior sensitization to ranitidine.

In our patient, there was no warning sign of urticarial rash. Life-threatening bronchospasm and hypotension occurred and were observed within a few minutes of i.v. ranitidine administration, which necessitated immediate treatment with i.v. adrenaline, fluids, steroids, noradrenaline, intubation, and mechanical ventilation. The presence of urticarial rash is variable. Less than 20% of patients have a rash at the time of anaphylaxis. Bronchospasm is more frequently encountered (33%), and cardiovascular collapse occurs in 86% of cases. The absence of any urticarial rash in our patient gives rise to the suspicion of a possible additional allergenic component in the i.v. ranitidine preparation. However, in the literature, no serious anaphylactic or allergic reactions have been reported for additional components in i.v. ranitidine (sodium hydrogen phosphate dodecahydrate, sodium hydroxide, citric acid monohydrate and water). Unfortunately, ranitidine intradermal tests were not performed, and serum tryptase was not estimated on admission to clarify the event.

The unexpected onset of clinical symptoms and signs in an otherwise fit and healthy young woman coincided with i.v. ranitidine application and a rapid response to treatment was decisive for diagnosis of ranitidine-induced anaphylaxis.

In our patient, we observed an increase of serum BNP to 260 pmol/l. BNP is a hormone that is secreted from cardiac ventricular myocytes as a response to pressure or volume overload. It causes diuresis, natriuresis and vasodilation, and inhibits the sympathetic and renin-angiotensin-aldosterone systems. It is mostly used as

adjuvant marker of heart failure and its prognosis. Clinical studies have demonstrated that levels of serum BNP >400 pmol/l are diagnostic for heart failure. Serum BNP level of 260 pmol/l, as observed in our patient, is not conclusive for the diagnosis of heart failure. Volume overload, various medications, hypoxemia and tachycardia could all have increased BNP in our particular case. Furthermore, heart failure as a possible cause of pulmonary congestion was not likely,

because of the patient's young age, complete lack of any clinical history that was suggestive of heart failure, and the clinical course of fast, complete recovery (10).

Our conclusions are that ranitidine seemed to be associated with life-threatening anaphylaxis after previous sporadic asymptomatic use of ranitidine in our patient. In this case, early treatment was mandatory to preserve life.

REFERENCES

- Johansson SG, Bieber T, Dahl R, Friedmann PS, Lanier BQ, Lockey RF, et al. Revised nomenclature for allergy for global use: Report of the Nomenclature Review Committee of the World Allergy Organization, October 2003. *J Allergy Clin Immunol* 2004; 113: 832–6.
- Soar J, Pumphrey R, Cant A, Clarke S, Corbett A, Dawson P et al. Emergency treatment of anaphylactic reactions – guidelines for healthcare providers. *Resuscitation* 2008; 77: 157–69.
- Sampson HA, Munoz-Furlong A, Campbell RL, Adkinson NF Jr, Bock SA, Branum A, et al. Second symposium on the definition and management of anaphylaxis: Summary report-Second National Institute of Allergy and Infectious Disease/Food Allergy and Anaphylaxis Network Symposium. *Ann Emerg Med* 2006; 47:373–80.
- Lin RY, Curry A, Pesola GR, Knight RJ, Lee HS, Bakalchuk L et al. Improved outcomes in patients with acute allergic syndromes who are treated with combined H1 and H2 antagonists. *Ann Emerg Med* 2000; 36: 462–8.
- Mills JG, Koch KM, Webster C, Sirgo MA, Fitzgerald K, Wood JR. The safety of ranitidine in over a decade of use. *Aliment Pharmacol Ther* 1997; 11: 129–37.
- Rethnam U, Yesupalan RS. Anaphylactic reaction associated with Ranitidine in a patient with acute pancreatitis: a case report. *J Med Case Reports* 2007; 1: 75.
- Thurot-Guillou C, Bourrain JL, Jacquier JP, Beani JC. Anaphylactic reaction to ranitidine and dexchlorpheniramine. *Eur J Dermatol*. 2007; 17: 170–1.
- Demirkan K, Bozkurt B, Karakaya G, Kalyoncu AF. Anaphylactic reaction to drugs commonly used for gastrointestinal system diseases: 3 case reports and review of the literature. *J Investig Allergol Clin Immunol*. 2006;16: 203–9.
- Ko YI, Park HS, Choi IS. Ranitidine-induced anaphylaxis: detection of serum specific IgE antibody. *Allergy* 2006; 61: 260–70.
- Task Force for Diagnosis and Treatment of Acute and Chronic Heart Failure 2008 of European Society of Cardiology, Dickstein K, Cohen-Solal A, Filippatos G, McMurray JJ, Ponikowski P, Poole-Wilson PA, et al. ESC Guidelines for the diagnosis and treatment of acute and chronic heart failure 2008: the Task Force for the Diagnosis and Treatment of Acute and Chronic Heart Failure 2008 of the European Society of Cardiology. Developed in collaboration with the Heart Failure Association of the ESC (HFA) and endorsed by the European Society of Intensive Care Medicine (ESICM). *Eur Heart J* 2008; 29: 2388–442.