

case report

## Osteosarcoma of the maxilla

Biges Sayin, Nilgün Yildirim, Murat Vural, Doğan Dede

Department of Radiology, Ankara Numune State Hospital, Ankara, Turkey

---

**Background.** Maxillofacial sarcomas are rare tumours and osteosarcoma of the jaws is an exceptionally rare entity. Unlike osteosarcoma of the long bones, maxillofacial osteosarcomas are reported to occur in the third or fourth decades.

**Case report.** We report an 18-year-old female patient with the histopathologic diagnosis of osteoblastic osteosarcoma of the maxillary bone on the basis of computerized tomographic findings. Following the initial surgery and the adjuvant chemo-radiotherapy, a massive local recurrence developed in the facial region of the patient within two years.

**Conclusions.** The radiographic evaluation of the osteosarcoma of the maxilla is important in the diagnosis and obtaining a complete surgical therapy. CT examination of this region after plain radiography plays a major role at the diagnosis.

*Key words:* maxillary neoplasms – radiography; osteosarcoma

---

### Introduction

Osteosarcoma is the most common primary malignancy of bone although only 6% to 10% of osteosarcomas occur in the craniofacial region.<sup>1</sup> Within the craniofacial region the mandible is usually reported as the most common site of the involvement, followed by the maxilla and skull.<sup>1,2</sup> The average age at the onset of osteosarcoma of the maxillofacial region is about one or two decades later than that of osteosarcomas of other regions and

the highest occurrence is found in the third to fourth decade of life.

The patient we present is much younger than those in the literature.

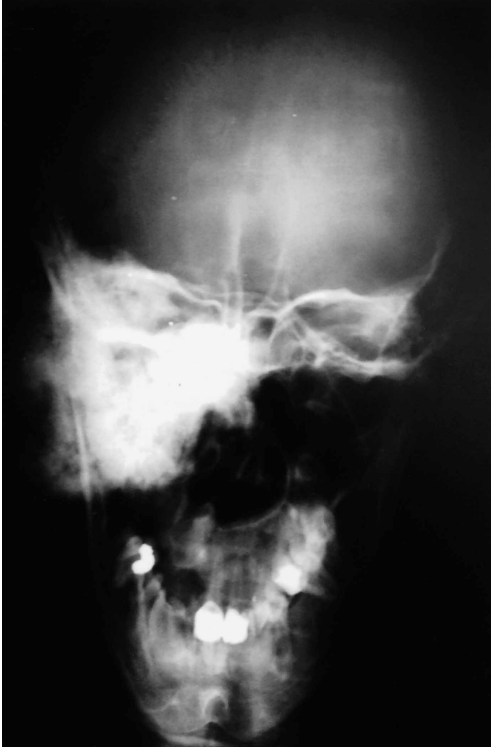### Case report

An 18-year-old female patient was admitted to our hospital in September 2000 with the complaint of a painless swelling of her right cheek which was gradually enlarging for over two months. She also reported excessive tears in her right eye and loss of teeth on the right maxilla. By the physical examination, a 4 × 7 centimetre, hard, non-tender mass involving the right half of the maxillary region was found. No cervical lymphadenopathy was detected following the bilateral palpation

Received 6 October 2004

Accepted 30 October 2004

Correspondence to: Biges Sayin MD, 96.sokak Yazikiri Sitesi B-2 Blok No:12, 06530 Ümitköy /Ankara, Turkey; Phone: +90 312 235 23 85; Fax: +90 312 363 22 89; E-mail: tamsay@hotmail.com



**Figure 1.** On Townes view plain film densely calcified and ossified mass can be appreciated.

of the neck. Her systemic examination did not reveal abnormal clinical findings. Chest X-ray, blood tests and abdominal ultrasonography were normal. A whole-body bone scan showed the increased activity in the right maxillary location. On the computerized tomography it was seen that the tumour exhibited the invasion into the upper palatinum and infero-lateral wall of the maxillary sinus, and caused a development of a centimetre defect in the base of the orbital cavity, however, there was no descent of the orbital structures. Although the tumour was in close relation to the medial wall of the maxillary sinus, this region appeared to be tumour-free. A punch biopsy of the lesion revealed the diagnosis of osteoblastic osteosarcoma of the maxilla.

After the evaluation, a surgical exploration was performed and the patient underwent a wide excision of the tumour with hemimaxil-

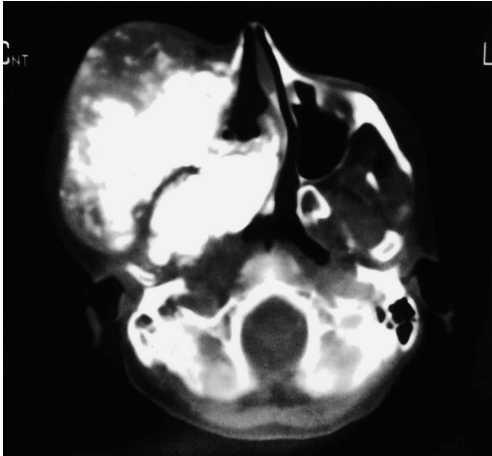
lectomy of the right side. The histopathologic examination of the specimen confirmed the diagnosis of the punch biopsy of osteoblastic osteosarcoma and the margins of the surgical resection were negative for the tumour. The nearest margin of the resection to tumour was three millimetres away. The patient received a total of 57 Gy adjuvant irradiation therapy with  $^{60}\text{Co}$  teletherapy equipment. The combination chemotherapy (adriamycin 500 mg/m<sup>2</sup> and metotrexate 50 mg/m<sup>2</sup>) was given in six cycles in an adjuvant setting.

In December 2001, she was free of symptoms and both the control X-ray and CT did not detect any recurrent tumour in the related region.

In June 2002, she was again admitted to our hospital with the complaint of a painful swelling in the operated area, difficulty in oral feeding and chemosis. Upon a clinical examination, a massive recurrent lesion at the operated site was noted. The plain radiography demonstrated a densely ossified mass in the right hemifacial region (Figure 1).

On CT scan examination, a 6 × 9 × 15 cm, mixed density, complex mass was seen at the primary site and also invaded the upper, lateral and inferior wall of the right orbita, the zygomatic bone, the infratemporal fossa, the masticatory muscles, and extended to ethmoid air spaces and narrowed the airway passage. The inferior border of the right ramus was disrupted and the right bulbus oculi was pushed anteriorly by the tumour. The right masseter muscle was seemed to be thickened and heterogeneous with respect to the contra lateral side. The right parapharyngeal fat tissue and lateral recessus was obliterated and the right sided narrowing of the nasopharyngeal airway passage was noted. The mass had dense amorphous ossifications and showed the heterogeneous uptake of contrast material (Figure 2). We also constructed three-dimensional (3D) images so as to define the lesion more precisely (Figure 3).

The patient was evaluated for the possible

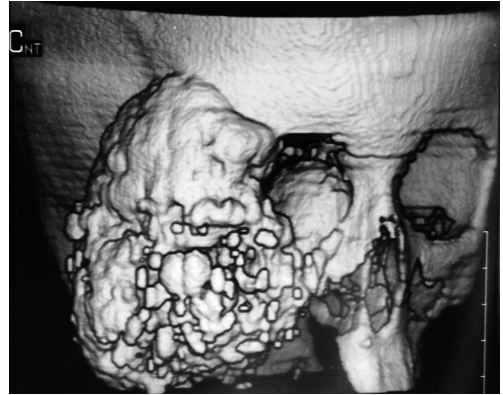

**Figure 2.** Axial computed tomography image. Mass composed of calcification and ossification.

metastasis and was negative. Because of locally advanced and in-operable disease, a course of palliative external radiation therapy was administered with  $^{60}\text{Co}$  teletherapy equipment. Following a total dose of 20 Gy, there was an improvement in her symptoms but no regression of the lesion was noted.

### Discussion

Osteosarcoma is the most common primary malignancy of bone, although only 6% to 10% of osteosarcomas occur in the craniofacial region.<sup>1</sup> Osteosarcoma of the craniofacial region is a relatively rare disease.<sup>2,3</sup> The mandible is usually reported as the most common site of involvement although there are some reports that mandibular and maxillary osteosarcomas have been seen in the equal frequency followed by the skull.<sup>1,4,5</sup> When compared with other locations, craniofacial osteosarcomas are less aggressive, occur in a more elderly population and prefer local invasion rather than distant metastases. The average age at the onset of osteosarcoma of the maxillofacial region is found in the third to fourth decade of life.<sup>6</sup> While a slight male predominance is reported by some au-



**Figure 3.** Three dimensional reconstructed image of the mass.

thors,<sup>1,4,7</sup> some others propose it is more frequent in women.<sup>5</sup> There are also reports with equal gender distribution.<sup>3</sup> The histologic types are chondroblastic (41%), osteoblastic (33%) and fibroblastic (26%).<sup>2</sup>

The major risk factors for the development of osteosarcoma of the jaws are similar to those for osteosarcoma of the long bones, i.e., previous irradiation of facial region, Paget's disease and fibrous dysplasia. Other bone abnormalities, such as multiple osteochondromatosis, chronic osteomyelitis, myositis ossificans and trauma have also been proposed as risk factors.<sup>3,7</sup> Our patient had no known aetiology of osteosarcoma.

On plain radiographs, findings in osteosarcoma of the jaws are non-specific and these tumours have variable presentations, with the spectrum ranging from osteolytic through mixed osteolytic-osteoblastic to predominantly osteoblastic.<sup>8</sup> It may have a completely radio lucent appearance, but it is often presented as a poorly-defined mixed radio lucent-radiopaque lesion.<sup>7,8</sup> Plain radiography must be followed by the CT examination as the bone erosion, soft tissue infiltration and neoplastic tissue ossification can be showed superiorly.

CT has come to play a large role as osseous changes in the jaws, distinguishing the lesion from surrounding or superimposed structures, anatomy of the tumour and the degree

of ossification can be precisely evaluated. The CT appearance of our case has been reported as being a mass of mixed radiopacity with a predominant soft tissue component, central calcification/ossification, and the aggressive destruction of the structures involved. Three radiographic presentations of osteosarcoma of the jaw are identified.<sup>5</sup> The first is radiolucent, characterized by a total absence of bone formation within the tumour. In this type, the conventional radiology reveals a non-specific destruction of bone indistinguishable from the bone erosion caused by carcinoma. The second has a mottled appearance with small areas of amorphous ossification separated by non-ossified tumour tissue. In this type, the mottled ossification can be better or exclusively visualized by CT. The third, with lamellar ossification, is typically characterized by bony plates irradiating from a focus like a sunburst. In most cases, this type is visible with the conventional radiography; however CT separates fine lamellae from adjacent structures and makes the diagnosis easier in the less typical cases.

The presented patient's radiographic appearance was in accordance with the third type identified above. This trabecular sunburst pattern, resulting from bony spicules extending from cortex into the soft tissue, has been reported in 25% to 32% of jaw osteosarcomas.<sup>1</sup> The sunburst pattern of periosteal bone formation in relation to a large soft tissue destructive mass, is considered characteristic of the osteosarcoma but it is non-specific.<sup>9,10</sup>

It is clear that the complete resection of the primary lesion is ideal for the treatment of osteosarcoma. A total maxillectomy is recommended at the time of the initial diagnosis of osteosarcoma as was in the patient presented.<sup>6</sup> The surgical margin appears important in terms of prognosis. Patients with clear surgical margins of greater than 5 mm demonstrate a better survival, fewer local recurrences, and less metastatic disease than those with margins of less than 5 mm.<sup>7</sup> Although

such a wide rim of normal tissue is impractical in the jaws, clear margins play a role in eradication of disease and limitation of intramedullary extension.<sup>6,7</sup> In our patient, clear surgical margins were obtained at the initial therapy, but one margin was close to the tumour as previously described. Osteosarcomas arising from the maxilla cannot always be resected with sufficiently safe margins as in the presented patient. This is reflected by a relatively high local recurrence rate in some series.<sup>6</sup> These tumours have usually a tendency to spread with local invasion.<sup>2,3,5</sup> Our patient had no detectable metastases in spite of the advanced, recurrent mass.

Adjuvant treatments are considered effective for preventing recurrence only when the primary lesion has been removed completely, although chemotherapy can be used for the control of occult distant metastases, as in osteosarcomas of extremities.<sup>6,11</sup> From available data, it appears that the introduction of chemotherapy for the treatment of craniofacial osteosarcomas did not lead to the improvement in the survival statistics as it did with osteosarcomas of extremities.<sup>2</sup> Some studies have shown radiation to be ineffective in the treatment of craniofacial osteosarcomas.<sup>2,11</sup> Delgado *et al* expressed that when surgical margins are not free of disease, the use of radiation does not improve the outcome.<sup>9</sup> On the other hand, the ability of these tumours to spread through bone marrow dictates the establishment of surgical margins extending beyond the clinical and radiological presentation of the disease.<sup>2</sup> Therefore, early diagnosis and radical surgery with wide surgical margins should be the most important part of primary treatment, as the residual tumour may show the aggressive local invasion of the tissues of the head and neck, as in our patient.<sup>1,4,12</sup> High histological grade and incomplete resection or local recurrence support a poor prognosis.<sup>2</sup>

In our view the presented case is interest-

ing in terms of relatively early age onset of the tumour. Secondly, although the patient was free of symptoms and local recurrence with X-ray and CT 1.5 years after the therapy, she presented with a local, massive recurrence in 6 months time. That's why we believe that the careful follow-up of these patients for local recurrence is mandatory.

In conclusion, osteosarcoma of the maxilla has an aggressive biological behaviour even in the case of applying adjuvant therapies. Therefore, early diagnosis and radical surgery with wide surgical margins are the keys to a good outcome. CT has an important role in the early diagnosis and the evaluation of its extent for the surgical planning.

### References

1. Barnes EL, Peel RL, Verbin RS, Goodman MA, Apple BN. Diseases of the bones and joints. In: Barnes EL, editor. *Surgical pathology of the head and neck*. New York: Marcel Dekker Inc; 1985. p. 985-99.
2. Mardinger O, Givol N, Talmi YP, Taicher S, Saba K, Hashomer T. Osteosarcoma of the jaw. *Oral Surg Oral Med Oral Pathol Oral Radiol Endod* 2001; **91**: 445-51.
3. Oda D, Bavisotto LM, Schmidt RA, McNutt M, Bruckner JD, Conrad III EU, et al. Head and neck osteosarcoma at the University of Washington. *Head Neck* 1997; **19**: 513-23.
4. Mark RJ, Sercarz JA, Tran L, Dodd LG, Selch M, Calcaterra TC: Osteogenic sarcoma of the head and neck: the UCLA experience. *Arch Otolaryngol Head Neck Surg* 1991; **117**: 761-6.
5. Bianchi SD, Boccardi A. Radiological aspects of osteosarcoma of the jaws. *Dentomaxillofac Radiol* 1999; **28**: 42-7.
6. Okinaka Y, Takahashi M. Osteosarcoma of the maxilla: Report of a case and review of the literature concerning metastasis. *J Oral Maxillofac Surg* 1997; **55**: 1177-81.
7. August M, Magennis P, Dewitt D. Osteogenic sarcoma of the jaws: factors influencing prognosis. *Int J Oral Maxillofac Surg* 1997; **26**: 198-204.
8. Cavalcanti MGP, Ruprecht A, Yang J. Radiological findings in an unusual osteosarcoma in the maxilla. *Dentomaxillofac Radiol* 2000; **29**: 180-4.
9. Delgado R, Maafs E, Alfeiran A, Mohar A, Barrera JL, Zinser Z, et al. Osteosarcoma of the jaw. *Head Neck* 1994; **16**: 246-52.
10. Anderson D, Snyderman CH. Pathologic quiz case 2. High grade osteosarcoma of the maxilla. *Arch Otolaryngol Head Neck Surg* 1997; **123**: 1355-6.
11. Van Es RJJ, Keus RB, Van der Waal I, Koole R, Vermey A. Osteosarcoma of the jaw bones. *Int J Oral Maxillofac Surg* 1997; **26**: 191-7.