

## Heidelberg Retina Tomograph for the Detection of Glaucoma

Heidelbergov mrežnični tomograf pri odkrivanju glavkoma

Barbara Cvenkel

Eye Hospital, University  
Medical Centre Ljubljana

### Korespondenca/ Correspondence:

Barbara Cvenkel  
Eye Hospital, University  
Medical Centre,  
Grablovičeva 46,  
1000 Ljubljana  
email: barbara.cvenkel@  
kclj.si

### Ključne besede:

Heidelbergov mrežnični  
tomograf, glavkom,  
odkrivanje

### Key words:

Heidelberg retina  
tomograph, glaucoma,  
diagnosis

### Citirajte kot/Cite as:

Zdrav Vestn 2012;  
81: 1-157-69

Prispelo: 2. feb. 2012,  
Sprejeto: 13. mar. 2012

### Abstract

Heidelberg Retina Tomograph (HRT) is a confocal scanning laser ophthalmoscope which acquires and analyzes 3-dimensional images of the optic nerve head. The latest instrument HRT<sub>3</sub> includes software with larger ethnic-specific normative database. This review summarizes relevant published literature on HRT in diagnosing glaucoma, detecting glaucoma progression, the diagnostic accuracy of HRT among other imaging devices and its role in clinical practice.

### Izvleček

Heidelbergov mrežnični tomograf (HRT) je konfokalni laserski oftalmoskop, ki posname in analizira 3-dimenzionalne slike papile vidnega živca. Zadnja verzija aparata, HRT<sub>3</sub>, uporablja programsko opremo, ki vključuje večjo, etnično specifično normativno podatkovno bazo. Ta pregledni prispevek obravnava pomembne članke o vlogi HRT pri odkrivanju glavkoma in njegovega napredovanja, o diagnostični vrednosti HRT med drugimi slikovnimi metodami in njegovem mestu v klinični praksi.

---

### Introduction

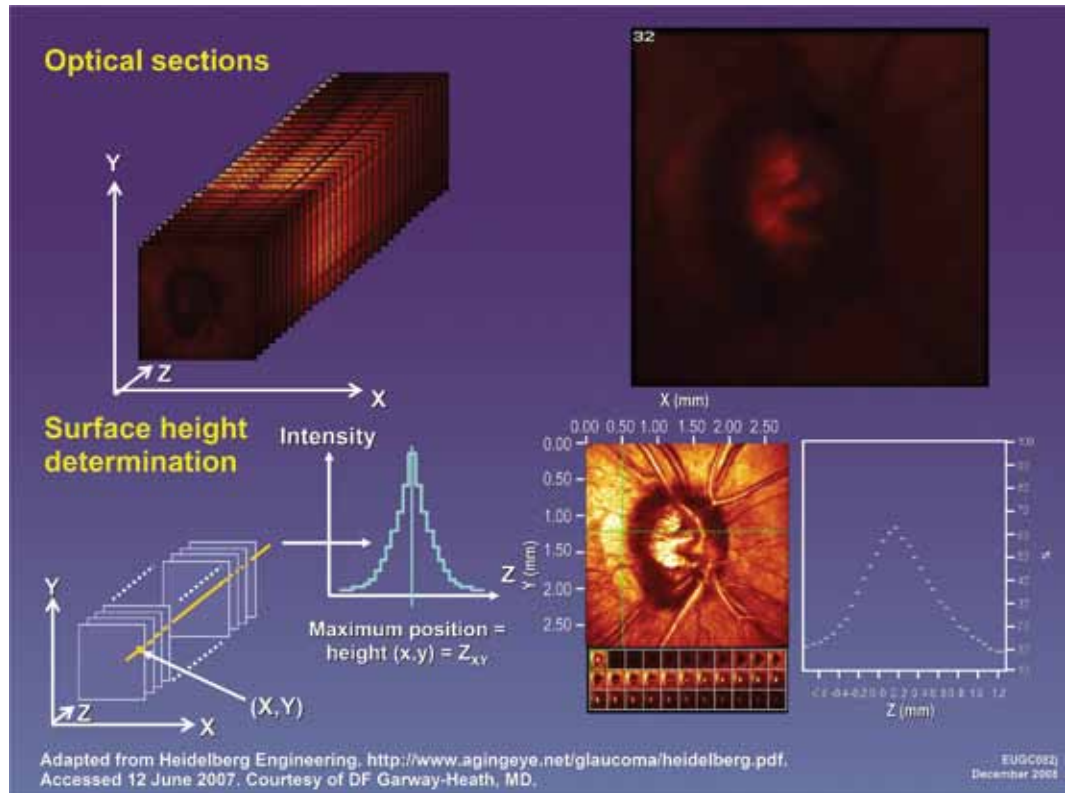
Glaucoma is a slowly progressive optic neuropathy that causes death of retinal ganglion cells and their axons, accompanied by the changes of the connective tissue of the optic nerve head (ONH). It has been documented that at least 25 % to 35 % of retinal ganglion cells are lost before the appearance of first visual field loss in standard automated perimetry.<sup>1</sup> Because the glaucomatous damage is irreversible, it is important to detect disease early enough to prevent or delay the progression and to preserve vision-related quality of life.

The mainstay of glaucoma diagnosis is assessment of both, structural changes at the optic disc and retinal nerve fibre layer

(RNFL) and visual field (VF). There is no strong correlation between structural and functional changes in glaucoma. This is probably due to different information collecting, the variability in testing and also due to the lack of gold standard for the definition of early glaucoma.

The diagnostic performance of structural tests is usually compared to the assessments of ONH stereophotographs by experts as a reference standard. In clinical practice, the clinician judges the optic disc and RNFL at slit lamp using indirect ophthalmoscopy. The clinical examination requires skill and experience especially in borderline cases (suspicious optic discs) and is prone to variability among ophthalmologists. In contrast, imaging technologies provide accurate

**Figure 1:** Optical sections are acquired along the optic nerve (z-axis) at intervals of 1/16 mm. Only the light originating from the corresponding focal plane reaches the light detector, whereas the light outside the focal plane is masked.



te, quantitative and repeatable information. Confocal scanning laser tomography with its commercial device Heidelberg Retina Tomograph (HRT; Heidelberg Engineering GmbH, Heidelberg, Germany), which acquires topographical images of ONH, has been available for more than a decade. It has been shown that HRT and scanning laser polarimeter GDx had better diagnostic ability than subjective evaluation of ONH and RNFL by general ophthalmologists.<sup>2,3</sup> However, the data provided by the imaging instruments should be interpreted in the context of all clinically relevant information for the management of patients with glaucoma.

This review summarizes the published literature on confocal scanning laser ophthalmoscopy, its role in detecting glaucoma and its progression, as well as its role in the clinical practice.

### Confocal scanning laser ophthalmoscopy

The Heidelberg Retina Tomograph is a confocal scanning laser ophthalmoscope designed to acquire and analyse three-dimensional images of the ONH and the para-

papillary RNFL. In a confocal laser scanning system, a 670-nm diode laser emits a beam that is focused in the x-axis and y-axis (horizontal and vertical dimensions) of the ONH, perpendicular to the z-axis (axis along the optic nerve) and the amount of reflected light from each scanned point (at each pixel) is measured. In front of the light detector, a confocal pinhole allows only light originating from the corresponding focal plane to reach the light detector, while the light outside the focal plane is masked. The reflected image from this plane is captured as a two-dimensional scan. Successive equidistant optical sections at intervals of 1/16 mm are acquired, up to 64, depending on the cup depth of the optic disc. These sections are then combined to form a three-dimensional image of the ONH region. Surfaces of the optic cup, neuroretinal rim, and peripapillary retina are determined by a change in reflectance intensity along the z-axis at each point (Figure 1). This creates a topographic map for the calculation of cup-to-disc (C/D) ratio, rim area, and other optic disc parameters. The first commercial device HRT I can scan at 10, 15 and 20 degrees of width. Later introduced devices, the HRT II and HRT3, have

the image field of 15 degrees, with a density of 384 x 384 pixels, and an improved lateral resolution of 11 mm. Additionally, both devices have automated features, such as serial scans, averaging of scans, and fine focus and scan depth. The examination can be performed through undilated pupils, 3 scans consisting of 384x384 pixels are acquired and automatically aligned to create one mean topographic image used for analysis. The image quality is assessed by standard deviation of the mean topographic image by the software. The HRT I and II require drawing of the optic disc margin by the operator. The quantification of the optic disc parameters is related to the reference plane, which is defined as the plane 50 µm below the contour line at the inferior papillomacular bundle. Space above this reference plane is defined as »neuretinal rim« and space below the plane is defined as »cup«. The recent HRT<sub>3</sub> has an operator-independent assessment of the optic disc margin.

### Algorithms used for analysis of images to diagnose glaucoma and its progression

In the HRT II and HRT<sub>3</sub>, the acquired images are automatically analyzed by special algorithms which compare the subject's topography images to the normative database. HRT II uses different algorithms, such as various linear discriminant function analyses and the Moorfields Regression Analysis.

*Discriminant function analysis* is a method of predicting group membership from an optimally weighed combination of variables. For HRT, this analysis determines a combination of ONH parameters that best predicts the presence or absence of glaucoma. There are several discriminant analyses formulae used for the classification of HRT printouts that were developed by different researchers. The differences among the various formulae probably reflect the differences in the subject groups caused by factors such as subject selection, ONH size, glaucoma definitions and variations in disc margin contour line drawing. Most often used are discriminant function analyses developed

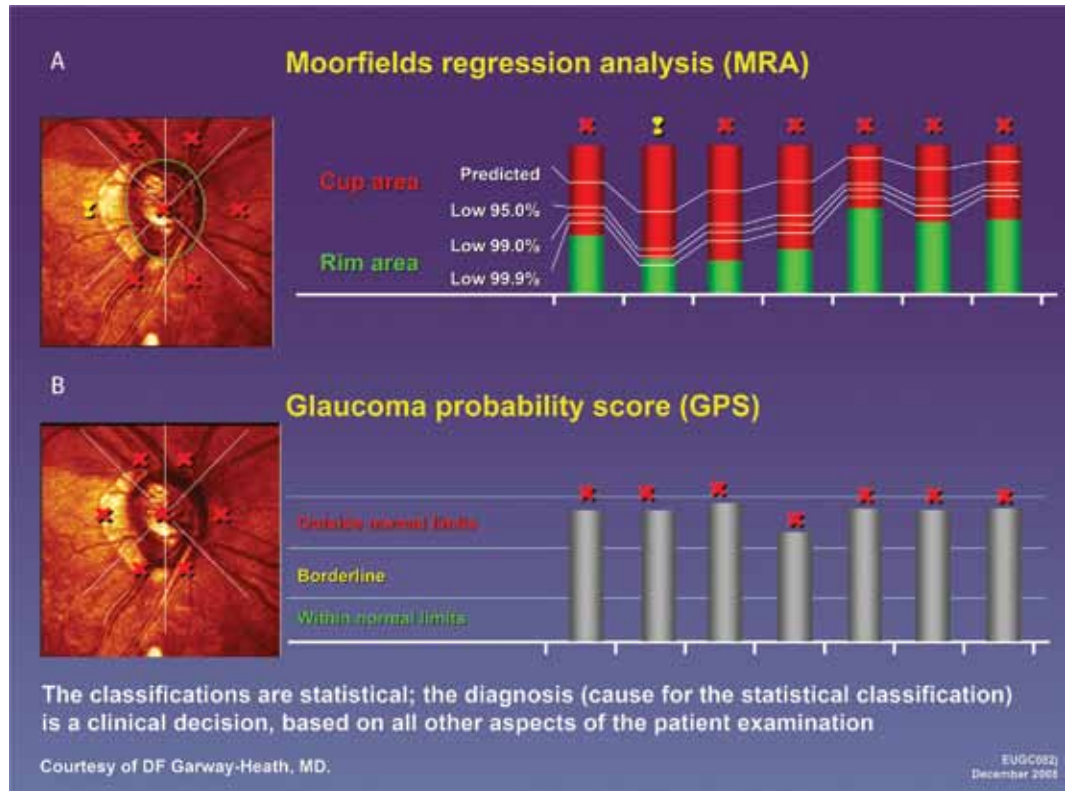
by Mikelberg, Bathija and by Burk and co-workers.<sup>4</sup>

*Moorfields Regression Analysis (MRA)* is based on the relationship between global and sectorial optic disc area and neuretinal rim area, adjusted for age. By comparing the actual measurements for the global and 6 optic disc segments to the database obtained from 112 normal eyes (later an extended normative database available), the MRA classifies optic disc into 3 grades: "normal" if all the measurements fall within 95 % confidence intervals (CI); "borderline" if at least one falls between the lower 95 % and 99.9 % CI; and "outside normal limits" if at least one measurement is less than the lower 99.9 % CI (Figure 2).

The newer HRT<sub>3</sub> software includes a larger normative database with ethnic-specific stratification and calculates the *glaucoma probability score (GPS)*, which uses two parameters of parapillary RNFL shape (horizontal and vertical RNFL curvature) and three parameters of ONH shape (cup size, cup depth and rim steepness) for input into a vector machine learning classifier that estimates the probability of the presence of glaucoma.<sup>5-7</sup> The result is a score between 0 % and 100 % and interpreted as: 0 %–27 % normal, 28 %–64 % borderline, and more than 65 % outside normal limits. No contour line or reference plane is used in the GPS calculation, and therefore analysis is operator independent. This is based on mathematical modelling of the optic nerve shape, which typically exhibits a cup with varying width and depth, as well as curvature of the rim region.<sup>5</sup> The normally convex RNFL curvature, caused by the ganglion cell axons converging towards the optic nerve, flattens as axons are lost as a result of glaucoma.

HRT has been available for longer than other quantitative imaging devices and has undergone only minimal hardware changes, along with important software improvements. The first device on the market, HRT I showed good agreement for stereometric parameters with HRT II, which suggests that HRT I and HRT II examinations can be used interchangeably to detect changes in stereometric parameters over time.<sup>8</sup> Therefore, more data has accumulated and is available

**Figure 2:** Moorfields Regression Analysis (A) and Glaucoma Probability Score (B) algorithms for analysis of HRT images.



for longitudinal analysis, which is extremely important to detect progression in a slowly progressive disease such as glaucoma. HRT II and HRT3 software has two types of progression algorithm. Trend analysis, which tracks a normalized stereometric parameter in time, and topographical change analysis (event-based analysis), which monitors changes in surface topography over time. Topographical change analysis has been validated in several longitudinal studies and showed changes more frequently than stereophotographs of optic disc and was at least as reliable as expert observers judging progression from monoscopic photographs.<sup>9,10</sup>

### Reproducibility of HRT analysis

One of the most important requisites of imaging device is the reproducibility of the findings, as this can affect its diagnostic power. Measurements of optic disc stereometric parameters with HRT I and HRT II have been demonstrated to be repeatable with intra-class correlation coefficient of approximately 0.85.<sup>11</sup> The sources of measurements' variability for HRT I and HRT II include image quality,<sup>12</sup> patient/scanner

misalignment,<sup>13</sup> and inter-observer differences in optic disc contour line drawing.<sup>14</sup> The HRT3 GPS classification which does not rely on optic disc margin drawing by the observer, showed excellent intra-session reproducibility of GPS parameters for normal subjects with mean intra-class correlation coefficients ranging from 0.897 to 0.976 and slightly decreased in the glaucoma patients with the mean intra-class coefficients ranging from 0.705 to 0.922.<sup>15</sup>

### Diagnostic accuracy of HRT in glaucoma detection

The ability of HRT to differentiate glaucoma from normal eyes is usually reported as the sensitivity and the specificity of the test. The diagnostic accuracy of the HRT is compared to different reference standards, such as the assessment of optic disc at slit lamp or viewing ONH stereophotographs, visual field defects or both. Sensitivity is the proportion of true positives that are correctly identified by the test and specificity is the proportion of true negatives correctly identified by the test. Often the sensitivities are reported at a fixed specificity of 95 % (i.e.

the accuracy of test accepting the 5 % false positives). The tradeoff between sensitivity and specificity is important in judging the performance of a test and is described by a receiver operating characteristic (ROC) curve across different cutoff points. ROC curves are used to compare accuracies among different diagnostic tests and are plots of the true positive rate against the false positive rate for the different possible cut-points of a diagnostic test. The area under the ROC curve is a measure of test accuracy, with areas closer to 1 indicating the more accurate test.

### Factors affecting the diagnostic accuracy of HRT

Important factors that affect the diagnostic accuracy of every diagnostic test are: differences in population, study design, criteria used to define the disease, setting (clinic- or population-based), severity of glaucoma and differences in the reference standard. Most of the diagnostic studies in glaucoma are case-control design studies, including glaucoma patients (cases) with typical glaucomatous ONH changes and/or repeatable glaucomatous visual field defects and normal subjects with normal intraocular pressure, healthy optic disc and no visual field defects. In these studies the discriminating ability of HRT is better than in patients suspected of having glaucoma, because of the absence of a perfect reference standard for early disease. The diagnosis of true glaucoma in a glaucoma suspect can only be confirmed in time, when progressive damage is detected to confirm the diagnosis. Therefore the diagnostic accuracy of HRT is lower in population-based and screening studies, which include more mixed cases.

### Case/control studies: Diagnostic performance of HRT algorithms

In the HRT II and III software most often used diagnostic classifications are the Moorfields Regression Analysis (MRA) and Glaucoma Probability Score (GPS). The sensitivity of MRA ranged from 56 % to 84 %, and specificity from 94 % to 96 %, when borderline cases were treated as test negative.<sup>16</sup>

When borderline cases were considered as test positive, sensitivity increased to 85 % and specificity decreased to 81 %.<sup>17</sup>

The sensitivity and specificity of the MRA and GPS to discriminate normal from glaucomatous discs is similar, with areas under ROC curves from 0.77 to 0.90 for MRA, and from 0.78 to 0.92 for GPS.<sup>6,18</sup> Harizman and colleagues<sup>7</sup> compared the detection of glaucoma using operator-dependent MRA classification and operator-independent GPS in the HRT3. They showed that global GPS had a sensitivity and specificity of 77.1 % and 90.3 %, compared with 71.4 % and 91.9 % for the overall MRA classification. The GPS was better at discriminating patients with early glaucoma (defined as visual field with mean deviation  $\leq 5$  dB), with a sensitivity of 72.3 % compared with 59.6 % for MRA. Similar results were reported by Coops and colleagues.<sup>6</sup> When borderline cases were considered as within normal limits, the GPS had a sensitivity of 59 % and a specificity of 91 % and the MRA had a sensitivity of 56 % and specificity of 76 %. The diagnostic performance of global GPS and MRA were similar with areas under ROC curve of 0.78 and 0.77, respectively. Combining GPS and MRA did not improve diagnostic performance. In a Turkish primary open-angle glaucoma population, MRA had a sensitivity of 67.7 % and a specificity of 95.1 %, whereas the GPS had a sensitivity of 70.9 % and a specificity of 88 %.<sup>19</sup> The parameters with the highest area under ROC curve were global GPS (0.86), cup/disc area (0.85), rim/disc are (0.85) and vertical cup/disc (0.85). Reddy and colleagues<sup>18</sup> reported age-adjusted sensitivity and specificity of 76.8 % and 92 % for GPS, and 80.5 % and 93 % for MRA, respectively. Differences in both classification systems are caused by differences in study population including ethnicity,<sup>20</sup> severity of glaucoma, and different disc size; the MRA is also influenced by the operator-dependent contour line placement. More severe disease is associated with increased sensitivity.<sup>18,21,22</sup> The sensitivity for early glaucoma was from 52.1 %<sup>23</sup> to 69.8 % for MRA<sup>18</sup> and from 66.6 %<sup>18</sup> to 78.3 %<sup>23</sup> for GPS. The GPS classification usually has a higher sensitivity and a lower specificity than MRA in patients with mild

glaucomatous visual field loss.<sup>24</sup> Discriminating ability of the HRT (manufacturer's recommendation) is good for the optic disc size between 1.2 and 2.8 mm<sup>2</sup>. Both GPS and MRA were influenced by disc size. Larger optic discs were associated with increased sensitivity of the MRA and GPS<sup>6,25</sup> and of various HRT parameters,<sup>26</sup> whereas smaller discs were associated with decreased sensitivity.<sup>21</sup> Coops and colleagues<sup>6</sup> reported a stronger dependency of GPS than MRA on disc size with a 21 % increase in the odds of an outside normal limits GPS classification for each 0.1 mm<sup>2</sup> increase in disc area compared to 15 % for MRA.

Coops and colleagues<sup>6</sup> found close agreement between the overall classifications of GPS; complete agreement in 71 % glaucoma cases and in 68 % healthy control cases, whereas others found only moderate to fair agreement.<sup>19,23</sup>

In conclusion, the two classification systems have shown similar discriminating ability between healthy and glaucomatous optic discs. The GPS has the advantage that placement of the contour line is not required. However, in some eyes the GPS algorithm cannot find a surface fit compatible with the optic disc topography and therefore the GPS classification is not generated. In such cases MRA classification is still available.

### Population-based studies: Diagnostic performance of HRT algorithms

There are a few population-based studies investigating accuracy of HRT as a screening test for open-angle glaucoma. In a cross-sectional study enrolling 303 high-risk subjects, screening for glaucoma with HRT II was compared to clinical diagnosis of glaucoma.<sup>27</sup> Depending on the gold standard and test-positive definitions for glaucoma, sensitivity ranged from 25 % to 100 % and specificity from 87 % to 97 %. The best combination of sensitivity/specificity (84.6 %/95.6 %) was present when borderline outcomes were considered test negative, and the gold standard definition included glaucoma suspects with normal. In this study, the prevalence of glaucoma, defined as optic nerve damage

was 7.2 % (21 of 291 clinically examined participants). HRT II as glaucoma case finding test had an average sensitivity of 69 % and specificity of 94 % compared to ophthalmic examination as a reference standard.<sup>28</sup> In the Tajimi study<sup>29</sup> including 2297 subjects, sensitivity and specificity of 3 classifications (Mikelberg discriminant function, MRA and GPS) using HRT II was evaluated and compared to the reference standard (i.e. clinical evaluation of optic disc, RNFL and visual field). The sensitivities were low for all 3 classifications: 59.1 % for Mikelberg discriminant function, 39.4 % for MRA, and 65.2 % for GPS; specificities were 86.7 % for Mikelberg discriminant function, 96.1 % for MRA, and 83.0 % for GPS. Positive predictive values (i.e. the proportion of those with a positive test result who actually have disease) for these classifications were low, ranging from 10 % to 23 %, whereas negative predictive values (the proportion of those with a negative test result who do not have disease) were good, ranging from 98 % to 99 %. Low sensitivities are likely due to greater heterogeneity, as this study included a larger proportion of glaucoma suspect eyes. Eyes with early glaucoma and smaller cup tended to be misdiagnosed (classified as false negative) by all 3 classifications. Larger discs, but also older age and presbiopia were associated with lower specificity, especially with the GPS. A similar performance of HRT II was reported in the Singapore Malay Eye Study.<sup>30</sup> When borderline cases were considered within normal limits, the sensitivity was 43.6 % and specificity 97.2 %. When comparing different HRT II algorithms (3 linear discriminant functions and MRA), the areas under ROC curves were similar ranging from 0.704 to 0.789. Larger optic disc size was associated with increased sensitivity and false-positive rate. The HRT II as a screening tool was evaluated in participants from the 10-year follow-up Blue Mountains Eye Study.<sup>31</sup> The MRA classification was compared to a reference standard, which were optic disc stereophotographs and Humphrey 24-2 visual fields. HRT scans could be acquired from 95.9 % participant (1644 out of 1952 subjects). The prevalence of glaucoma diagnosed independently by optic disc stere-

ophotographs and visual fields was 5.43 % (105 participants). If borderline outcomes were classified as test-negative, the MRA had a sensitivity of 64.1 % and a specificity of 85.7 %. Including borderline as test-positive, the sensitivity increased to 87.0 %, whereas specificity dropped to 70.6 %. Diagnostic performance improved for visual field with MD < -4.0 dB. Predictors of MRA outside normal limits were open-angle glaucoma, older age, greater topography standard deviation, and larger disc size. Larger discs increased the sensitivity at the expense of specificity. Older participants with the highest prevalence of glaucoma had an increased topography standard deviation (measure of the scan quality), which was associated with the poorest sensitivity and specificity.

### Correlation of structural changes measured by HRT with visual field

Morphological changes at the ONH and RNFL are associated with loss of function. The gold standard for measuring functional deficit is standard automated perimetry. Many global or sectoral topographic parameters obtained by HRT have been found to be correlated with global or sectoral visual field indices (Table 1). Most often found parameters correlating with visual field were:

cup area, cup/disc ratio, rim area, rim volume, cup shape measure, RNFL thickness and RNFL cross-sectional area. Rim area and cup shape were the best predictors of visual field indices (mean deviation (MD) and pattern standard deviation (PSD)). The associations were stronger when more advanced glaucoma patients with MD worse than -10 dB were included than in patients with early glaucoma. Based on the 95th percentile of the standardized rim/disc area ratio, Bartz-Schmidt and colleagues<sup>32</sup> calculated the relative rim area loss and correlated this with visual field index MD. The scatter plot showed an exponential relationship, with 40 % of the neuroretinal rim lost before the appearance of the first visual field defect, while in the later stages of glaucoma a large change in MD was accompanied by a small amount of rim area loss. However, there are great interindividual variations among glaucoma patients, which are more pronounced for early glaucoma.<sup>22,32,33</sup> Some studies found better associations for sectoral than for global parameters. Lan and colleagues<sup>33</sup> observed a good relationship between inferior and combined superior/inferior rim area and corresponding sectoral visual field MD. In two studies,<sup>34,35</sup> optic disc in patients with focal damage was divided into 36 sectors and mapped to visual field organized in 21 zones. These studies found that some

**Table 1:** Correlation coefficients between global HRT topographic parameters and visual field indices from different studies.

HRT parameter	Study population	Number of subjects	MD correlation coefficient	PSD or CPSD correlation coefficient	Study
Cup shape	Early to moderate glaucoma	46	-0.65	0.55	Brigatti L, et al. <sup>52</sup>
Cup shape	Normal, OHT and glaucoma	Normal 59 OHT 64 Glaucoma 171	-0.43	0.38	Iester M, et al.
Rim area	Glaucoma	62	0.32	0.25	Lan YW, et al. <sup>33</sup>
Rim area	Glaucoma	44	0.62	-0.34	Lee KH <sup>53</sup>
Rim area	Normal and glaucoma	Normal 37 Glaucoma 475	-0.45	-	Medved N, et al. <sup>22</sup>
Classification algorithms*	Normal and glaucoma	Normal 48 Glaucoma 104	From 0.23 to 0,32	-	Ford BA, et al. <sup>17</sup>

MD – mean deviation

PSD – pattern standard deviation; CPSD – corrected pattern standard deviation

\* Linear discriminant functions of Mikelberg, Burk and Bathija

field zones topographically map to certain rim sectors with a higher probability than to others, but there was also a considerable interindividual variability.

## HRT compared to other imaging devices for ONH and RNFL assessment

Besides confocal scanning laser tomography with HRT, the most common used technologies are optical coherence tomography (OCT) and scanning laser polarimetry (Gdx Nerve Fibre Analyzer, Carl Zeiss Meditec). Among the studies that directly compared these instruments, there was no significant difference in their ability to differentiate glaucoma from controls. The comparison of HRT II, GDx VCC, and Stratus OCT showed similar areas under ROC curves for the best parameter from each device. The areas under ROC curves were 0.91 for nerve fibre indicator from the GDx VCC, 0.92 for retinal nerve fiber layer inferior thickness from Stratus OCT, and 0.86 for linear discriminant function from HRT II.<sup>36</sup> Agreement on categorization between instruments was assessed using weighted  $\kappa$  (kappa) approach, with  $\kappa$  less than 0 indicating poor agreement, 0 to 0.20 slight, 0.21 to 0.40 fair, 0.41 to 0.60 moderate, 0.61 to 0.80 substantial and 0.81 to 1 almost perfect agreement. The agreement in categorization among the devices ranged from moderate to substantial (0.50 to 0.72). A report by the American Academy of Ophthalmology<sup>37</sup> based on the review of relevant articles from January 2003 to February 2006 on imaging of ONH and RNFL found that in direct comparison there was no single imaging device that outperforms the others in distinguishing patients with glaucoma from controls. The results between different studies cannot be directly compared, because sensitivities and specificities depend strongly on the parameters and algorithms used, and from the definition of glaucoma, which varies across the published studies. When comparing the performance of HRT I, GDx VCC and time domain OCT in patients with OHT, glaucoma suspect and early glaucoma,

Kanamori and colleagues<sup>38</sup> reported that all instruments were good in identifying glaucoma suspects and early glaucoma eyes. In this study, OCT (average RNFL thickness; area under ROC curve 0.869) and GDx VCC (nerve fibre indicator; area under ROC curve 0.875) showed similar and better discriminating ability for the best parameter in glaucoma suspect eyes compared to HRT (vertical cup/disc ratio; area under ROC 0.72).

Recently, Leung CK and colleagues<sup>39</sup> evaluated diagnostic performance and agreement between HRT<sub>3</sub> (MRA classification) and Spectral-domain OCT (Spectralis OCT, Heidelberg Engineering) in 79 patients with moderate and advanced glaucoma and 75 normal subjects. The agreement between categorical classification (»within normal limits«, »borderline«, and »outside normal limits«) at the temporal, superotemporal, superonasal, nasal, inferonasal and inferotemporal sectors of the optic disc were evaluated with  $\kappa$  statistics. When defining glaucoma as »outside normal limits« in the global and/or in  $\geq 1$  measurements, the respective sensitivities of Spectralis OCT and HRT were 91.1 % and 79.8 % at a similar level of specificity (97.4 % and 94.7 %). The area under ROC curve for OCT global RNFL thickness (0.978) was greater than for those of HRT global rim area (0.905) and vertical cup/disc ratio (0.857). Agreement of categorical classification between HRT and Spectralis OCT was fair to moderate ( $\kappa$  ranged from 0.33 to 0.53) with the best agreement in the inferotemporal sector. It was suggested that higher diagnostic sensitivity for glaucoma detection in this study may reflect stronger OCT RNFL thickness association with visual field sensitivity, which was used as a reference standard.<sup>40</sup>

## Role of imaging in clinical setting

### Glaucoma detection

Detection of glaucoma relies on the judgment of both the optic disc and visual field. In some eyes repeatable structural changes are detectable before development of repe-



atable visual field defects by standard automated perimetry.<sup>41,42</sup> Clinical examination of optic disc and RNFL is subjective, prone to variability, and requires an experienced observer. Imaging by HRT helps the clinician to assess optic nerve in a quantitative and objective way at the level of an expert observer. Most often stereophotographs are used as a gold standard in the assessment of optic disc status and also for the detection of structural change. Medeiros and colleagues<sup>43</sup> have shown that HRT linear cup/disc ratio measurements can be used interchangeably with the stereophotographic-based cup/disc ratio measurements.

Imaging devices were shown to perform better than general ophthalmologists in the evaluation of ONH and RNFL. Vessani and colleagues<sup>2</sup> compared the subjective assessment of ONH and RNFL stereophotographs by general ophthalmologists and by a glaucoma expert with the objective imaging by HRT3, Stratus OCT and GDx enhanced corneal compensation in discriminating normal from glaucoma eyes. All imaging techniques had better performance than subjective evaluation of the ONH by general ophthalmologists, but not by a glaucoma expert. Best parameters from HRT3 were global cup/disc area ratio and glaucoma probability score (for both area under ROC curve 0.83). In another study, the European Optic Disc Assessment Trial,<sup>3</sup> 243 general ophthalmologists from 11 European countries classified stereoscopic slides of 40 healthy eyes and 48 glaucomatous eyes with varying severity of the disease and their diagnostic accuracies were compared with the best parameter from GDx VCC and HRT I. Both imaging devices had better diagnostic accuracy than general ophthalmologists in detecting glaucoma, who correctly classified in approximately 80 % of cases (CI from 61.4 % to 94.3 %). In this study, HRT I was used, which requires optic disc contour placement. With the latest HRT3 GPS software for the analysis no optic disc contour line placement is required, and therefore one source of variability is removed and is more time-saving in a busy clinical setting.

## Prediction of glaucoma development

Bowd and colleagues<sup>44</sup> have demonstrated that baseline measurements predict the development of glaucomatous visual field defect in glaucoma-suspect eyes. Also, the largest study of ocular hypertensive eyes, the Confocal Scanning Laser Ophthalmoscopy Ancillary Study to OHTS,<sup>45</sup> reported that several baseline topographic optic disc measurements (larger cup/disc area ratio, mean cup depth, mean height contour, cup volume, reference plane height, and smaller rim area, rim area to disc area, and rim volume) as well as the MRA classification were predictive of the development of a repeatable optic disc or visual field endpoint. Eyes with a baseline MRA result »outside normal limits« had a 2.5 times increased risk of developing glaucoma than eyes with normal MRA at baseline. But among 128 eyes with HRT classification »outside normal limits« at baseline only 13.5 % eyes developed POAG after 8 years of follow-up. Approximately 80 % of participants who developed glaucoma had HRT values within the normal limits at baseline. HRT data, when used alone and combined with clinical measures (medical history, corneal thickness and complete ophthalmological examination) are associated with the development of glaucoma in subjects with ocular hypertension. Strouthidis and colleagues<sup>46</sup> have explored the ability of MRA and GPS classification systems at baseline to predict progression in 198 subjects with ocular hypertension during mean follow-up time of 6 years. They found that neither of the two classification systems could predict visual field progression in isolation. An abnormal MRA classification (defined as outside normal limits combined with borderline) was found to be predictive of HRT or VF progression, whereas an abnormal GPS classification was not. The 2 classifications, when found to be abnormal in the same subjects (which occurred in 30 % of OHT subjects), were more significantly associated with future HRT or VF progression than either one in isolation. This indicates, that in clinical practice, ocular hypertensive patients with both an abnormal MRA and GPS classification at presentation should be fol-

lowed closely as they have an increased risk of future VF or HRT change.

### Detection of glaucoma progression

In a study that compared the detection of ONH progression between HRT using linear discriminant function (event-based analysis) and stereophotographs, the change in many HRT parameters (especially the cup/disc area ratio and vertical cup/disc ratio) had a significant correlation with progression.<sup>47</sup> Monitoring progression at ONH with HRT was found to be complimentary to, but not a replacement for, stereoscopic ONH photography. Similar findings were reported by O'Leary and colleagues.<sup>48</sup> In this study, the 91 eyes of 56 patients were monitored by HRT for at least 70 months and compared to stereophotographs evaluated by expert observers as the reference standard. Topographic change analysis, statistical image mapping, and linear regression of rim area across time were applied to HRT for progression analysis. All 3 statistical methods had only moderate agreement with each other and had poor agreement with expert-assessed change in optic disc stereophotographs. Only fair agreement between HRT II using topographic change analysis and expert clinical assessment of ONH stereophotograph evaluation of ONH was also demonstrated in another study.<sup>9</sup> Topographic change analysis failed to identify progressive structural damage in the presence of advanced optic nerve damage.<sup>49</sup>

### Conclusions

The Heidelberg Retina tomograph (HRT) is a confocal scanning laser ophthalmoscope that has been available for over a decade. HRT evaluates objectively and quantitatively the ONH topography and parapapillary RNFL. There are two principal applications of HRT in the management of patients with glaucoma. The first is to help the clinician in identifying whether or not a particular optic disc is glaucomatous or is within normal limits. The second is to assist in monitoring progression of disease through the assessment of optic nerve head changes over time.

Most often used HRT classification systems incorporated in HRT II and HRT 3 are: the Glaucoma Probability Score (GPS) and the Moorfield Regression Analysis (MRA). Both report the probability of a particular ONH being abnormal. The GPS differentiates between normal and glaucomatous eyes by a 3-dimensional mathematical model of ONH shape.<sup>5</sup> The model uses two RNFL parameters (horizontal and vertical RNFL curvature) and three optic disc parameters (cup size, cup depth and rim steepness). The GPS model assumes that with the development of glaucoma, the RNFL curvature flattens and thins, the cup deepens and enlarges, and that the slope of neuretinal rim steepens. Unlike the MRA, the GPS does not require contour line placement. The MRA classification compares a subject's rim area for global and 6 optic disc sectors with the predicted rim area taking into account optic disc size and age.

Both classification systems have similar performance in differentiating normal from glaucomatous eyes. There is evidence that »an outside normal limits« MRA is more useful than GPS to confirm that a disc is abnormal, whereas a "within normal limits" GPS classification is more useful than MRA in confirming that a disc is normal.<sup>50</sup> Disease severity has been shown to influence classification, with GPS having a higher sensitivity and lower specificity than MRA in patients with mild glaucomatous visual field damage, whereas MRA better differentiates patients with severe glaucomatous visual field loss.<sup>51</sup>

Although various ONH parameters have shown significant correlation with visual field indices, there are great variations among individuals, especially in patients with mild glaucomatous visual field loss. Combined abnormal GPS and MRA classifications in the same patient are associated with an increased risk for future optic disc change or visual field damage in ocular hypertensive subjects.

To detect change longitudinally, HRT software has two types of progression algorithm: trend-based analysis, which tracks a normalized stereometric parameter over time, and event-based topographical chan-

ge analysis (TCA), which monitors surface topography over time. The TCA compared to clinical assessment of ONH stereophotographs had moderate agreement, and detected progression more frequently. This higher rate of identifying a change probably reflects that changes detected by TCA are not identified by observing the stereophotographs. But at present, HRT progression alone should not indicate a treatment change. The HRT results must be evaluated in conjunction with other clinical features of deterioration before altering therapy.

In conclusion, HRT enables an accurate, quantitative and repeatable recording of ONH structure with less fluctuation than standard automated perimetry. It is also feasible in patients who are unable to undergo perimetry. The diagnostic classification systems assist the clinician to discriminate between normal and glaucomatous eyes and may also be used to estimate a rate of change, which guides patient management. Only good quality image scans should be used for analysis with topography standard deviation as recommended by the manufacturer. The classifications should not be used in isolation to diagnose and change treatment, but rather as an additional information taking into account all clinical features, i. e. the history and clinical examination.

## References

1. Kerrigan-Baumrind LA, Quigley HA, Pease ME, Kerrigan DF, Mitchell RS. Number of ganglion cells in glaucoma eyes compared with threshold visual field tests in the same persons. *Invest Ophthalmol Vis Sci* 2000; 41(3): 741–8.
2. Vessani RM, Moritz R, Batis L, Zagui RB, Bernardoni S, Susanna R. Comparison of quantitative imaging devices and subjective optic nerve head assessment by general ophthalmologists to differentiate normal from glaucomatous eyes. *J Glaucoma* 2009; 18(3): 253–61.
3. Reus NJ, Lemij HG, Garway-Heath DF, et al. Clinical assessment of stereoscopic optic disc photographs for glaucoma: the European Optic Disc Assessment Trial. *Ophthalmology* 2010; 117(4): 717–23.
4. Iester M, Mardin CY, Budde WM, Junemann AG, Hayler JK, Jonas JB. Discriminant analysis formulas of optic nerve head parameters measured by confocal scanning laser tomography. *J Glaucoma* 2002; 11(2): 97–104.
5. Swindale NV, Stjepanovic G, Chin A, Mikelberg FS. Automated analysis of normal and glaucomatous optic nerve head topography images. *Invest Ophthalmol Vis Sci* 2000; 41(7): 1730–42.
6. Coops A, Henson DB, Kwartz AJ, Artes PH. Automated analysis of heidelberg retina tomograph optic disc images by glaucoma probability score. *Invest Ophthalmol Vis Sci* 2006; 47(12): 5348–55.
7. Harizman N, Zelefsky JR, Ilitchev E, Tello C, Ritch R, Liebmann JM. Detection of glaucoma using operator-dependent versus operator-independent classification in the Heidelberg retinal tomograph-III. *Br J Ophthalmol* 2006; 90(11): 1390–2.
8. Balasubramanian M, Bowd C, Weinreb RN, Zangwill LM. Agreement between the Heidelberg Retina Tomograph (HRT) stereometric parameters estimated using HRT-I and HRT-II. *Optom Vis Sci* 2011; 88(1): 140–9.
9. Kourkoutas D, Buys YM, Flanagan JG, Hatch WV, Balian C, Trope GE. Comparison of glaucoma progression evaluated with Heidelberg retina tomograph II versus optic nerve head stereophotographs. *Can J Ophthalmol* 2007; 42(1): 82–8.
10. Chauhan BC, Hutchison DM, Artes PH, et al. Optic disc progression in glaucoma: comparison of confocal scanning laser tomography to optic disc photographs in a prospective study. *Invest Ophthalmol Vis Sci* 2009; 50(4): 1682–91.
11. Dreher AW, Tso PC, Weinreb RN. Reproducibility of topographic measurements of the normal and glaucomatous optic nerve head with the laser tomographic scanner. *Am J Ophthalmol* 1991; 111(2): 221–9.
12. Miglior S, Albe E, Guareschi M, Rossetti L, Orzalesi N. Intraobserver and interobserver reproducibility in the evaluation of optic disc stereometric parameters by Heidelberg Retina Tomograph. *Ophthalmology* 2002; 109(6): 1072–7.
13. Orgul S, Cioffi GA, Bacon DR, Van Buskirk EM. Sources of variability of topometric data with a scanning laser ophthalmoscope. *Arch Ophthalmol* 1996; 114(2): 161–4.
14. Tan JC, Garway-Heath DF, Fitzke FW, Hitchings RA. Reasons for rim area variability in scanning laser tomography. *Invest Ophthalmol Vis Sci* 2003; 44(3): 1126–31.
15. Taibbi G, Fogagnolo P, Orzalesi N, Rossetti L. Reproducibility of the Heidelberg Retina Tomograph III Glaucoma Probability Score. *J Glaucoma* 2009; 18(3): 247–52.
16. Rao HL, Babu GJ, Sekhar GC. Comparison of the diagnostic capability of the Heidelberg Retina Tomographs 2 and 3 for glaucoma in the Indian population. *Ophthalmology* 2010; 117(2): 275–81.
17. Ford BA, Artes PH, McCormick TA, Nicoleta MT, LeBlanc RP, Chauhan BC. Comparison of data analysis tools for detection of glaucoma with the Heidelberg Retina Tomograph. *Ophthalmology* 2003; 110(6): 1145–50.
18. Reddy S, Xing D, Arthur SN, et al. HRT III glaucoma probability score and Moorfields regression across the glaucoma spectrum. *J Glaucoma* 2009; 18(5): 368–72.
19. Bozkurt B, Irkek M, Arslan U. Diagnostic accuracy of Heidelberg Retina Tomograph III classifications in a Turkish primary open-angle glaucoma population. *Acta Ophthalmol* 2010; 88(1): 125–30.
20. Girkin CA, Sample PA, Liebmann JM, et al. African Descent and Glaucoma Evaluation Study (ADAGES): II. Ancestry differences in optic disc, retinal nerve fiber layer, and macular structure in healthy subjects. *Arch Ophthalmol*; 128(5): 541–50.
21. Medeiros FA, Zangwill LM, Bowd C, Sample PA, Weinreb RN. Influence of disease severity and optic disc size on the diagnostic performance of imaging instruments in glaucoma. *Invest Ophthalmol Vis Sci* 2006; 47(3): 1008–15.
22. Medved N, Cvenkel B. Diagnostic accuracy of the Moorfields Regression Analysis using the Heidelberg Retina Tomograph in glaucoma patients with visual field defects. *Eur J Ophthalmol* 2007; 17(2): 216–22.
23. Jindal S, Dada T, Sreenivas V, Gupta V, Sihota R, Panda A. Comparison of the diagnostic ability of Moorfield's regression analysis and glaucoma probability score using Heidelberg retinal tomograph III in eyes with primary open angle glaucoma. *Indian J Ophthalmol*; 58(6): 487–92.
24. Ferreras A, Pablo LE, Pajarin AB, Larrosa JM, Polo V, Pueyo V. Diagnostic ability of the Heidelberg Retina Tomograph 3 for glaucoma. *Am J Ophthalmol* 2008; 145(2): 354–9.
25. Bathija R, Zangwill L, Berry CC, Sample PA, Weinreb RN. Detection of early glaucomatous structural damage with confocal scanning laser tomography. *J Glaucoma* 1998; 7(2): 121–7.
26. Iester M, Mikelberg FS, Drance SM. The effect of optic disc size on diagnostic precision with the Heidelberg retina tomograph. *Ophthalmology* 1997; 104(3): 545–8.
27. Harasymowycz PJ, Papamatheakis DG, Fansi AK, Gresset J, Lesk MR. Validity of screening for glaucomatous optic nerve damage using confocal scanning laser ophthalmoscopy (Heidelberg Retina Tomograph II) in high-risk populations: a pilot study. *Ophthalmology* 2005; 112(12): 2164–71.
28. Jeong A, Murdoch I, Cousens S, Healey P, Theodossades J. Sensitivity and specificity of two glaucoma case-finding strategies for optometrists. *Ophthalmic Physiol Opt* 2003; 23(4): 341–6.

29. Saito H, Tsutsumi T, Araie M, Tomidokoro A, Iwase A. Sensitivity and specificity of the Heidelberg Retina Tomograph II Version 3.0 in a population-based study: the Tajimi Study. *Ophthalmology* 2009; 116(10): 1854–61.
30. Zheng Y, Wong TY, Lamoureux E, et al. Diagnostic ability of Heidelberg Retina Tomography in detecting glaucoma in a population setting: the Singapore Malay Eye Study. *Ophthalmology* 2010; 117(2): 290–7.
31. Healey PR, Lee AJ, Aung T, Wong TY, Mitchell P. Diagnostic accuracy of the Heidelberg Retina Tomograph for glaucoma a population-based assessment. *Ophthalmology* 2010; 117(9): 1667–73.
32. Bartz-Schmidt KU, Thumann G, Jonescu-Cuypers CP, Krieglstein GK. Quantitative morphologic and functional evaluation of the optic nerve head in chronic open-angle glaucoma. *Surv Ophthalmol* 1999; 44 Suppl 1:S41–53.
33. Lan YW, Henson DB, Kwartz AJ. The correlation between optic nerve head topographic measurements, peripapillary nerve fibre layer thickness, and visual field indices in glaucoma. *Br J Ophthalmol* 2003; 87(9): 1135–41.
34. Yamagishi N, Anton A, Sample PA, Zangwill L, Lopez A, Weinreb RN. Mapping structural damage of the optic disk to visual field defect in glaucoma. *Am J Ophthalmol* 1997; 123(5): 667–76.
35. Anton A, Yamagishi N, Zangwill L, Sample PA, Weinreb RN. Mapping structural to functional damage in glaucoma with standard automated perimetry and confocal scanning laser ophthalmoscopy. *Am J Ophthalmol* 1998; 125(4): 436–46.
36. Medeiros FA, Zangwill LM, Bowd C, Weinreb RN. Comparison of the GDx VCC scanning laser polarimeter, HRT II confocal scanning laser ophthalmoscope, and stratus OCT optical coherence tomograph for the detection of glaucoma. *Arch Ophthalmol* 2004; 122(6): 827–37.
37. Lin SC, Singh K, Jampel HD, et al. Optic nerve head and retinal nerve fiber layer analysis: a report by the American Academy of Ophthalmology. *Ophthalmology* 2007; 114(10): 1937–49.
38. Kanamori A, Nagai-Kusuhara A, Escano MF, Maeda H, Nakamura M, Negi A. Comparison of confocal scanning laser ophthalmoscopy, scanning laser polarimetry and optical coherence tomography to discriminate ocular hypertension and glaucoma at an early stage. *Graefes Arch Clin Exp Ophthalmol* 2006; 244(1): 58–68.
39. Leung CK, Ye C, Weinreb RN, et al. Retinal nerve fiber layer imaging with spectral-domain optical coherence tomography a study on diagnostic agreement with Heidelberg Retinal Tomograph. *Ophthalmology* 2010; 117(2): 267–74.
40. Bowd C, Zangwill LM, Medeiros FA, et al. Structure-function relationships using confocal scanning laser ophthalmoscopy, optical coherence tomography, and scanning laser polarimetry. *Invest Ophthalmol Vis Sci* 2006; 47(7): 2889–95.
41. Kass MA, Heuer DK, Higginbotham EJ, et al. The Ocular Hypertension Treatment Study: a randomized trial determines that topical ocular hypotensive medication delays or prevents the onset of primary open-angle glaucoma. *Arch Ophthalmol* 2002; 120(6): 701–13; discussion 829–30.
42. Miglior S, Zeyen T, Pfeiffer N, Cunha-Vaz J, Torri V, Adamsons I. Results of the European Glaucoma Prevention Study. *Ophthalmology* 2005; 112(3): 366–75.
43. Medeiros FA, Zangwill LM, Bowd C, Vasile C, Sample PA, Weinreb RN. Agreement between stereophotographic and confocal scanning laser ophthalmoscopy measurements of cup/disc ratio: effect on a predictive model for glaucoma development. *J Glaucoma* 2007; 16(2): 209–14.
44. Bowd C, Zangwill LM, Medeiros FA, et al. Confocal scanning laser ophthalmoscopy classifiers and stereophotograph evaluation for prediction of visual field abnormalities in glaucoma-suspect eyes. *Invest Ophthalmol Vis Sci* 2004; 45(7): 2255–62.
45. Zangwill LM, Weinreb RN, Beiser JA, et al. Baseline topographic optic disc measurements are associated with the development of primary open-angle glaucoma: the Confocal Scanning Laser Ophthalmoscopy Ancillary Study to the Ocular Hypertension Treatment Study. *Arch Ophthalmol* 2005; 123(9): 1188–97.
46. Strouthidis NG, Gardiner SK, Owen VM, Zuniga C, Garway-Heath DF. Predicting progression to glaucoma in ocular hypertensive patients. *J Glaucoma* 2010; 19(5): 304–9.
47. Saarela V, Falck A, Airaksinen PJ, Tuulonen A. The sensitivity and specificity of Heidelberg Retina Tomograph parameters to glaucomatous progression in disc photographs. *Br J Ophthalmol* 2010; 94(1): 68–73.
48. O'Leary N, Crabb DP, Mansberger SL, et al. Glaucomatous progression in series of stereoscopic photographs and Heidelberg retina tomograph images. *Arch Ophthalmol* 2010; 128(5): 560–8.
49. Hudson CJ, Kim LS, Hancock SA, Cunliffe IA, Wild JM. Some dissociating factors in the analysis of structural and functional progressive damage in open-angle glaucoma. *Br J Ophthalmol* 2007; 91(5): 624–8.
50. Zangwill LM, Jain S, Racette L, et al. The effect of disc size and severity of disease on the diagnostic accuracy of the Heidelberg Retina Tomograph Glaucoma Probability Score. *Invest Ophthalmol Vis Sci* 2007; 48(6): 2653–60.
51. Ferreras A, Pajarin AB, Polo V, Larrosa JM, Pablo LE, Honrubia FM. Diagnostic ability of Heidelberg Retina Tomograph 3 classifications: glaucoma probability score versus Moorfields regression analysis. *Ophthalmology* 2007; 114(11): 1981–7.
52. Brigatti L, Caprioli J. Correlation of visual field with scanning confocal laser optic disc measurements in glaucoma. *Arch Ophthalmol* 1995; 113(9): 1191–4.
53. Lee KH, Park KH, Kim DM, Youn DH. Relationship between optic nerve head parameters of Heidelberg Retina Tomograph and visual field defects in primary open-angle glaucoma. *Korean J Ophthalmol* 1996; 10(1): 24–8.