

Research article/Raziskovalni prispevek

COMPARISON OF OPTIC NERVE HEAD TOPOGRAPHY IN NORMAL EYES USING CONFOCAL LASER SCANNING TOMOGRAPH AND RETINAL THICKNESS ANALYZER

PRIMERJAVA KONFOKALNEGA SKENIRAJOČEGA LASERSKEGA TOMOGRAFA IN ANALIZATORJA DEBELINE MREŽNICE PRI ANALIZI TOPOGRAFIJE PAPILE VIDNEGA ŽIVCA PRI NORMALNIH OČEH

Andreja Rekič, Barbara Cvenkel

Očesna klinika, Klinični center, Zaloška 29a, 1525 Ljubljana

Arrived 2005-02-02, accepted 2005-04-21; ZDRAV VESTN 2005; 74: 617-22

Key words: Heidelberg retina tomograph; limits of agreement; optic nerve head; repeatability; retinal thickness analyzer

Abstract – Background. To compare optic nerve head topography measurements by Heidelberg retina tomograph I (HRT) and retinal thickness analyser (RTA) and thereby to determine clinical agreement between the devices. To investigate reproducibility of measurements for HRT and RTA. To obtain our own HRT and RTA database for comparison of healthy and glaucomatous eyes.

Methods. The study included 100 normal eyes of 50 white adults of both sexes (mean age of 55.5 [SD 9.5] years). Ophthalmologic examination, fundus photography, HRT and RTA examinations were performed. To determine reproducibility 10 volunteers repeated the examination after a week. For HRT and RTA measurements mean (SD), median, 5th and 95th percentile, range and coefficient of variation were calculated. Differences in topographic parameters between HRT and RTA were tested for significance. Clinical agreement was assessed with »limits of agreement« and reproducibility expressed by repeatability coefficient and intraclass correlation coefficient (ICC).

Results. Significant differences ($p < 0.05$) in topographic parameters obtained by HRT and RTA were observed for all parameters except for rim area ($p = 0.051$) and height variation contour ($p = 0.054$). Limits of agreement between HRT and RTA were too wide and clinically important. Repeatability coefficient was good (< 0.10) for all HRT parameters except for RNFL cross-sectional area (0.28). Repeatability coefficient was > 0.10 for RTA parameters cup area (0.15), rim area (0.19), maximum cup depth (0.13), height varia-

Ključne besede: analizator debeline mrežnice; Heidelbergov tomograf mrežnice; meje ujemanja; papila vidnega živca; ponovljivost

Izveček – Izhodišča. Strukturne spremembe papile vidnega živca in stanjšanje plasti retinalnih živčnih vlaken (PRŽV) se pri glavkomi nevropatiji pogosto pojavijo pred izpadi v vidnem polju. Morfologija papile vidnega živca je zato pomembna pri zgodnjem odkrivanju in spremljanju glavkoma, kar je pripeljalo do razvoja preiskovalnih metod, kot sta konfokalna skenirajoča laserska oftalmoskopija in digitalna laserska špranjska svetilka, ki omogočata objektivno in kvantitativno analizo tridimenzionalnih lastnosti topografije papile vidnega živca in PRŽV. Namen naše raziskave je bil preveriti ujemanje med metodama in njuno zamenljivost v klinični praksi s primerjavo med meritvami topografij papil s konfokalnim skenirajočim laserskim oftalmoskopom, Heidelbergovim tomografom mrežnice I (HRT) in z digitalno lasersko špranjsko svetilko ter analizatorjem debeline mrežnice (RTA). Preverili smo tudi zanesljivost HRT in RTA pri ponovnem pregledu z določitvijo ponovljivosti meritev za obe metodi. Za vrednotenje strukturnih sprememb papile vidnega živca so potrebni zanesljivi in primerljivi podatki za topografske parametre papile pri zdravih očeh. Zato smo želeli pridobiti lastno normativno podatkovno bazo za HRT in RTA za zdrave oči, kar bi omogočilo zgodnje odkrivanje glavkoma pri slovenski populaciji.

Metode. V raziskavo smo vključili 100 oces 50 zdravih prostovoljcev (32 žensk in 18 moških), starih od 40 do 75 let (povprečna starost 55,5 ± 9,5 leta), ki so obiskali očesno ambulanto zaradi predpisa očal. Vključitvena merila so bila: starost > 40 let, očesni pritisk < 21 mmHg, normalno vidno polje, dioptrija, manjša od ± 6 dioptrij, prozorni optični mediji in očesno ozadje brez bolezenskih sprememb. Preiskovancem

tion contour (0.11) and RNFL cross-sectional area (0.14). ICC was good (> 90%) for all parameters, except for mean RNFL thickness (89%) for HRT and height variation contour (84%) for RTA.

Conclusions. *The two devices cannot be used interchangeably. At present, clinical usefulness of HRT is superior to RTA due to better reproducibility of measurements, better software support, shorter duration of the examination and good comparability of our HRT database with the database included in the latest HRT software version. At the moment RTA is using the same database as HRT. Therefore, our RTA database provides a new basis for comparison of optic disc characteristics between healthy and glaucomatous eyes.*

smo razširili zenici z 1-odstotnim tropikamidom. Po oftalmološkem pregledu je sledila keratometrija, fotografiranje očesnega ozadja z nemidriatično fundusno kamero, preiskava s HRT in nato še z RTA. Za določitev ponovljivosti meritev smo pri 10 naključno izbranih preiskovancih obe preiskavi po enem tednu ponovili na levem očesu. Z Wilcoxonovim testom predznačenih rangov nismo ugotovili statistično pomembnih razlik med vrednostmi topografskih parametrov papile za desno in levo oko, zato smo pri nadaljnji statistični obdelavi meritve obeh oči združili. Izračunali smo srednjo vrednost (SV), standardni odklon (SD), najmanjšo in največjo vrednost ter koeficient variacije meritev s HRT in RTA. S testom Shapiro-Wilk smo ugotovili značilno odstopanje meritev od normalne porazdelitve za večino topografskih parametrov papile za HRT in RTA, zato smo izračunali mediano ter za oceno povprečja populacije določili 5. in 95. percentil. Statistično značilnost razlik med meritvami parametrov papile s HRT in RTA smo preverili z Wilcoxonovim testom predznačenih rangov. Klinično ujemanje med metodama smo ocenili z določitvijo spodnje in zgornje meje ujemanja, ki smo ju izračunali kot SV razlik $\pm 1,96 \cdot SD$ razlik med meritvami s HRT in z RTA, za posamezen parameter papile. Med mejama ujemanja se nahaja 95% razlik med meritvami istih parametrov papile z obehma napravama. Če so razlike znotraj mej ujemanja klinično pomembne, metodi nista zamenljivi v klinični praksi. Ponovljivost meritev za HRT in RTA smo ocenili s koeficientom ponovljivosti in s koeficientom korelacije znotraj razreda (ICC). Pri določitvi koeficienta ponovljivosti smo upoštevali razlike med prvo in drugo meritvijo pri posameznem preiskovancu. Koeficient ponovljivosti je enak $2 \cdot SD$ razlik med meritvama, pri čemer pričakujemo, da je 95% razlik manjših od dveh standardnih odklonov. Koeficient ICC temelji na primerjavi variabilnosti med preiskovanci in variabilnosti znotraj njih. ICC je variabilnost med preiskovanci, izražena kot odstotek celotne (znotraj preiskovanca + med preiskovanci) variabilnosti. Omenjeni variabilnosti smo ocenili z enosmerno analizo variance.

Rezultati. Med vsemi topografskimi parametri papile, izmerjenimi s HRT in RTA smo ugotovili statistično značilne ($p < 0,05$) razlike, razen za površino nevoretinskega obroča ($p = 0,051$) in za razlike v začrtani meji papile ($p = 0,054$). Meje ujemanja med HRT in RTA so bile preširoke in zato klinično pomembne. Koeficient ponovljivosti za HRT je bil dober ($< 0,10$) za vse parametre, razen za površino prečnega prereza PRŽV (0,28). Koeficient ponovljivosti za RTA je bil večji od 0,10 za površino ekskavacije (0,15), površino NRO (0,15), največjo globino ekskavacije (0,13), razlike v višini začrtane meje papile (0,11) in površino prečnega prereza PRŽV (0,14). ICC je bil dober (> 90%) za vse parametre, razen za povprečno debelino PRŽV (89%) pri HRT in za razlike v začrtani meji papile (84%) pri RTA.

Zaključki. *Razlike med meritvami topografskih parametrov papile s HRT in z RTA so statistično pomembne in meje ujemanja preširoke, zato metodi nista zamenljivi v klinični praksi. Ponovljivost meritev za HRT je boljša kot za RTA. Pridobljena lastna normativna podatkovna baza za HRT je primerljiva z obstoječimi normativi za HRT, za katere so dokazali visoko specifičnost (96%) in občutljivost (84%) za ločevanje med zdravimi osebami in tistimi z začetno obliko glaukoma. Naša nova podatkovna baza za RTA ni primerljiva z obstoječimi normativi z RTA. Vzrok je lahko dejstvo, da RTA uporablja iste normative kot HRT. Ker smo dokazali, da se meritve parametrov papile s HRT in RTA razlikujejo, je nova, lastna normativna podatkovna baza za RTA osnova za ločevanje glaukomske spremenjene papile od normalne papile pri naši populaciji. Zaključujemo z ugotovitvijo, da je HRT v primerjavi z RTA bolj uporabna in zanesljiva preiskovalna metoda*

za analizo topografije papile v klinični praksi zaradi primerljive normativne podatkovne baze za slovensko populacijo z obstoječo bazo, dobre ponovljivosti meritev, bolj izpopolnjene programske opreme in krajšega trajanja preiskave.

Introduction

Structural changes of the optic nerve head (ONH) and retinal nerve fibre layer (RNFL) loss often precede detectable visual field loss in glaucomatous optic neuropathy (1). Since, clinical examination of the ONH is subjective, qualitative, and often unreliable technique with high interobserver variability, accurate and objective methods of detecting early disc abnormalities, and their progression, are essential part of the early diagnosis and monitoring of glaucoma. Therefore, new ocular imaging technologies have emerged which provide more accurate, reproducible, objective, and quantitative morphometric analysis of the ONH topography and RNFL thickness (2–4). Today, several such imaging technologies are available including confocal laser scanning tomography, scanning laser polarimetry, optical coherence tomography, and retinal thickness analysis.

HRT (Heidelberg Engineering GmbH, Heidelberg, Germany), the most frequently used ONH imaging device, is an automated confocal laser scanning tomograph that uses a diode laser to acquire, record and analyse the three-dimensional topography of the optic nerve in an accurate, and reproducible manner (5–7). On the other hand, RTA (Talia Technology Ltd, Neve-Ilan, Israel), a digitised slit lamp that uses green helium-neon laser as a light source, was originally introduced to evaluate retinal thickness throughout the posterior pole. Recently, software that creates and analyses topographic map of the optic disc has been added to the RTA (8). The new RTA function has not been extensively studied yet and since it is a new method, we are interested in its reproducibility, and consistency with established techniques.

The aim of this study is to compare the measurements by HRT and RTA across the topographic parameters, and determine the clinical agreement between the devices. Secondly, to investigate the potential to detect structural changes of ONH and RNFL over time, the reproducibility (repeatability) of HRT and RTA was tested. Lastly, to obtain our own HRT and RTA database for normal eyes in population older than 40 years that would allow us to reliably distinguish morphological changes in ONH of patients with early glaucoma from those of normal subjects in our population.

Methods

In this study fifty healthy white adults of both sexes were recruited from the outpatients requiring presbyopic correction. Inclusion criteria were: age > 40 years, intraocular pressure < 21 mmHg, refractive error less than ± 6 dioptres (D), normal visual field, clear optic media, no optic disc abnormalities, and no concurrent ocular disease. Subjects' pupils were dilated with 1% tropicamide. After complete ophthalmologic examination of both eyes, keratometry, fundus photography with nonmydriatic fundus camera (Topcon TRC – NW6S), and ONH imaging with HRT, followed by RTA were performed. To determine the reproducibility of measurements by HRT and RTA, 10 subjects selected randomly within the study group underwent HRT and RTA examination of only left eye again after a week. All investigations were made by the same examiner. The study followed the tenets of the Declaration of Helsinki-Tokio and was approved by the national ethics committee. All subjects gave informed consent to the investigations performed.

ONH imaging with the HRT was performed using mean topographies based on 3 consecutive series of HRT images, scan angle of 10°. ONH image was recreated from a series of optical sections cut at 32 consecutive focal planes, and the information displayed in the topographic image and the reflectivity image. The image quality was assessed by the computer software and the operator. On the topographic image, the optic disc margin was outlined manually while looking at the fundus photograph. For calculations of optic disc topographic parameters with HRT software version 3.0 the standard reference plane was placed 50 μm posterior to the mean height of the contour line defining the disc margin in a temporal segment between 350° and 356°. The following 11 ONH topographic parameters were analysed: disc area, cup area, cup-disc ratio, rim area, rim volume, mean cup depth, maximal cup depth, height variation contour, mean RNFL thickness, and RNFL cross-sectional area.

Optic disc was also scanned with the disc topography mode of the RTA. One scan area covered 3 \times 3 mm, which consisted of 16 optical sagittal cross sections. For each measurement four such scans, at the superior, inferotemporal, inferonasal, and temporal areas of the optic disc were performed by fixating the internal targets by the subject. The image quality was assessed by the operator. Optic disc contour line was drawn manually with the help of the fundus photograph. The same eleven ONH topographic parameters as in HRT were calculated with the RTA disc topography software version 1.11, using the same standard reference plane.

The statistical analysis included 100 eyes of 50 healthy adults (32 female and 18 male) aged 40 to 75 years (mean age 55.5 [SD 9.5] years). The mean (SD) refractive error was + 0.44 (1.36) D, range: - 4.50 D to + 3.00 D and the mean corneal curvature of 7.75 (SD 0.23) mm, range: 7.30 mm to 8.35 mm was measured. Differences between measurements of ONH parameters for left and right eyes were tested for significance with Wilcoxon signed rank test for HRT and RTA separately. There were no significant differences ($p > 0.05$) between measurements of parameters for left and right eyes with HRT and RTA, so for further purposes of statistical analysis we joined the measurements of both eyes together. For all HRT and RTA ONH topographic parameters mean value, standard deviation, range and coefficient of variation were calculated separately. Measurements of individual HRT and RTA parameters were tested for normal distribution with the Shapiro-Wilk test. Because of significant deviation of measurements of several parameters from normality, we determined median, and the 5th and 95th percentiles of the distribution. Differences between measurements of ONH parameters by HRT and RTA were tested for significance with Wilcoxon signed rank test. The clinical agreement between measurements across parameters by HRT and RTA was evaluated with upper and lower limits of agreement (LA = the mean difference \pm 1.96* SD of the mean difference of measurements by HRT and RTA). Between LA we expect to find 95% of differences between measurements of the same parameters with both devices. If the differences within LA are clinically important, the methods are not interchangeable in clinical practice (9). The repeatability of measurements across parameters was calculated as repeatability coefficient and as intraclass correlation coefficient (ICC) (9, 10). The repeatability coefficient relates to the difference between the first and the second measurement and is expressed as 2* SD of the difference, where we expect 95%

of the differences to be less than this value. ICC on the other hand estimates the within-patient and between-patient variances, assuming that the within-patient variance is the same across the volunteers. »One way« analysis of variance was used to calculate both variances. ICC was obtained by expressing the between-patient variance as a percentage of the total (within-patient plus between-patient variance) variance. The ICC represents the power by which patients can be distinguished from each other by their measurement outcome. It is usually accepted that repeatability is high when repeatability coefficient is 0.10 or smaller and the ICC is greater than 90%. Statistical analysis of HRT and RTA data were performed with the SAS statistical software (SAS® System for Windows Release 8.2., SAS Institute Inc., Cary, NC, USA).

Results

Table 1 and Table 2 show the mean values with standard deviation, median, the 5th and 95th percentiles, range values, and coefficient of variation for eleven ONH topographic parameters measured by HRT and RTA respectively.

Repeatability between the first and the second measurement repeated after a week in 10 volunteers (10 left eyes), expressed as repeatability coefficient and as ICC, is outlined in Table 3. Repeatability coefficient was good (0.10 or smaller) for all topographic parameters measured by HRT, except for RNFL cross-sectional area. Repeatability for parameters measured by RTA was not so good for cup area, rim area, maximal cup depth, height variation contour and RNFL cross-sectional area. ICC was high (90% or greater) for most of the parameters measured by HRT and RTA.

The agreement between the two devices presented as limits of agreement (LA) is shown for individual parameters in Table 4. Within these LA we expected to find most of the differences between HRT and RTA measurements. As shown in Table 4, the disc area measured by HRT was underestimated by 0.20 mm² or overestimated by 0.13 mm² in comparison to measurement of disc area by RTA. LA are wider for parameters with higher repeatability coefficient (smaller reproducibility e. g. rim area from - 0.39 mm² to 0.46 mm²). Additionally, Table 4 presents the statistical significance (Wilcoxon signed rank test significant difference at $p < 0.05$) of differences between measurements of topographic parameters by HRT and RTA.

Discussion

In our study we found significant differences between measurements of most of the ONH topographic parameters by HRT and RTA. The parameters measured by HRT were greater than by RTA. Several factors may account for these differences. Firstly, different principles of measurement between the two devices and different light sources in the two instruments. In RTA, similar as in slit lamp biomicroscopy a thin laser slit is projected obliquely onto the retina, while in HRT the light is projected almost perpendicularly onto the retina. Also, RTA uses short-wave green heli-

um-neon laser (wavelength 540 nm) as a light source, that has smaller depth of tissue penetration than long-wave red-diode laser (wavelength 670 nm) used by HRT. Secondly, despite all the effort it was difficult to get a good scan with RTA in some patients, despite wide pupils and clear optical media. The optic disc image had less distinct borders especially in cases where sharp optical slits could not be achieved in all 4 scans. That could be the reason for different positioning of the contour line in RTA despite simultaneous observation of the optic disc photograph. As a result, the reference plane which depends on the contour line was positioned differently and that affected the analyses of parameters depending on the reference plane. For example, by drawing a smaller contour line by RTA the reference plane was shifted downwards accounting for more or equal rim and less cup in comparison to the analysis of the same ONH topography by HRT.

In the only published study that compared optic disc topography measured by HRT II and RTA in 10 eyes of ten healthy subjects, the differences between topographic parameters were significant only for the mean cup depth, maximal cup depth, mean RNFL thickness, and RNFL cross-sectional area which were measured greater by HRT II. The authors attributed the more shallow measurements of these z-axis related parameters by RTA to its short wavelength laser (11).

Inter-test reproducibility expressed as repeatability coefficient was good for HRT and comparable to other authors (11, 12). Better inter-test reproducibility of measurements by HRT than by RTA results from analysing a mean topographic image (derived from 3 single scans) and rejecting scans with unacceptable standard deviation (greater than 30 microns).

Table 1. Mean (SD), median, 5th and 95th percentile, the range and coefficient of variation of optic disc measurements (100 normal eyes, 50 subjects) by HRT.

Razpr. 1. Srednja vrednost (SD), mediana, 5. in 95. percentil, najmanjša in največja meritev in koeficient variacije za topografske parametre papile vidnega živca, izmerjene s HRT pri 100 normalnih očeh (50 preiskovancev).

ONH topographic parameters	Mean (SD)	Median	5 th P	95 th P	Min	Max	CV (%)
Topografski parametri papile vidnega živca	SV (SD)	Mediana	5. P	95. P	Min	Max	KV (%)
Disc area (mm ²) **	1.97 (0.38)	1.93	1.45	2.64	1.19	3.32	19.06
Površina papile							
Cup area (mm ²) **	0.38 (0.25)	0.39	0.01	0.83	0.00	0.99	66.10
Površina ekskavacije							
Cup/Disc ratio **	0.19 (0.11)	0.21	0.00	0.37	0.00	0.39	59.80
Razmerje površina ekskavacije/površina papile							
Rim area (mm ²) **	1.59 (0.32)	1.55	1.16	2.35	1.08	2.50	20.04
Površina NRO							
Cup volume (mm ³) **	0.07 (0.07)	0.06	0.00	0.21	0.00	0.26	94.88
Prostornina ekskavacije							
Rim volume (mm ³) **	0.45 (0.16)	0.43	0.27	0.73	0.15	1.10	34.86
Prostornina NRO							
Mean cup depth (mm)	0.19 (0.08)	0.19	0.07	0.33	0.02	0.37	42.73
Povprečna globina ekskavacije							
Maximum cup depth (mm)	0.49 (0.19)	0.48	0.19	0.77	0.10	1.01	39.18
Največja globina ekskavacije							
Height variation contour (mm)	0.40 (0.09)	0.40	0.25	0.56	0.15	0.60	22.50
Razlike v višini začrtane meje papile							
Mean RNFL thickness (mm)	0.26 (0.06)	0.26	0.16	0.38	0.12	0.39	22.75
Povprečna debelina PRŽV							
RNFL cross-sectional area (mm ²) **	1.28 (0.33)	1.22	0.76	1.88	0.55	2.30	25.96
Površina prečnega prereza PRŽV							

ONH - optic nerve head / papila vidnega živca, NRO - nevroretinski obroč, RNFL - retinal nerve fibre layer, PRŽV - plast retinalnih živčnih vlaken, ** - ONH topographic parameters with significant deviation from normal distribution / topografski parametri papile vidnega živca z značilnim odstopanjem od normalne porazdelitve, SV - srednja vrednost, SD - standard deviation / standardni odklon, P - percentile / percentil, Min - the smallest measurement / najmanjša meritev, Max - the largest measurement / največja meritev, CV - coefficient of variation, KV - koeficient variacije

Table 2. Mean (SD), median, 5th and 95th percentile, the range and coefficient of variation of optic disc measurements (100 normal eyes, 50 subjects) by RTA.

Razpr. 2. Srednja vrednost (SD), mediana, 5. in 95. percentil, najmanjša in največja meritev in koeficient variacije za topografske parametre papile vidnega živca, izmerjene z RTA pri 100 normalnih očeh (50 preiskovancev).

ONH topographic parameters	Mean (SD)	Median	5 th P	95 th P	Min	Max	CV (%)
Topografski parametri papile vidnega živca	SV (SD)	Mediana	5. P	95. P			KV (%)
Disc area (mm ²) Površina papile	1.94 (0.38)	1.90	1.45	2.62	1.14	3.04	19.53
Cup area (mm ²) ** Površina ekskavacije	0.25 (0.24)	0.15	0.00	0.77	0.00	0.93	95.59
Cup/Disc ratio ** Razmerje površina ekskavacije/ površina papile	0.12 (0.10)	0.09	0.00	0.35	0.00	0.39	86.71
Rim area (mm ²) ** Površina NRO	1.68 (0.34)	1.64	1.21	2.30	1.28	2.47	20.05
Cup volume (mm ³) ** Prostornina ekskavacije	0.03 (0.04)	0.01	0.00	0.12	0.00	0.17	140.98
Rim volume (mm ³) ** Prostornina NRO	0.40 (0.15)	0.39	0.18	0.64	0.12	0.83	36.32
Mean cup depth (mm) ** Povprečna globina ekskavacije	0.07 (0.06)	0.07	0.00	0.17	0.00	0.24	77.83
Maximum cup depth (mm) Največja globina ekskavacije	0.43 (0.20)	0.44	0.09	0.78	0.02	0.83	46.38
Height variation contour (mm) Razlike v višini začrtane meje papile	0.45 (0.13)	0.43	0.25	0.70	0.18	0.80	29.41
Mean RNFL thickness (mm) Povprečna debelina PRŽV	0.23 (0.06)	0.23	0.13	0.34	0.11	0.38	26.58
RNFL cross-sectional area (mm ²) Površina prečnega prereza PRŽV	1.11 (0.26)	1.13	0.66	1.52	0.49	1.67	23.52

ONH - optic nerve head / papila vidnega živca, NRO - nevroretinski obroč, RNFL - retinal nerve fibre layer, PRŽV - plast retinalnih živčnih vlaken, * significant / statistično značilno, ** - ONH topographic parameters with significant deviation from normal distribution / topografski parametri papile vidnega živca z značilnim odstopanjem od normalne porazdelitve, SV - srednja vrednost, SD - standard deviation / standardni odklon, P - percentile / percentil, Min - the smallest measurement / najmanjša meritev, Max - the largest measurement / največja meritev, CV - coefficient of variation, KV - koeficient variacije

The reproducibility expressed as ICC was excellent across all topographic parameters measured by both instruments. The agreement between HRT and RTA, expressed as limits of agreement (LA) was especially poor for parameters with low

Figure 1. Comparison of existent HRT and RTA standard values of optic nerve head (ONH) topographic parameters and HRT and RTA standard values acquired in our study. HRT and RTA standard values of ONH topographic parameters from our study are mean values of ONH parameters listed in Table 1.

Par 1 - disc area, par 2 - cup area, par 3 - cup/disc ratio, par 4 - rim area, par 5 - cup volume, par 6 - rim volume, par 7 - mean cup depth, par 8 - maximum cup depth, par 9 - height variation contour, par 10 - mean retinal nerve fiber layer (RNFL) thickness, par 11 - RNFL cross-sectional area.

Sl. 1. Primerjava HRT in RTA standardnih vrednosti topografskih parametrov papile s HRT in RTA standardnimi vrednostmi, pridobljenimi z našo raziskavo. HRT in RTA standardne vrednosti parametrov papile naše raziskave so srednje vrednosti parametrov papile, ki so navedene v razpredelnici 1. Par 1 - površina papile, par 2 - površina ekskavacije, par 3 - razmerje površina ekskavacije/površina papile, par 4 - površina nevroretinskega obroča (NRO), par 5 - prostornina ekskavacije, par 6 - prostornina NRO, par 7 - povprečna globina ekskavacije, par 8 - največja globina ekskavacije, par 9 - razlike v višini začrtane meje papile, par 10 - povprečna debelina plasti retinalnih živčnih vlaken (PRŽV), par 11 - površina prečnega prereza PRŽV.

repeatability (cup area, rim area, maximal cup depth, height variation contour, and RNFL cross-sectional area). But also for other parameters the LA were too wide to be clinically acceptable, therefore the two devices cannot be used interchangeably in clinical practice. In the only published study the authors studied the correlation between the parameters measured by HRT I and RTA in 20 normal subjects and defined good correlation between the two instruments for the maximum cup depth, mean cup depth and cup shape measure (13). However, excellent correlation does not indicate good clinical agreement between the devices.

Our ONH topography database acquired by HRT is comparable to the database used by the latest HRT software (Figure 1), which was reported to have high specificity (96%) and good sensitivity (84%) to distinguish between control subjects and patients with early glaucoma (14). Our RTA database on the other hand, is not comparable to the database used by RTA at the moment. The reason for that could be the fact that RTA is using the same normative database as HRT. And since we have found significant differences between measurements of ONH parameters by HRT and RTA, our new RTA database provides a new basis for comparison of optic disc characteristics between healthy and glaucomatous eyes and needs further evaluation of its diagnostic accuracy.

The ONH imaging by HRT is rapid, has good reproducibility by averaging 3 scans, and is quite comfortable for the patients (easy fixation of the external target, less intensive light as judged by the patients), with no need for pupil dilation. Also, HRT software helps the operator to assess the quality of the image. On the other hand, RTA examination requires wide pupils (more than 5 mm) for a sharp scan of the whole optic disc, it is more strenuous for the patient (more difficult to find and fixate the internal targets), and it is time consuming. The operator's experience with RTA is important in order to obtain sharp optical cross sections of

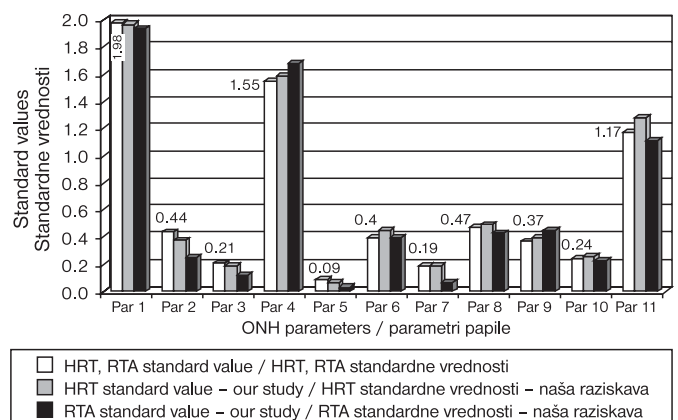


Table 3. *Repeatability of optic disc measurements by HRT and RTA for 10 normal left eyes (10 subjects) expressed as the repeatability coefficient and as ICC.*

Razpr. 3. *Ponovljivost meritev topografskih parametrov papile vidnega živca na 10 normalnih levih očeh (10 preiskovancev) za HRT in RTA, izražena s koeficientom ponovljivosti in z ICC.*

ONH topographic parameters Topografski parametri papile vidnega živca	HRT		RTA	
	Repeatability coefficient Koeficient ponovljivosti	ICC (%)	Repeatability coefficient Koeficient ponovljivosti	ICC (%)
Disc area (mm ²) Površina papile	0.0148	100.0	0.0626	99.8
Cup area (mm ²) Površina ekskavacije	0.0220	99.9	0.1558	96.9
Cup/Disc ratio Razmerje površina ekskavacije/ površina papile	0.0158	99.8	0.0696	96.9
Rim area (mm ²) Površina NRO	0.0268	100.0	0.1876	96.8
Cup volume (mm ³) Prostornina ekskavacije	0.0198	99.4	0.0362	95.9
Rim volume (mm ³) Prostornina NRO	0.0850	96.1	0.0990	95.1
Mean cup depth (mm) Povprečna globina ekskavacije	0.0184	99.6	0.0302	98.3
Maximum cup depth (mm) Največja globina ekskavacije	0.0330	99.7	0.1300	96.4
Height variation contour (mm) Razlike v višini začrtane meje papile	0.0952	90.0	0.1128	84.0
Mean RNFL thickness (mm) Povprečna debelina PRŽV	0.0570	89.0	0.0214	98.3
RNFL cross-sectional area (mm ²) Površina prečnega prereza PRŽV	0.2766	92.2	0.1370	96.4

ICC - intraclass correlation coefficient / koeficient korelacije znotraj razreda, ONH - optic nerve head / papila vidnega živca, NRO - nevroretinski obroč, RNFL - retinal nerve fibre layer, PRŽV - plast retinalnih živčnih vlaken

all 4 scans constituting topography image and also to assess their quality. However, in some eyes it was difficult to get a scan of good quality, despite wide pupils and clear optical media.

In summary, the two devices cannot be used interchangeably in clinical practice on account of the significant differences between measurements of optic disc topographic parameters by HRT and RTA, and clinically important differences within LA. The inter-test reproducibility of measurements was good for both devices, but better for HRT. At present, clinical usefulness of HRT is superior to RTA on account of better potential to detect structural change of ONH over time, better software support, shorter duration of the examination and good comparability of our HRT database with the existing one.

Zahvala

Gospo mag. sc. Marjanci Breznik, mag. farm., se zahvaljujemo za razlago statističnih metod in potrpežljivo obdelavo naših številnih podatkov.

Reference

- Sommer A, Katz J, Quigley HA, Miller NR, Robin AL, Richter RC, et al. Clinically detectable nerve fiber atrophy precedes the onset of glaucomatous visual field loss. *Arch Ophthalmol* 1991; 109: 77-83.
- Greenfield DS. Optic nerve and retinal nerve fiber layer analyzers in glaucoma. *Curr Opin Ophthalmol* 2002; 13: 68-76.

Table 4. *Limits of agreement (LA) between HRT and RTA and significance of differences between measurements of individual parameters by HRT and RTA (p) (Wilcoxon signed rank test).*

Razpr. 4. *Meje ujemanja med HRT in RTA ter prikaz statistične značilnosti razlik med meritvami posameznih parametrov s HRT in z RTA (p) (Wilcoxonov test predznačenih rangov).*

ONH topographic parameters Topografski parametri papile vidnega živca	Lower LA (d - 1.96 s) Spodnja meja ujemanja	Upper LA (d + 1.96 s) Zgornja meja ujemanja	p value p vrednost
Disc area (mm ²) Površina papile	- 0.2012	0.1260	< 0.0001*
Cup area (mm ²) Površina ekskavacije	- 0.3634	0.1794	< 0.0001*
Cup/Disc ratio Razmerje površina ekskavacije/ površina papile	- 0.1954	0.0990	< 0.0001*
Rim area (mm ²) Površina NRO	- 0.3904	0.4600	0.0510
Cup volume (mm ³) Prostornina ekskavacije	- 0.1216	0.0520	< 0.0001*
Rim volume (mm ³) Prostornina NRO	- 0.3940	0.2516	0.0021*
Mean cup depth (mm) Povprečna globina ekskavacije	- 0.2134	- 0.0062	< 0.0001*
Maximum cup depth (mm) Največja globina ekskavacije	- 0.2870	0.1946	0.0108*
Height variation contour (mm) Razlike v višini začrtane meje papile	- 0.2092	0.2876	0.0537
Mean RNFL thickness (mm) Povprečna debelina PRŽV	- 0.2256	0.1616	0.0156*
RNFL cross-sectional area (mm ²) Površina prečnega prereza PRŽV	- 1.0960	0.7236	0.0062*

ONH - optic nerve head / papila vidnega živca, NRO - nevroretinski obroč, RNFL - retinal nerve fibre layer, PRŽV - plast retinalnih živčnih vlaken, * signifikant / statistično značilno

- Harju M, Vesti E. Scanning laser ophthalmoscopy of the optic nerve head in exfoliation glaucoma and ocular hypertension with exfoliation syndrome. *Br J Ophthalmol* 2001; 85: 297-303.
- Jonas JB, Mardin CY, Gründler AE. Comparison of measurements of neuroretinal rim area between confocal laser scanning tomography and planimetry of photographs. *Br J Ophthalmol* 1998; 82: 362-6.
- Schuman JS, Kim J. Glaucoma diagnosis and management. Imaging of the optic nerve head and nerve fiber layer in glaucoma. *Ophthalmol Clin N Am* 2000; 13: 383-406.
- Mikelberg FS. Ophthalmic imaging and diagnostics. Scanning laser ophthalmoscopy of the optic disc in glaucoma with the Heidelberg Retina Tomograph. *Ophthalmol Clin N Am* 1998; 11: 435-44.
- Janknecht P, Funk J. Optic nerve head analyser and Heidelberg Retina Tomograph: accuracy and reproducibility of topographic measurements in a model eye and volunteers. *Br J Ophthalmol* 1994; 78: 760-8.
- Zeimer R, Shahidi M, Mori M, Zou S, Asrani S. A new method for rapid mapping of the retinal thickness at the posterior pole. *Invest Ophthalmol Vis Sci* 1996; 37: 1994-2001.
- Bland JM, Altman DG. Statistical methods for assessing agreement between two methods of clinical measurement. *Lancet* 1986; 307-10.
- Blackmann NJM. Reproducibility of clinical data I: continuous outcomes. *Pharmaceut Statist* 2004; 3: 99-108.
- Itai N, Tanito M, Chihara E. Comparison of optic disc topography measured by Retinal Thickness Analyzer with measurement by Heidelberg Retina Tomograph. *Jpn J Ophthalmol* 2003; 47: 214-20.
- Rohrschneider K, Burk RO, Kruse FE, Volcker HE. Reproducibility of the optic nerve head topography with a new laser tomographic scanning device. *Ophthalmology* 1994; 101: 1044-9.
- Martinez de la Casa JM, Garcia Feijoo J, Castillo Gomez A, Garcia Sanchez J. Correlations between retinal thickness analyser (RTA) and confocal scanning laser tomography (HRT) in optic disc analysis. *Arch Soc Esp Ophthalmol* 2004; 79: 21-5.
- Wollstein G, Garway-Heath DF, Hitchings RA. Identification of early glaucoma cases with the scanning laser ophthalmoscope. *Ophthalmology* 1998; 105: 1557-63.