

PROGRESSION OF HIP DYSPLASIA IN 40 POLICE WORKING DOGS: A RETROSPECTIVE STUDY

Bojan Zorko ^{1*}, Teodora Ivanuša ¹, Rok Pelc ²

Addresses of authors: ¹ Small Animal Clinic, Veterinary Faculty, Gerbičeva 60, 1000 Ljubljana; ² Department for Police Working Dogs of Ministry for Internal Affairs, Zlatek 6, 1000 Ljubljana, Slovenia

* Corresponding author, Email: bojan.zorko@vf.uni-lj.si

Summary: The aim of the study was to evaluate the effects of progression of CHD and degenerative joint disease on a working capability of population of police working dogs. In the first part of the study, we reviewed the whole health documentation of all dogs and gathered all necessary radiographs of hip joints that were taken at first initial procurement. In the second part, clinical examination and radiographs of all dogs were taken 60 months after first examination and the progression of hip dysplasia was evaluated by the FCI scheme. All dogs were male, 35 German shepherds and 5 Rottweilers. The Norberg-Olsson angle in the first set of radiographs was $105.54 \pm 3.22^\circ$ in 37 dogs without hip dysplasia and $100.17 \pm 2.99^\circ$ in 3 dogs with initial mild dysplasia. In the second set of radiographs taken after 60 months of service the Norberg-Olsson angle was $105.60 \pm 3.67^\circ$ in 23 dogs with no signs of hip dysplasia and $101.62 \pm 4.49^\circ$ in 17 dogs with hip dysplasia. On the first set of radiographs, secondary degenerative changes were found in 3 dogs with initial mild dysplasia (7.5 %) and in 14 dogs (35 %) on second radiographs. The position of the centre of the femoral head on first radiographs was outside of dorsal acetabular rim in 25 (31.25 %) of estimated hip joints ($n = 80$); at the level of the rim in 30 (37.5 %) and inside in 25 (31.25 %). On second radiographs it was outside in 41 (51.25 %); at the level of the rim in 26 (32.5 %); and inside in 13 (31.25 %) of estimated hip joints. The mean femoral angle of inclination for all 40 dogs was $132.50 \pm 4.39^\circ$. If it has occurred, the increase in degree of hip dysplasia was generally more than one degree. In 57.5 % of cases hip dysplasia was not determined on second radiographs. All dogs with some degree of hip dysplasia were German shepherds, but only one of them had clinical symptoms connected to CHD. The progression of hip dysplasia did not correlate with work period of the dogs, and has no influence on working ability of these dogs, despite their active duties. No dog in this study was lost due to CHD.

Key words: veterinary medicine; bone diseases, developmental; hip dysplasia, canine - radiography; dogs

Introduction

Hip dysplasia is a complex disease that affects humans and most domestic animals. The word dysplasia literally means abnormal development. Canine hip dysplasia (CHD) has been studied extensively since it was first reported in 1935 (1). The majority of research has been done on early diagnosis of CHD and its treatment.

CHD is not a congenital disease and cannot be diagnosed by conventional methods at birth. The hips are normal at birth but uneven growth between the skeletal and muscular system results

in a femoral head that is forced out of the acetabular cup. Subluxation of the femoral head occurs at an early age when the components of the joint are still cartilaginous and thus soft and malleable. This results in deformation of the acetabulum and remodelling of the femoral head leading to the development of a painful osteoarthritis. The course of the disease in a particular dog is influenced by growth rate, body weight, pattern of exercise and by other environmental factors (2).

The actual incidence of CHD is unknown, but the disease is known to affect large and giant breeds more commonly. Large-breed dogs are used by the police and armed Forces. Loss of military working dogs due to CHD has been reported to be 7 % in one study (3) and 12.9 % in another (4).

A long-term retrospective study of the effects of CHD on a random population of police working dogs was not found in the literature. A retrospective study of CHD in military dogs in San Antonio Texas was done in 1996 (5) and 1971 (6). Numerous authors have suggested that a significant percentage of performance dogs are lost as a result of CHD. In one study 35 % of working dogs were lost due to CHD (7).

The present study was done to evaluate the possible effects of CHD on a population of working dogs and to answer the following questions: Did dogs initially graded as normal develop hip dysplasia or degenerative joint disease (DJD); was there any influence of CHD and degenerative joint disease on working capability; how many dogs were lost due to CHD; is present system of initial procurement radiographs and examinations of Slovenian police dogs appropriate.

Material and methods

Complete medical records and radiographic files of 40 police working dogs were selected from files maintained at the Department for police dogs of Ministry for Internal Affairs in Slovenia. The two breeds selected were German shepherd dog (35 dogs) and Rottweiler (5 dogs). For all 40 dogs medical records were required to be complete, and dogs had to be procured in 1992 or later. All dogs were male.

On initial evaluation dogs were approximately 20 months old (19.75), on final examination they were 7 years old (6.78). Period between first and final radiographs was approximately 60 months.

All dogs performed similar duties and were kept in similar environment. All dogs had been active as police working dogs despite the presence or absence of CHD.

For each dog pelvic radiographs made at initial procurement and on final pelvic examination were graded. Each dog was clinically examined for any signs of lameness, pain or neurologic deficit. Before taking radiographs all dogs were sedated with medetomidin (0.05 mg/kg Domitor Finland).

A data sheet was prepared and each dog was assigned a number from one to 40. A complete review was performed of each dog's medical record. Data recorded included name and tattoo number, breed, sex, type of dog (patrol, detection...), age at procurement, date of procurement, origin of dog, total years of service, all clinical history and data relating to hind limb lameness or inability to perform to mission standards.

After all data was obtained two radiologists

reviewed the pelvic radiographs for FCI grading and for the presence of DJD.

Pelvic radiographs of each dog were checked for proper labelling, dates and position and were verified in the medical record. They were graded according to the FCI current grading system from A to E. The Norberg-Olsson angle and angle of inclination were measured at first. Then the position of the centre of the femoral head relative to the dorsal acetabular rim was estimated. Each measurement was repeated three times and the mean value was recorded. The dogs with the presence of DJD were divided in six groups according to the location of osteophyte formation: Sclerosation of the femoral neck, changes on the femoral head, changes on the femoral neck, changes of the acetabulum, changes on the dorsal acetabular rim and Morgan line.

Dogs were considered to have CHD if they did not rate as A or B grade.

Norberg-Olsson angles, angles of inclination and position of the centre of the femoral head measurements were plotted against age and the time of examination. The relationship between angles, measurements and advancing age were investigated using correlation analysis.

The mean month of work for normal and dysplastic dogs were evaluated using Student t-test. The correlation between Norberg-Olsson angle and progression of DJD was estimated with Pearson's correlation coefficient.

Results

Out of the 40 evaluated, 3 dogs (7.5 %) were considered dysplastic at initial examination. All of them were German shepherd dogs and were graded as C1. They already had mild degenerative changes on femoral neck.

Grading of the second set of radiographs resulted in a total of 23 (57.5 %) normal dogs and 17 (42.5 %) dysplastic dogs. All dysplastic dogs were German shepherd dogs, 8 of them were graded as C1, 6 as C2, two as D1 and one as D2 (Fig. 1). 14 of them had mild to moderate secondary degenerative changes, mainly on the femoral neck and head. The increase in degree of hip dysplasia in all dogs was mainly just over one degree, if it has occurred (Fig. 2 and 3).

The total number of months worked by the normal dogs was compared with the total months worked by the dysplastic dogs. No significant difference was found between the two groups (p greater than 0.05). The mean working period in dysplastic dogs was 61.29 ± 22.84 months. The

mean working period in normal dogs was 59.87 ± 22.40 months.

On final clinical and neurological examination, 20 dogs (50 %) showed signs of hind-limb lameness or hind-limb ataxia and difficulty with obstacles. But only in one dog (2.5 %) this was due to DJD of the hip joint, in all other cases this signs were due to lumbosacral disease (typical back pain, hyperesthesia, anal hyporeflexia, pelvic limb paresis, self mutilation, tail paresis). No dog in this study was lost due to CHD.

At first radiographs mean Norberg-Olsson angle was $105.54 \pm 3.22^\circ$ in 37 dogs with no hip dysplasia and $100.17 \pm 2.99^\circ$ in 3 dogs with initial mild dysplasia. At second radiographs after sixty months of service mean Norberg-Olsson angle was $105.60 \pm 3.67^\circ$ in 23 dogs with no signs of hip dysplasia and $101.62 \pm 4.49^\circ$ in 17 dogs with CHD. In 14 dogs (35 %) initially considered normal and with signs of CHD on final radiograph, there was significant difference between Norberg-Olsson angle measurements ($P = 0.041$). Mean Norberg-Olsson angle in these dogs on initial radiographs was $104.54 \pm 2.66^\circ$ and $102.68 \pm$

3.90° on final examination.

On first radiographs secondary degenerative changes were found in 3 dogs (7.5 %) and in 14 dogs (35 %) on second radiographs. Only 3 of them had symmetrical changes. Mean Norberg-Olsson angle in dogs with CHD and DJD was $100.84 \pm 4.54^\circ$. Mean Norberg-Olsson angle in dogs with signs of CHD but without signs of DJD was $102.60 \pm 4.39^\circ$. Norberg-Olsson angle does not correlate with progression of DJD.

The mean femoral angle of inclination for all 40 dogs was $132.50 \pm 4.39^\circ$. There was no significant difference between normal and dysplastic dogs, nor between first and final radiographic examination.

The position of the centre of femoral head on first radiographs was outside of dorsal acetabular rim in 25 (31.25 %) of estimated hip joints ($n = 80$); at the level of the rim in 30 (37.5 %); and inside in 25 (31.25 %) hip joints. On second radiographs it was outside in 41 (51.25 %); at the level of the rim in 26 (32.5 %); and inside in 13 (31.25 %) of estimated hip joints. The difference is significant.

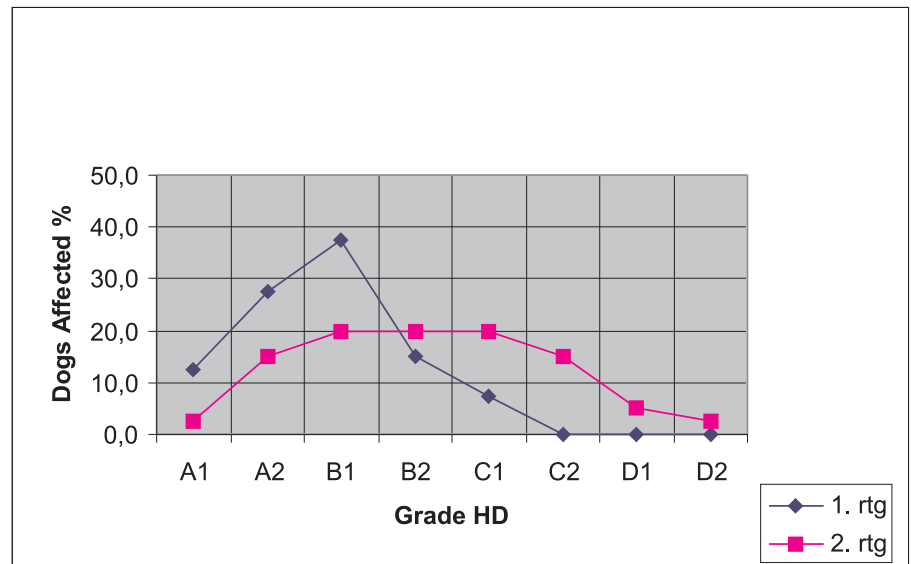


Figure 1: Hip dysplasia grades on initial (1. rtg) and final (2. rtg) radiographic examination

Discussion

All dogs in this study performed similar duties including attack work, tracking, foot patrols, which demands a great deal of jumping and physical exertion. All dogs are maintained in excellent physical condition by routine obstacle course work and specialty training. Most dogs work 8 to 12 hours daily several times a week. They were fed a standard diet. Each dog's weight is regulated

and kept within standard limits established by the Police Veterinary Department.

Numerous authors have suggested that a significant percentage (between 7 % and 35 %) of performance dogs are lost as a result of CHD (3,4,6,7,8). This study demonstrates a significantly lower percentage. Only one dog (2.5 %) was lame because of CHD and DJD, but none was euthanized because of CHD.

Of the 40 dogs evaluated, 3 dogs (7.5 %) were

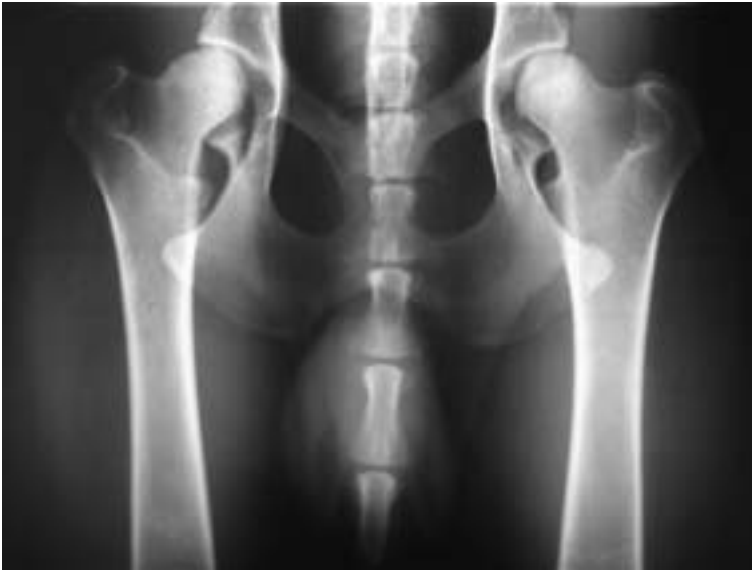

Figure 2: Initial radiograph of 26 month old german shepherd dog graded as L = C1 R = B2

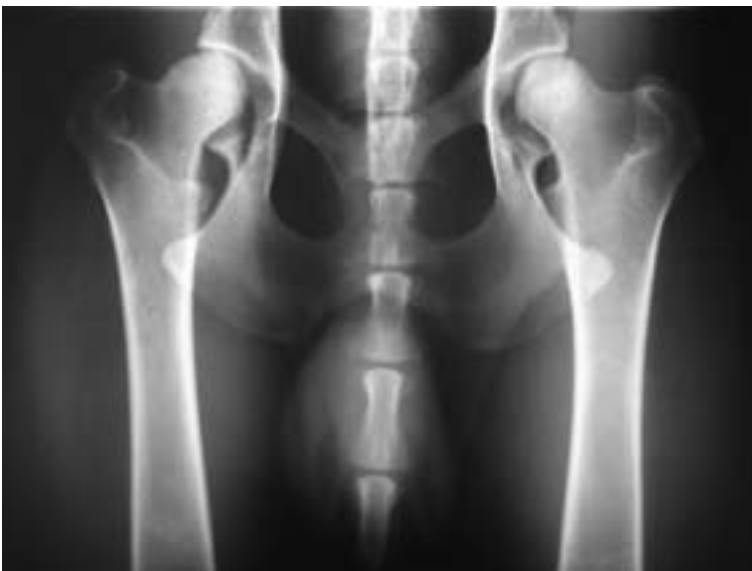


Figure 3: Final radiograph of the same dog (8 years old) graded as L = D1 R = C2

considered dysplastic on initial examination. All of them were German shepherd dogs and were graded as C1. Dogs that are severely dysplastic are rejected on initial procurement based on the results of pelvic radiography and physical examinations. Final grading resulted in a total of 23 (57.5 %) normal dogs and 17 (42.5 %) dysplastic dogs, 14 of dysplastic dogs (35 %) already developed mild to moderate degenerative changes. All dysplastic dogs were German shepherd dogs. It is not known if the percentage of dysplastic dogs of each breed seen in this study is similar to the actual incidence of dysplasia in each breed, because more rottweilers with normal pelvic radi-

ographs were available for procurement than German shepherd dogs. However, it may be presumed that the incidence of CHD in German shepherd dogs was over 50 % on final examination and all rottweilers were normal. Despite high percentage of dogs with CHD and DJD all of them but one were in good physical condition. Dogs selected with temperaments compatible for this type of training may have high pain tolerance (2).

Several authors have suggested an upper age limit for radiographic evaluation of CHD. Six years of age has been suggested, because it is thought that normal dogs would show degenerative changes due to aging and that these changes

would be associated incorrectly with CHD (2). In our study dogs on final examination were approximately 7 years old (6.78), and 11 (27.5 %) of 37 dogs that had normal hip joints initially developed mild to moderate DJD, whereas 100 % of dogs initially diagnosed with hip dysplasia developed moderate DJD, which put their relative risk for development of DJD much higher than that of dogs with normal hips.

The mean Norberg-Olsson angle for normal dogs in our study was $105.54 \pm 3.22^\circ$ and $101.62 \pm 4.49^\circ$ for dysplastic dogs which is similar to $104.99 \pm 4.12^\circ$ for normal and $100.84 \pm 5.47^\circ$ for dysplastic dogs in another study (5).

A significant difference existed between Norberg-Olsson angle measurements in 14 dogs (35 %) which were initially considered normal and as dysplastic on final examination ($P = 0.041$), which is similar with a previous studies (3,5,6). The Norberg-Olsson angle in these dogs showed tendency to decrease with progression of dysplasia, whereas in normal dogs it showed tendency to increase with age, which may put the prognostic value of Norberg-Olsson angle in question.

Norberg-Olsson angle did not correlate with progression of degenerative changes. The appearance of subluxation does not appear to lead inevitably to secondary degenerative changes which agrees with a previous study (5). Further studies appear to be indicated to follow dysplastic and normal dogs over their lifetimes to better determine a cause and effect relationship between subluxation (joint laxity) and the development of secondary degenerative changes.

The mean angle of inclination in our study was $132.50 \pm 4.39^\circ$ which is similar to $132.49 \pm 5.00^\circ$ in another (5). Angles of inclination did not correlate significantly with CHD ($P > 0.05$) in this study. This agrees with previous studies which concluded that femoral angles of inclination did not influence the development of CHD (5,9).

There was a significant difference in the position of the centre of the femoral head in relation to the dorsal acetabular rim between first and final evaluation ($P < 0.05$), which gives this grade very important place.

There was no significant difference in the total number of months worked between normal and dysplastic dogs ($P > 0.05$). This also agrees with a previous study (4).

Canine hip dysplasia appears to be a problem that will not limit most police working dogs severely until old age. Of course this takes into account the fact that almost all severely dysplastic dogs on initial procurement radiographs and examinations are excluded from the police service. A significant percentage of police working dogs are nowadays lost due to lumbosacral disease.

This study has confirmed that the present system of initial procurement radiographs and examinations of Slovenian police working dogs is appropriate.

References

1. Schnelle GB. Some new diseases in the dog. *Am Kennel Gaz* 1935; 52: 25-6.
2. Morgan JP, Wind A, Davidson AP. Hereditary bone and joint diseases in the dog. Hannover: Schlutersche, 2000: 109-203.
3. Dutton RE, Moore GE. Clinical review of death/euthanasia in 123 military working dog necropsies. *Military Med* 1987; 152: 489-93.
4. Banfield CM, Bartels JE, Hudson JA, Wright JC, Montgomery RD, Hathcock JT. A retrospective study of canine hip dysplasia in 116 military working dogs. Part II. *J Am Anim Hosp Assoc* 1996; 32: 423-30.
5. Banfield CM, Bartels JE, Hudson JA, Wright JC, Hathcock JT, Montgomery RD. A retrospective study of canine hip dysplasia in 116 military working dogs. Part I. *J Am Anim Hosp Assoc* 1996; 32: 413-22.
6. Townsend LR, Gillette EL, Lebel JL. Progression of hip dysplasia in military working dogs. *J Am Vet Med Assoc* 1971; 159: 1129-33.
7. Zorko B. Progression of canine hip dysplasia in 40 police working dogs. In: International Veterinary Radiology Association Congress. Midrand, South Africa, 2003: 92.
8. Brass W. Hip dysplasia in dogs. *J Small Anim Pract* 1989; 30: 166-70.
9. Hauptman J, Cardinet GH, Morgan JP, Guffy MM, Wallace LJ. Angles of inclination and anteversion in hip dysplasia in the dog. *Am J Vet Res* 1985; 46: 2033-6.
10. Moore GE, Burkman KD, Carter MN, Peterson MR. Causes of death or reasons for euthanasia in military working dogs: 927 cases (1993-1996). *J Am Vet Med Assoc* 2001; 219: 209-14.

RETROSPEKTIVNA ŠTUDIJA NAPREDOVANJA KOLČNE DISPLAZIJE PRI 40 POLICIJSKIH DELOVNIH PSIH

B. Zorko, T. Ivanuša, R. Pelc

Povzetek: Proučevali smo napredovanje kolčne displazije pri 40 policijskih delovnih psih. Namen našega dela je bil, ugotoviti učinke kolčne displazije na populacijo delovnih psov, še posebej, ali ima kolčna displazija in posledična degenerativna bolezen sklepa vpliv na delovno sposobnost teh psov. Najprej smo pregledali celotno zdravstveno dokumentacijo vseh psov in zbrali vse rentgenograme kolčnih sklepov, ki so bili narejeni ob sprejemu psov v policijo. V drugem delu raziskave smo vse pse ponovno klinično pregledali po 60 mesecih službe in naredili kontrolne rentgenske slike kolkov. Ugotavljali smo napredovanje kolčne displazije z ocenjevanjem po shemi FCI. Vsi psi so bili moškega spola, 35 je bilo nemških ovčarjev, pa 5 rotvajlerjev. Na prvih rentgenogramih je bil pri 37 psih brez znakov displazije Norbergov kot $105,54 \pm 3,22^\circ$, pri treh psih z začetno blažjo stopnjo displazije pa $100,17 \pm 2,99^\circ$. Na kontrolnih rentgenogramih po 60 mesecih dela je bil pri 23 psih brez displazije Norbergov kot $105,60 \pm 3,67^\circ$, pri 17 psih, z displazijo pa $101,62 \pm 4,49^\circ$. Na začetnih rentgenogramih smo našli degenerativne spremembe pri 3 psih (7,5 %), na kontrolnih rentgenogramih pa že pri 14 psih (35 %). Položaj centra stegnene glavice je bil glede na dorzalni acetabularni rob na prvih rentgenogramih zunaj roba pri 25 (31,25 %) sklepah (n = 80), na robu pri 30 sklepah (37,5 %) in znotraj roba pri 25 sklepah (31,25 %). Na kontrolnih rentgenogramih je bil zunaj roba pri 41 sklepah (51,25 %), na robu pri 26 sklepah (32,5 %) in znotraj roba pri 13 sklepah (31,25 %). Če se je stopnja displazije, povečala, se je večinoma za več kot eno stopnjo. Pri 57,5 % psov na kontrolnem slikanju displazije nismo našli. Vsi psi z znaki displazije so bili nemški ovčarji, vendar je imel samo eden (2,5 %) klinične znake bolezni. Kljub aktivni uporabi napredovanje kolčne displazije ni bilo v korelaciji s starostjo ali časom uporabe psov, prav tako ni vplivalo na delovno sposobnost teh psov. Noben pes v tej raziskavi ni bil izločen zaradi kolčne displazije.

Ključne besede: veterinarska medicina; kost, boleznirazvojnje; kolk, displazija psa - radiografija; psi