

First case of interconnected clusters of primary meningococcal arthritis and meningococcal meningitis due to *Neisseria meningitidis* serogroup B in Slovenia

Prvi primer povezanih skupkov primarnega meningokoknega artritisa in meningokoknega meningitisa zaradi *Neisserie meningitidis* skupine B v Sloveniji

Miha Simoniti,¹ Tanja Selič Kurinčič,¹ Alenka Trop Skaza,² Ines Kebler,² Metka Paragi,³ Tamara Kastrin³

Abstract

¹ Department of Infectious Diseases, General Hospital Celje, Celje, Slovenia

² National Institute of Public Health, Regional Unit Celje, Celje, Slovenia

³ Department of Public Health Microbiology, Centre for Medical Microbiology, National Laboratory of Health, Environment and Food, Ljubljana, Slovenia

Correspondence/ Korespondenca:

Miha Simoniti, e: miha.simoniti@gmail.com

Key words:

meningococcus; serogroup B; cluster; bone and joint infections

Ključne besede:

meningokok; skupina B; skupek; okužbe kosti in sklepov

In this report, we describe a case of interconnected clusters of invasive meningococcal disease due to *Neisseria meningitidis* serogroup B:P1.22,14:F5-1(ST-269) in young adults – a boyfriend and a girlfriend. The male was diagnosed with primary meningococcal septic arthritis of the right knee and the female was diagnosed with meningococcal meningitis with meningococemia a few hours later. Both were hospitalized at the General Hospital Celje and treated with ceftriaxone, but with different outcomes; the female recovered completely, while the male will probably have long-term sequelae of septic arthritis.

Izvleček

V članku opisujemo primer povezanega skupka invazivne meningokokne bolezni zaradi povzročitelja *Neisseria meningitidis* serološke skupine B:P1.22,14:F5-1(ST-269) pri mladih odraslih (fant in dekle). Pri moškem smo ugotavljali primarni meningokokni septični artritis desnega kolena in pri ženski meningokokni meningitis z meningokokcemijo z začetkom nekaj ur kasneje. Oba sta bila hospitalizirana v Splošni bolnišnici Celje in zdravljena s ceftriaksonom, a z različnima izidoma. Ženska je popolnoma ozdravela, medtem ko bo imel moški najverjetneje trajne posledice zaradi septičnega artritisa.

Cite as/Citirajte kot: Simoniti M, Selič Kurinčič T, Trop Skaza A, Kebler I, Paragi M, Kastrin T. First case of interconnected clusters of primary meningococcal arthritis and meningococcal meningitis due to *Neisseria meningitidis* serogroup B in Slovenia. *Zdrav Vestn.* 2021;90(5–6):266–74.

DOI: <https://doi.org/10.6016/ZdravVestn.3042>



Copyright (c) 2021 Slovenian Medical Journal. This work is licensed under a Creative Commons Attribution-NonCommercial 4.0 International License.

Received: 24. 2. 2020
Accepted: 19. 1. 2021



1 Introduction

Neisseria meningitidis (the meningococcus) is the cause of invasive meningococcal disease, ranging from mild bacteraemia to devastating purulent meningitis, sepsis, pneumonia and other, less common forms such as meningococcal arthritis (1). In 2017, 3,221 confirmed cases of invasive meningococcal disease (IMD), including 282 deaths, were reported in 30 EU/EEA Member States. Serogroup B caused 51% of cases overall and was the dominating serogroup in all age groups below 65 years (2). We present a cluster of two cases of invasive meningococcal disease – arthritis and meningococcaemia with meningitis. Both cases were caused by *Neisseria meningitidis* serogroup B and our cluster is the first to be reported in Slovenia.

2 Case reports

On 11 December 2018, a 23-year-old previously healthy male was examined in the Surgical Emergency Room of the General Hospital Celje because of swelling of his right knee that had occurred suddenly two days earlier; he could not remember any trauma that might have caused it. He had become febrile on 8 December 2018, a day before the knee swelling occurred, and reported about a rash on his torso. He had a headache which spontaneously resolved without intervention. However, during the

medical examination, the focus was only on the knee and there was no mention of a febrile illness. The surgeon described a significant circular swelling of the knee with positive ballottement and no signs of inflammation such as redness or heat. The surgeon ordered an X-ray that showed no signs of skeletal trauma, and performed a puncture to obtain a fluid sample that was then sent for culture to the microbiology laboratory.

On 13 December 2018, he was contacted to return to the hospital as the Gram stain of the joint fluid showed Gram-negative diplococci and the culture grew *Neisseria meningitidis*. He was immediately admitted to the Orthopaedics Ward. The epidemiologist of the National Institute of Public Health, Regional Unit Celje, was notified about the patient. An infectious disease specialist was called in for consultation and examined the patient: a petechial rash could be seen on his limbs, but the patient did not present with meningeal symptoms. Laboratory testing revealed moderately elevated CRP and mildly elevated procalcitonin without leukocytosis (Table 1). The rest of the findings were within normal limits, including coagulation studies; laboratory testing was not repeated until 7 days later, after which inflammatory parameters had normalized. After blood cultures were drawn, the patient started antibiotic therapy

Table 1: Laboratory testing results of the male patient.

Variable	Reference range	On admission
White blood cell count (per mm³)	4,000 – 10,000	8,100
Platelet count (per mm³)	150,000 – 350,000	290,000
CRP (mg/L)	<5	87.0
Procalcitonin	<0.5	1.2

with ceftriaxone 2g/12h. A synovectomy was performed in the patient on 13 December 2018.

Susceptibility testing of *Neisseria meningitidis* from the synovial fluid showed excellent susceptibility to all tested antibiotics. Blood cultures drawn prior to the start of antibiotic therapy were negative for bacterial growth, as was the synovial sample taken during the surgery.

The subsequent course and hospitalization were uneventful. The patient was afebrile and he developed no new symptoms. However, symptoms concerning his right knee abated only slowly and incompletely, with pain and poor mobility persisting despite physical and analgesic therapy. He received parenteral ceftriaxone for 14 days and on 27 December 2018 he was switched to oral ciprofloxacin therapy (750 mg twice daily). He was discharged from the hospital on 31 December 2018. After completing the three-week antibiotic course, the patient came in for a check-up. Due to persistent poor mobility of the right knee and only 20 degree flexion, the patient was referred to balneorehabilitation at a thermal spa.

After 6 months of follow-up no significant improvement of symptoms had been achieved with loss of mobility persisting, especially with flexion.

On 12 December 2018, the first patient's girlfriend, a previously healthy 23-year-old woman, fell ill with a sore throat, a temperature of up to 40 degrees Celsius, and generalized muscle and joint pain. Her right ankle and left wrist were particularly painful, but without any signs of arthritis. On 13 December 2018, she noticed a red rash spreading over her whole body. She did not have a headache. She was examined in the Infectious Diseases Emergency

Room at the General Hospital Celje on 13 December 2018. By that time, it had already been confirmed that her boyfriend was ill with meningococcal septic arthritis. She was tachycardic, hypertensive and febrile. Petechial haemorrhage was noticed on her body. There was mild pharyngitis without tonsillitis, and the rest of the examination was unremarkable. Laboratory testing revealed a normal total leukocyte count with left shift and mildly elevated CRP, moderately elevated procalcitonin and creatinine (Table 2). Blood cultures were drawn and treatment with ceftriaxone 2g/12h started immediately afterwards. Laboratory testing 18 hours after admission showed a significant increase in inflammatory parameters and near-normalization of kidney function. The rest of the parameters tested, including hepatic enzymes, were within normal limits, including on admission. On 14 December 2018, a lumbar puncture was performed. Cerebrospinal fluid (CSF) was macroscopically cloudy and colourless. White blood cell count was 5205 leukocytes per mm³ with neutrophilic predominance, glucose was 2.51 mmol/L, and protein 1.51 g/L. A CSF sample was sent for microbiologic analysis – PCR Filmarray was positive for *N. meningitidis*, Gram stain showed damaged Gram-negative diplococci and culture was negative for bacterial growth – the lumbar puncture was performed after antibiotic therapy had commenced. Blood cultures also grew *N. meningitidis*. The regional epidemiologist was notified about this patient as well. Susceptibility testing of *N. meningitidis* from blood cultures showed excellent susceptibility to all tested antibiotics.

The subsequent clinical course was mostly uneventful as the patient became afebrile soon, with the repeated

Table 2: Laboratory testing results of the female patient.

Variable	Reference range	On admission	18 hours after admission
White blood cell count (per mm³)	4,000 – 10,000	8,900	10,500
Differential count (%)			
Neutrophils	40-75	80	61
Band forms	<4	12	15
Lymphocytes	20-50	6	19
Monocytes	2-10	2	4
Basophils	0-1	0	0
Eosinophils	<6	0	0
Platelet count (per mm³)	150,000 – 350,000	200	180
CRP (mg/L)	<5	87.0	183.4
Procalcitonin	<0.5	4.0	8.0
Creatinine (µmol/L)	44-80	130	102

laboratory testing showing a significant decrease in inflammatory parameter levels. Arthralgia had resolved completely by 22 December 2018, when the patient was discharged from the hospital after having been treated for 10 days with ceftriaxone. At home, she continued taking oral penicillin for 4 more days. By the first check-up on 16 January 2019, the patient had recovered completely.

In both cases, the isolates were *N. meningitidis* serogroup B. The isolates were serotyped by slide agglutination and the results were confirmed with molecular capsule typing by RT-PCR (3). The genome sequences of the isolates were determined on an Illumina MiSeq platform. Whole genome sequence (WGS) data were collected, de novo assembled and submitted for the automated annotation and analysis to the PubMLST/Neisseria website, BIGSdb (4).

Both isolates were ST-269, ST-269 complex, with the finetype B:P1.22,14:F5-1.

2.1 Epidemiological investigation

On 13 December 2018, the epidemiologist at the National Institute of Public Health, Regional Unit Celje, was informed of the isolation of *N. meningitidis* from the punctate of the male's knee, and also of the suspicion of meningococcal meningitis in the male's girlfriend a few hours later.

In accordance with invasive meningococcal disease intervention algorithm we identified 9 close contacts. Four contacts were family members – 3 adults and 1 child. All family members received antibiotic prophylaxis with ciprofloxacin – the adults received a single 500 mg dose, and the child received a single 250 mg dose. The other close contacts were friends with whom the patients had interacted on 8 December. They also received a single 500 mg dose of ciprofloxacin (5,6).

3 Discussion

Unusually, the patient with arthritis did not completely recover despite the adequate and even prolonged antibiotic and surgical therapy, perhaps due to a delay in starting treatment. Prompt recognition and treatment of the clinical syndrome and rapid epidemiological investigation and start of chemoprophylaxis are key to preventing progression of the disease in index cases and preventing further spread of the invasive disease in close contacts.

In Europe, the incidence rate of confirmed cases of invasive meningococcal disease is similar to that in Slovenia (0.5/100,000 inhabitants) (Table 3) (7). In 2017, the overall incidence for invasive meningococcal disease in Europe was 0.6/100,000 inhabitants. The clinical presentation was known for 1641 cases (51%). Meningitis or both meningitis and meningococemia was reported in 937 cases (57%), meningococemia only in 604 (37%), pneumonia in 19 (1%) and 'other' in 81 cases (5%) (2). As part of the national surveillance system of invasive bacterial infections in Slovenia, all invasive isolates of *N. meningitidis* are collected at the Department for Public Health Microbiology, National Laboratory of Health, Environment and Food in Ljubljana, where they are typed and the antibiotic susceptibility is determined (7).

In 2017, 8 isolates of *N. meningitidis* were received at the Department for

Public Health Microbiology, National Laboratory of Health, Environment and Food in Ljubljana, out of 11 that were reported in total in that year; the other 3 were not sent to the reference laboratory and were thus not analysed further. Out of these, six were isolated in children (under the age of 15 years) and two in the adult patient group (>15 years of age). The sample from which they were isolated was in five cases blood, in two cases blood and CSF at the same time, and in one case CSF. The referring diagnosis was known to the laboratory in five cases; in four cases it was meningitis and in one case sepsis; in the rest, the clinical diagnosis was not made available to the laboratory. In six cases, we demonstrated the serogroup B and in two cases the serogroup C (7).

In 2018, 19 cases of invasive meningococcal disease were confirmed by the Department for Public Health Microbiology, National Laboratory of Health, Environment and Food in Ljubljana (Figure 1) (8). Eighteen cases were laboratory-confirmed, and one was a potential case without laboratory confirmation. In three cases, this was demonstrated only by the molecular RT-PCR method from the patient's blood. Fifteen isolates of *N. meningitidis* were cultivated. In the age group of children under the age of 15 years the laboratory received six isolates of *N. meningitidis* and in one additional case *N. meningitidis* serogroup C was demonstrated only by RT-PCR. In three cases the sample

Table 3: Reported cases and incidence rate of invasive meningococcal diseases. Referenced after Sočan M, et al. (7).

Year	2013	2014	2015	2016	2017
Number of reported cases	11	8	20	7	11
Cases/100,000	0.5	0.4	1.0	0.3	0.5

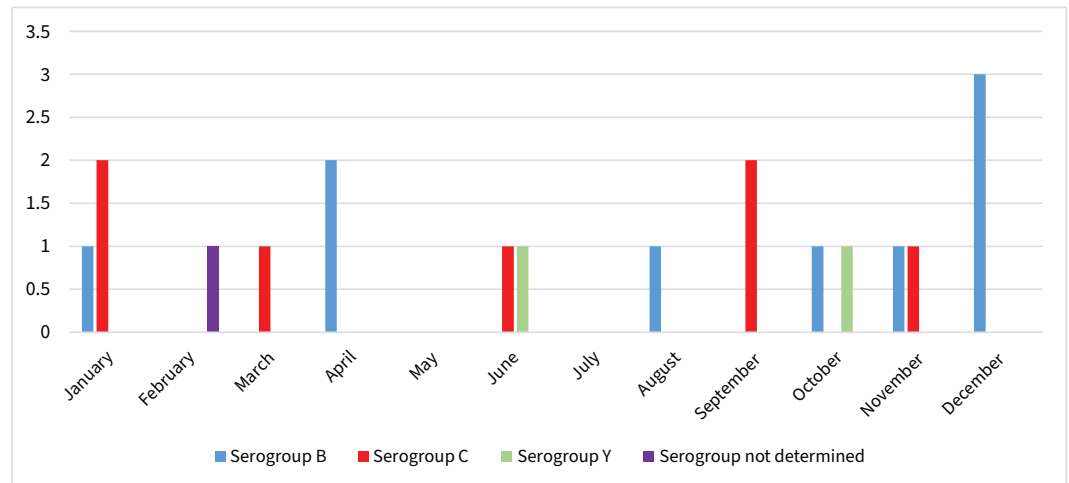


Figure 1: Invasive meningococcal disease: serogroup identification in 2018. Referenced after (8).

was CSF, in two it was blood, and in two cases blood and a CSF sample at the same time. The clinical diagnosis was known to the laboratory only in one case - meningitis. In the adult patient group (>15 years of age) the laboratory received 11 samples, two of which were demonstrated only molecularly. In nine cases the sample was blood, in one case it was blood and CSF at the same time, and in one case meningococcus was isolated from the knee puncture. The clinical diagnosis was known to the laboratory in six cases, in three cases there was meningitis and in two sepsis, in one case it was pneumonia and in one case it was septic arthritis. In eight cases we demonstrated *N. meningitidis* serogroup B, in seven cases *N. meningitidis* serogroup C, in two cases *N. meningitidis* serogroup Y, and in one case serogroup was not determined (Figure 1). Other serogroups of meningococcal disease are very rare in Slovenia (M. Paragi Personal Communication 4. 2. 2019; 8,9).

At this point it should be noted that the laboratory does not always receive information about the patient and their

clinical information in the referral document along with samples for microbiological analysis; this accounts for the lack of clinical diagnosis in several of the isolates mentioned in the text.

A cluster in the field of epidemiology means an aggregation of cases of a disease or another health-related condition; in our case, it refers to two patients, close contacts to each other, developing the same infectious disease in a short period of time. The highest risk of transmission of invasive meningococcal disease is to people who live in the same household as a case of meningococcal disease; in such cases, the absolute risk of developing a second case of invasive meningococcal disease within 30 days is 1 in 300 if chemoprophylaxis is not administered. This risk is the highest in the first 7 days and then falls rapidly (9,10,11,12). Chemoprophylaxis should be administered to close contacts that were in contact with the index patient during the 7 days before symptoms appear and for the first 24 hours from the start of antibiotic treatment. The purpose of chemoprophylaxis is to reduce the incidence of invasive meningococcal

disease among close contacts by eliminating established or newly acquired carriage of *N. meningitidis* that could cause invasive disease. In our case, ciprofloxacin chemoprophylaxis was given to all close contacts (5).

In 2017, 7 out of 8 isolates were susceptible to penicillin, as were the isolates from our patients (7). They were both treated with ceftriaxone instead of the more appropriate penicillin. The decision to treat with ceftriaxone and administer ciprofloxacin prophylaxis could be explained by easier use and convenient dosing, even though such decisions are not strictly medically correct; a single daily dose of ceftriaxone and a single dose of prophylactic ciprofloxacin instead of multiple doses of penicillin daily and two days of rifampicin prophylaxis. The authors do not condone such behaviour and recommend that medically appropriate instead of more convenient antibiotics be used for invasive meningococcal as well as other bacterial infections.

Our patients were treated as follows: the female patient with meningococemia and meningitis for 14 days (10 days of parenteral ceftriaxone and 4 days of oral penicillin), and the male patient with arthritis for 21 days (14 days of parenteral ceftriaxone and 7 days of oral ciprofloxacin). The duration of treatment for the female patient was longer than that suggested by guidelines for the treatment of meningococcal meningitis, which is 5-7 days (13). The duration of treatment for meningococcal arthritis has not yet been established; 21-day treatment is recommended for septic arthritis caused by common microorganisms, such as *Staphylococcus aureus*, but is probably excessive in the case of meningococcal joint infections; in a

large series, 4-7 days of treatment were enough for cure (14).

Septic arthritis is an acute bacterial infection of synovial joints. It is an infectious disease that requires early diagnosis and prompt treatment with a combination of antibiotics and surgical drainage. In Slovenia, the most commonly affected joint is the knee (48.9%), followed by the shoulder, wrist, and ankle. The most common cause of septic arthritis is *Staphylococcus aureus*, followed by streptococci; Gram-negative organisms are causative in 21% of cases, and of these, *N. meningitidis* is reported very rarely - in approximately 1% of all cases of septic arthritis (14,15). The frequency of arthritis secondary to meningococcal disease is variable, but the latest series reported a prevalence of 2% to 12.5% (14,16). In experimental models of bacterial arthritis, cartilage destruction starts after only eight hours of joint infection. The administration of antibiotics 24 hours after the infection causes significant joint destruction with an overall loss of collagen of up to 37%. Although there have been no formal long-term studies carried out, long-term outcomes after primary meningococcal arthritis appear to be favourable. In contrast to literature reporting no major sequelae after meningococcal arthritis, our patient did suffer from complications and sequelae in the form of loss of knee mobility (17,18,19).

The presented male patient with an atypical clinical course started treatment with antibiotics and surgery 3 days after the first onset of symptoms. Based on the published data for overall prognosis of septic arthritis with late treatment, irreversible joint destruction can be expected (18).

4 Conclusion

We confirmed the first cluster of invasive meningococcal disease in Slovenia.

Meningococcal arthritis is a very rare disease that can be overlooked if the patient's case history is incomplete. Prompt diagnosis and combination treatment with antibiotics and surgical drainage are crucial to prevent irreversible joint destruction. A brief description of the clinical picture with the sample sent for microbiological analysis would also be of great help to the microbiology laboratory responsible for identifying the causative microorganism.

Inform consent of the patient

Both patients gave informed consent for the publication of their cases.

Acknowledgement

This publication made use of the Neisseria Multi Locus Sequence Typing website (<https://pubmlst.org/neisseria/>) sited at the University of Oxford (Jolley et al. Wellcome Open Res2018, 3:124 [version 1; referees: 2 approved]). The development of this site has been funded by the Wellcome Trust and European Union.

References

1. Bennet JE, Dolin R, Blaser MJ. Mandell, Douglas, and Bennett's Principles and Practice of Infectious Diseases. 9th ed. Philadelphia (PA): Elsevier/Saunders; 2020. pp. 2585-607.
2. European Centre for Disease Prevention and Control. Invasive meningococcal disease: surveillance report: annual epidemiological report for 2017. Solna: ECDC; 2019 [cited 21 April 2019]. Available from: https://www.ecdc.europa.eu/sites/default/files/documents/AER_for_2017-invasive-meningococcal-disease.pdf.
3. Castillo D, Harcourt B, Hatcher C, Jackson M, Katz L, Mair R, et al. Laboratory methods for the diagnosis of meningitis caused by Neisseria meningitidis, Streptococcus pneumoniae, and Haemophilus influenzae. 2nd ed. Geneva: World Health Organization; 2011 [cited 2019 Feb 5]. Available from: <https://www.cdc.gov/meningitis/lab-manual/full-manual.pdf>.
4. Jolley KA, Maiden MC. BIGSdb: scalable analysis of bacterial genome variation at the population level. BMC Bioinformatics. 2010;11(1):595. DOI: 10.1186/1471-2105-11-595 PMID: 21143983
5. Grgič Vitek M, Učakar V. Invazivna meningokokna bolezen: algoritem ukrepanja: posodobljeno maj 2015. Ljubljana: Nacionalni inštitut za javno zdravje; 2017 [cited 2019 Feb 5]. Available from: https://www.nijz.si/sites/www.nijz.si/files/publikacije-datoteke/algoritem_meningo_posodobljen_2015_04_05_2015.pdf.
6. European Centre for Disease Prevention and Control. Public health management of sporadic cases of invasive meningococcal disease and their contacts. Solna: ECDC; 2010 [cited 2019 Feb 5]. Available from: https://www.ecdc.europa.eu/sites/default/files/media/en/publications/Publications/1010_GUI_Meningococcal_guidance.pdf.
7. Sočan M, Frelj T, Klavs I, Grilc E, Grgič Vitek M, Učakar V. Epidemiološko spremljanje nalezljivih boleznij v Sloveniji v letu 2018. Ljubljana: Nacionalni inštitut za javno zdravje; 2018 [cited 2019 Feb 5]. Available from: https://www.nijz.si/sites/www.nijz.si/files/uploaded/epidemiolosko_spremljanje_nalezljivih_boleznij_v_sloveniji_v_letu_2018.pdf.
8. Tedenski pregled dogodkov, nalezljive bolezni 4/2019 = Weekly report, Communicable diseases 4/2019. Ljubljana: Nacionalni inštitut za javno zdravje; 2019.
9. Trop Skaza A, Selič Kurinčič T, Bešković L, Paragi M, Božanič V. First case of meningococcal meningitis due to Neisseria meningitidis serogroup Z' in Slovenia, December 2010. Euro Surveill. 2011;16(6):2-4. DOI: 10.2807/es.e16.06.19786-en PMID: 21329646
10. Hastings L, Stuart J, Andrews N, Begg N. A retrospective survey of clusters of meningococcal disease in England and Wales, 1993 to 1995: estimated risks of further cases in household and educational settings. Commun Dis Rep CDR Rev. 1997;7(13):R195-200. PMID: 9447784
11. De Wals P, Hertoghe L, Borlée-Grimée I, De Maeyer-Cleempoel S, Reginster-Haneuse G, Dachy A, et al. Meningococcal disease in Belgium. Secondary attack rate among household, day-care nursery and pre-elementary school contacts. J Infect. 1981;3(1):53-61. DOI: 10.1016/S0163-4453(81)80009-6 PMID: 7185953

12. Zangwill KM, Schuchat A, Riedo FX, Pinner RW, Koo DT, Reeves MW, et al. School-based clusters of meningococcal disease in the United States. Descriptive epidemiology and a case-control analysis. *JAMA*. 1997;277(5):389-95. DOI: [10.1001/jama.1997.03540290041030](https://doi.org/10.1001/jama.1997.03540290041030) PMID: [9010171](https://pubmed.ncbi.nlm.nih.gov/9010171/)
13. Čižman M, Beović B. Kako predpisujemo protimikrobna zdravila v bolnišnicah. 2., dopolnjena izd. Ljubljana: Sekcija za protimikrobno zdravljenje Slovenskega zdravniškega društva; 2013.
14. Cabellos C, Nolla JM, Verdaguer R, Pelegrin I, Ribera A, Ariza J, et al. Arthritis related to systemic meningococcal disease: 34 years' experience. *Eur J Clin Microbiol Infect Dis*. 2012;31(10):2661-6. DOI: [10.1007/s10096-012-1610-1](https://doi.org/10.1007/s10096-012-1610-1) PMID: [22476361](https://pubmed.ncbi.nlm.nih.gov/22476361/)
15. Ross JJ, Saltzman CL, Carling P, Shapiro DS. Pneumococcal septic arthritis: review of 190 cases. *Clin Infect Dis*. 2003;36(3):319-27. DOI: [10.1086/345954](https://doi.org/10.1086/345954) PMID: [12539074](https://pubmed.ncbi.nlm.nih.gov/12539074/)
16. Weisfelt M, van de Beek D, Spanjaard L, de Gans J. Arthritis in adults with community-acquired bacterial meningitis: a prospective cohort study. *BMC Infect Dis*. 2006;6(1):64. DOI: [10.1186/1471-2334-6-64](https://doi.org/10.1186/1471-2334-6-64) PMID: [16571115](https://pubmed.ncbi.nlm.nih.gov/16571115/)
17. Furlan Lotrič S, Volkar Meglic J, Kolšek M, Bogovič P. Characteristics of patients with septic arthritis in Slovenia. *Orthop Proc*. 2015;97-B:62.
18. Boyle C, Howard T, Griffith D, Cowie J. Primary meningococcal septic arthritis with multiple native joint involvement. *BMJ Case Rep*. 2018;2018. DOI: [10.1136/bcr-2017-223197](https://doi.org/10.1136/bcr-2017-223197) PMID: [29739760](https://pubmed.ncbi.nlm.nih.gov/29739760/)
19. Smith RL, Schurman DJ, Kajiyama G, Mell M, Gillkerson E. The effect of antibiotics on the destruction of cartilage in experimental infectious arthritis. *J Bone Joint Surg Am*. 1987;69(7):1063-8. DOI: [10.2106/00004623-198769070-00015](https://doi.org/10.2106/00004623-198769070-00015) PMID: [3654698](https://pubmed.ncbi.nlm.nih.gov/3654698/)