

Fire coral persistent cutaneous reaction

M.Paradisi, A. Grassi, G. Conti, F. Passarelli and M.G. Cacciaguerra

S U M M A R Y

A patient who developed a persistent cutaneous reaction to fire coral is presented. Treatment with topical corticosteroids reduced the severity of the lesion but after a follow-up period of 18 months no complete resolution has been showed.

Introduction

Red Sea Coral ("stinging" or "fire coral") is a coelenterate of the Milleporina order and of the Hydrozoan class. It derives its name because it releases nematocysts, toxic organelles responsible for cutaneous lesions, immediately after contact with skin.

All coelenterates are invertebrate organisms composed of a double epithelial layer, which delimits a cavity, the "coelenterium". Their venomous apparatus is composed of the nematocysts, toxin-releasing organelles composed of a capsule and tube, located in large numbers on the tentacles and made-up of collagen-like material. The venom is ejected by the capsula of the nematocyst through the long filamentous tubule into the victim's body (1).

Toxic substances in the venom include quaternary ammonium compounds, proteins, 5-hydroxytryptamine, catecholamines, histamine and histamine liberators.

The cutaneous lesions are induced by the toxic substances liberated and by the foreign-body reaction to the fragments of calcium carbonate, which are in the tentacles that hurt the skin (2). Moreover, the skin scars are accompanied by burn and/or pain.

The severity of the cutaneous reactions depends on the number of the nematocysts discharged, the venom toxicity, the intensity of the stinging and the individual sensibility (3). The general symptoms, which have been reported, include nausea, vomiting, abdominal pain, diarrhea, muscle spasm, respiratory difficulty, tachycardia, hypotension and fever (1,4).

In the majority of cases soon after the contact with the fire coral an erythematous reaction appears, which spontaneously heals in about two months. Sometimes there is a lesional polymorphism. Soon after contact to a fire coral an acute vesiculo-bullous dermatitis follows; then there is a subacute granulomatous dermatitis and,

K E Y W O R D S

**coelenterates,
fire coral,
persistent
cutaneous
reaction**

in the last phase, a chronic lichenoid dermatitis.

Some authors have described a delayed or recurrent granulomatous-like or sarcoid-like cutaneous reaction after a period of up to 12 months from the fire coral contact (5). In some patients the coelenterate's induced cutaneous reaction can be delayed by the use of systemic corticosteroids (6).

Case report

A 41-year-old man with a personal history of gastroduodenitis came to our observation in September 1996 for an eczematous lesion on the right arm.

He referred that during the month of July, while swimming off the Red Sea, he had touched a coral well known as "fire coral" with his right arm (Fig. 1). Immediately an acute erythematous and edematous dermatitis with burning and pruritus developed on the site of contact.

Under antihistaminic therapy he noticed a marked reduction of the edema soon after 3 days, but the eczematous dermatitis persisted even under topical therapy with betamethasone dipropionate.

When the patient presented to us we noticed an erythematous-infiltrated, well-demarcated, 25X5 cm plaque, on the lateral surface of the right arm.

A biopsy of the lesion showed a dense perivascular infiltrate composed by lymphocytes, histiocytes and some eosinophils in the papillary and mid dermis. Superficial blood vessels were slightly dilated (Fig. 2). Histiocytes were mixed together with lymphocytes; there was no granuloma formation. The epidermis showed a slight ortho- and parakeratosis and some neutrophils in the stratum corneum. Immunohistochemical study revealed a T phenotype of all lymphocytes.

Because of the gastroduodenitis the patient received no systemic steroids but only topical application of clobetamethasone dipropionate twice a day, on alternate weeks for two months. The skin lesions healed only partially with persistence of the lesion up to the next four months.

Discussion

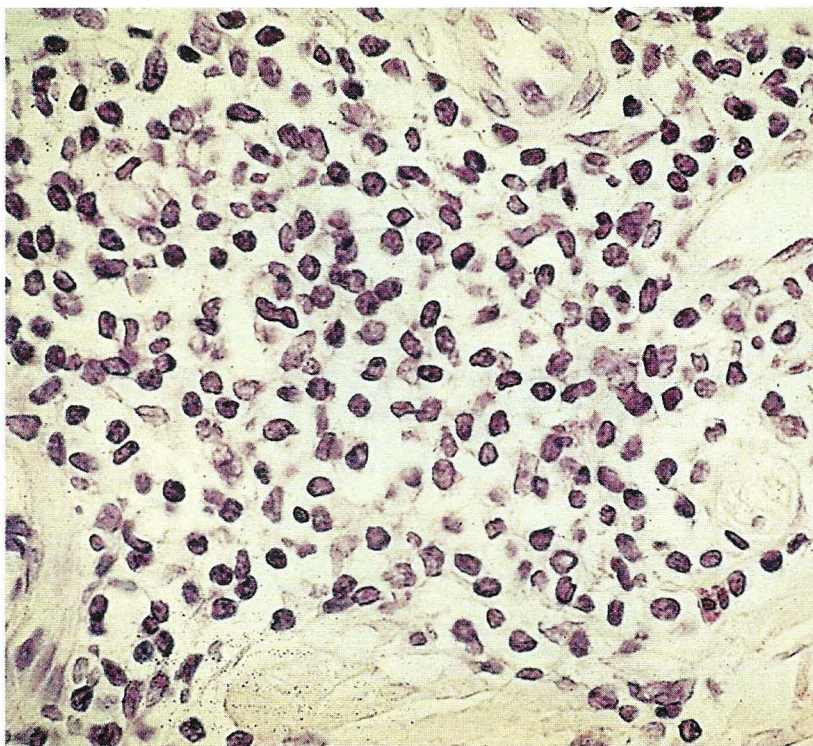
With this report we want to stress the characteristic of the cutaneous lesions induced by the "fire coral" due to the poor attention received in the dermatologic literature.

It has been observed that while the cutaneous lesions which appear soon after the contact with the "fire coral" depend on the venom toxicity, the delayed or recurrent lesions could be caused by a delayed hypersensitivity response to an antigenic compound of the



Figure 1. Fire coral, a coelenterate of the milleporina order. It has a protective calcareous skeleton with powerful stinging cells or nematocysts that release toxins. x 2.

Figure 2. A perivascular infiltrate of lymphocytes, histiocytes and eosinophils in papillary and mid dermis. HE x 40.



coelenterate's nematocyst. Some authors propose a type I hypersensitivity associated with a type IV allergy (7).

An immunohistochemical study reveals that Langerhans cells and T lymphocytes may play a role in the cutaneous eruptions to coelenterates (8).

In particular, in our case the histologic studies showed a chronic unspecific dermatitis without granuloma and almost without epidermal changes.

Contact with this coral can produce three types of cutaneous reactions: an acute urticaria-like, hemorrhagic

or ulcero-necrotic reaction associated or not to anaphylaxis, a leukocytoklastic-like vasculitis and, in many of these latter cases, a delayed response of type IV. Most probably our case can be included into this last group.

All these data have been confirmed by many studies on the serologic response of individuals who had touched the "fire coral". All patients demonstrated a higher titer of circulating specific antibodies against the coelenterate's antigens.

REFERENCES

1. Addy JH. Red Sea coral contact dermatitis. *Int J Dermatol* 1991; 30 (4):271-273.
2. Bianchini G, Lotti T, Campolmi P, Casigliani R, Panconesi E. Coral Ulcer as a Vasculitis. *Int J Dermatol* 1988;27 (7):506-507.
3. Camarasa JG, Nogués Antich E, Serra-Baldrich E. Red Sea coral contact dermatitis. *Contact Dermatitis* 1993;29:285-286.
4. Tong D. Coral dermatitis in the aquarium industry. *Contact Dermatitis* 1995;33:207-208.
5. Reed KM, Bronstein BR, Baden HP. Delayed and persistent cutaneous reactions to coelenterates. *J Am Acad Dermatol* 1984;10:462-466.
6. Burnett JW, Hepper KP, Aurelian L, Calton GJ, Gardepe SE. Recurrent eruptions following unusual solitary coelenterate envenomations. *J Am Acad Dermatol* 1987;17:86-92.
7. O'Donnell BE, Tan CY. Persistent contact dermatitis from jellyfish sting. *Contact Dermatitis* 1993;28:112-113.
8. Piérard GE, Letot B, Piérard-Franchimont C. Histologic study of delayed reactions to coelenterates. *J Am Acad Dermatol* 1990;22:599-601.
9. Hartman KR, Calton GJ, Burnett JW. Use of the radioallergosorbent test for the study of coelenterate toxin-specific immunoglobulin E. *Int Archs Allergy Appl Immunol* 1980;61:389-393.

A U T H O R S ' A D D R E S S E S *Mauro Paradisi, MD, Consultant dermatologist, VII Dept. of Dermatology, I.D.I. IRCSS, via dei Monti di Creta 104, Rome, Italy*
Alessandra Grassi, MD, same address
Giovanni Conti, MD, same address
Maria Giuliana Cacciaguerra, MD, same address
Francesca Passarelli, MD, Histopathology Lab., I.D.I. IRCSS, same address