

Perforacija želodca v neonatalnem obdobju

Neonatal gastric perforation: a case report

Avtor / Author

Ustanova / Institute

Sukič Klavdija¹, Miksič Mirjana¹, Jagrič Tomaž², Potrč Stojan^{2,3}

¹Univerzitetni klinični center Maribor, Klinika za pediatrijo, Maribor, Slovenija, ²Univerzitetni klinični center Maribor, Klinika za kirurgijo, Oddelek za abdominalno in splošno kirurgijo, Maribor, Slovenija, ³Univerza v Mariboru, Medicinska fakulteta, Maribor, Slovenija

¹University Medical Centre Maribor, Clinical department of pediatrics, Maribor, Slovenia,

²University Medical Centre Maribor, Surgical Clinic, Department of Abdominal Surgery,

Maribor, Slovenia, ³University of Maribor, Faculty of Medicine, Maribor, Slovenia

Ključne besede:

perforacija želodca, nedonošenček, pnevmoperitonej, gastrektomija

Key words:

gastric perforation, premature neonate, pneumoperitoneum, gastrectomy

Članek prispel / Received

07.04.2011

Članek sprejet / Accepted

18.05.2011

Naslov za dopisovanje /

Correspondence

Doc. dr. Stojan Potrč, dr. med.

Univerzitetni klinični center

Maribor, Klinika za kirurgijo,

Oddelek za abdominalno in splošno

kirurgijo, Ljubljanska 5,

SI-2000 Maribor, Slovenija

Telefon +386 23211301

E-pošta: stojan.potrc@ukc-mb.si

Izvleček

Namen: Perforacija v neonatalnem obdobju je redko, življenje ogrožujoče klinično stanje. Najpogosteje se pojavi pri kritično bolnih novorojenčkih, ki so zdravljeni v neonatalni intenzivni enoti. Poznanih je več možnih vzrokov, vendar ostajata etiologija in patogeneza v mnogih primerih nepojasnjena. Nedonošenost in nizka porodna teža sta znana dejavnika tveganja.

Poročilo o primeru: Predstavljamo primer fantka, gestacijske starosti 29. tednov, ki je bil rojen z urgentnim carskim rezom zaradi abrupcije placente. 4. dan po rojstvu smo opazili distenzijo abdomna ter hitro napredujoče šokovno stanje. Rentgenogram abdomna je potrdil pnevmoperitonej. Ob urgentni kirurški eksploraciji je bila ugotovljena perforacija želodca, ki je bil zašita po eksciziji okolnega ishemičnega tkiva.

Zaključek: Perforacija želodca pri novorojenčku je kirurška urgenca z visoko

Abstract

Purpose: Neonatal gastric perforation is a rare life-threatening clinical condition. It is usually handled in a neonatal intensive care unit setting. Many theories have been proposed to explain the etiology and pathogenesis of gastric perforation in the neonatal period, but in many cases they remain unknown. Prematurity and low birth weight are known as risk factors.

Case report: We report a 4-day-old male infant that was delivered by emergency Cesarean section because of placental abruption at 29-weeks gestational age. On the 4th day, the baby developed rapid abdominal distension with rapid progression to shock. Abdominal radiography showed free intra-peritoneal air. An emergency laparotomy revealed a perforation in the smaller curvature of the stomach that was sutured after excision of the surrounding ischemic stomach wall.

smrtnostjo. Za izboljšanje prognoze sta pomembna zgodnja prepoznavna in čimprejšnji kirurški poseg ob agresivnem podpornem zdravljenju.

Conclusion: Gastric perforation in a newborn infant represents an immediate surgical emergency with high mortality. Early diagnosis and early intervention may improve the prognosis associated with vigorous supportive measures.

INTRODUCTION

Gastric perforation in the newborn is a rare clinical condition of uncertain etiology with high mortality, especially in premature infants. It usually occurs in a neonatal intensive care unit setting. The first case was reported in 1825 by Siebold. Since then, over 300 cases have been reported in the literature. Legar et al. reported the first successful repair of gastric perforation in a newborn in 1950 (1, 2).

The etiology and pathogenesis of gastric perforation in the neonatal period are still unknown, although many variables have been proposed, including asphyxia, respiratory distress at birth, nasal ventilation, gastric trauma and postnatal corticosteroid administration (1–5). Premature birth and low birth weight are known risk factors. The first clinical sign in the majority of cases is abdominal distension associated with rapid development of respiratory distress and shock. Early identification and treatment of spontaneous gastric perforation significantly reduces mortality and morbidity. Gastric perforation in a newborn infant represents an immediate surgical emergency.

CASE REPORT

A 1.2 kg, 29-week gestational age male neonate that was born after in vitro fertilization to a 29-year-old primigravida was delivered by emergency Cesarean section because of placental abruption in placenta previa. The mother received antibiotics and steroids

during pregnancy for fetal lung maturation. At birth, the infant was depressed, pale, hypotonic, apneic and bradycardic. The infant received positive pressure ventilation with a bag mask and was afterwards intubated and received assisted ventilation. Apgar scores were 4 at 1 min, 6 at 5 min and 7 at 10 min. He was transferred to a neonatal intensive care unit where he received surfactant for the developing respiratory distress syndrome. His course was complicated by hypotension that required fluid resuscitation and vasoactive drugs.

On the second day, we recorded clinical sepsis confirmed by laboratory results. After treatment with broader spectrum antibiotics, the baby became clinically stabilized. Blood culture was negative.

On the fourth day, the baby developed rapid abdominal distension and bilious-stained gastric residuals. Bowel sounds were absent. He was tachycardic and hypotensive. An abdominal supine radiograph study revealed free intra-peritoneal air (Fig. 1), but there was no evidence of pneumatosis intestinalis or portal venous gas. Immediately, all feeds were discontinued. The patient received supportive care including fluid resuscitation and inotropic medications and nasogastric suction for decompression of the abdomen. An emergency laparotomy was performed. With peritoneal incision, a release of air was noted. Upon exploration, a perforation measuring 5 mm was found on

the smaller curvature of the stomach. The surrounding stomach wall was ischemic (Fig. 2). The ischemic region comprised the anterior wall of the corpus and cardia of the stomach. The necrotic tissue was excised (“almost proximal resection”) and the stomach remnant was closed with interrupted 5.0 resorbable sutures in the transverse direction. The nasogastric tube was placed deep in the duodenum for the purpose of decompression (first few days) and feeding (later). No other visible injuries or abnormalities were found within the abdomen. Pathological examination of the necrotic tissue showed mucosal necrosis and transmural hemorrhage.

In the immediate postoperative course, the baby needed vasoactive support and remained in critical condition for the next 3 days. Enteral feedings were cautiously introduced on the 6th postoperative day via the nasoduodenal tube and, at that time, his clinical condition was improving.

On the 15th postoperative day, the baby became lethargic and was refusing feedings. An abdominal disten-

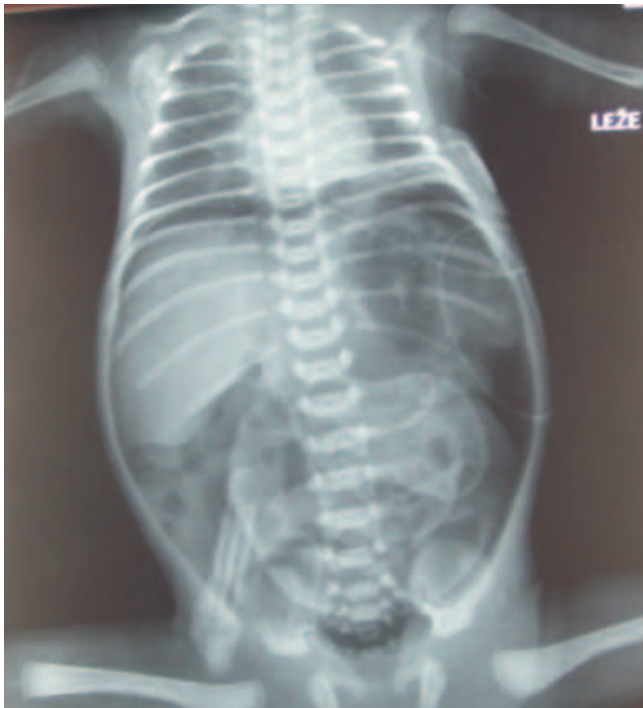

Figure 1. A plain abdominal X-ray showing free air in the peritoneal cavity.

sion was noted. Ultrasound examination discovered free fluid. Because of the development of acute abdomen symptoms, a laparotomy was performed. It showed a partial anastomotic dechiscence (5 mm) on the anterior wall, which was repaired. Two abdominal drains were inserted and removed on the 8th day after reoperation. The patient remained on total parenteral nutrition until postoperative day 6. The subsequent hospital course was uneventful and he was discharged and sent home tolerating oral feedings.

DISCUSSION

With the increasingly effective management of premature infants, we have learned that abdominal complaints in these infants do not represent a homogeneous group of illnesses.

Neonatal gastric perforations predominately affect premature infants but it can also occur in healthy term infants. Dickens et al. reported the incidence of neonatal gastric perforation as 0,34 per 1000 live births with males being affected four times more than females (3). The usual age at presentation is between the 2nd and 7th day of life (1-3).

The mortality rate is higher in premature infants (50% - 62%) than full-term infants (5% - 26%) and in low-birth weight neonates compared to those with

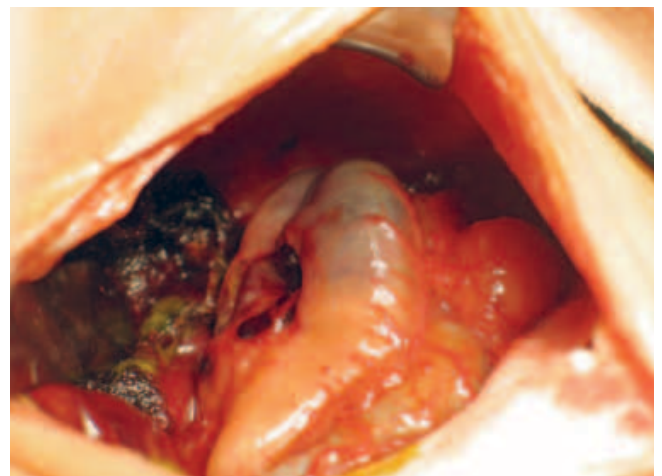


Figure 2. Ischemia of the proximal part of the stomach and perforation at the lesser curvature

a birth weight higher than 2500 g (55% vs 28%, respectively; 1,4).

Despite an increasing number of cases, there remains uncertainty in the literature on the etiology of gastric perforation occurring in the neonatal period. The etiology may be difficult to determine because these infants are usually sick and in the setting of a neonatal intensive care unit. Although there are some reports of gastric perforation occurring in healthy full-term babies, most historical reports have described gastric perforation in the neonatal population as spontaneous, without any associated gastrointestinal conditions and separate from necrotizing enterocolitis. Originally, it was thought to be caused by a congenital absence of the gastric musculature (1). It occurs in the greater curvature in most cases, but other locations have also been described in the literature (2).

Recently, several factors, including prematurity and concomitant gastrointestinal lesions, have been implicated as contributing factors (1–4). Also, a number of other theories have been proposed to explain these events, including hypoxic stress leading to gastric ischemia by selective shunting of blood away from the splanchnic vascular bed, sepsis, and mechanical rupture of the stomach secondary to increased gastric pressure due to lack of co-ordination or immaturity of the vomiting mechanism in infants. The use of positive pressure ventilation or nasal continuous positive airway pressure (nCPAP) without decompression of the stomach are other possible causes (1,5). In the literature, we find few reports of cases of neonates who developed gastric perforation after being treated with steroid therapy for bronchopulmonary dysplasia (6).

Because of known gastric hyperacidity in the first few days of life and gastric stress ulcers that have been reported in a variety of critically ill infants, it has been proposed that perforation can result from the transmural necrosis of such lesions (7).

Injuries from feeding tube placement are also reported. Perforation usually occurs along the greater curva-

ture and appears as a puncture wound or a short laceration. This type of injury usually occurs in the second week, presumably because of the time required to erode the intestinal wall (5, 8).

Signs and symptoms of gastric perforation include sudden onset of abdominal distention capable of compromising ventilatory support, increased gastric residue, tenderness, lethargy and apnea. In some cases, it is accompanied by bilious vomiting and features of sepsis, and it can progress into shock and respiratory failure (2,4,7). Differential diagnoses include necrotizing enterocolitis, septicemia, intestinal obstruction, spontaneous pneumoperitoneum without gastrointestinal perforation and others (9, 10).

Clinical suspicion is supported by radiological signs. Radiographic confirmation of a massive pneumoperitoneum in the absence of a gastric gas bubble, bowel air-fluid levels or pneumatosis intestinalis are suggestive of gastric perforation and contrast studies to confirm the diagnosis are not indicated. Gastric perforation is one of the most common causes of pneumoperitoneum during the first week of life (5).

The only treatment for gastric rupture is urgent surgical repair. Vigorous supportive measures, intravenous infusions, antibiotics, nasogastric suction and vasoactive support are mandatory. In the literature, few authors recommend needle decompression of the abdomen with a large IV catheter for improving respiratory and circulatory functions during the evaluation and resuscitation of the infant prior to definitive surgical intervention. Prompt surgical intervention with debridement of necrotic tissue and primary repair of the perforation is the recommended management (11).

Some cases with extensive necrosis of the stomach wall may require partial gastrectomy. Gastrostomy is not needed in all cases and should be individually assessed. A thorough examination of the stomach for a second perforation and the entire gastrointestinal tract for other unsuspected perforations or abnormalities should be carried out (4, 11, 12).

In our case, there were many risk factors, such as prematurity with gestational age at 29 weeks, hypotension and perinatal stress. During severe hypoxic stress, there is selective shunting of blood away from the splanchnic vascular bed. Regional hypoperfusion and transient gastric ischemia adding to hyperacidity could lead to transmural necrosis and perforation. During surgery, no other injuries or abnormalities were detected. As a resection of a large proportion of the stomach was necessary, the child must be carefully monitored regarding his growth and development. Suggestions for a good outcome are early diagnosis and supportive measures with modern hemodynamic monitoring to correct metabolic and electrolyte derangements before they become irreversible. Prompt surgical exploration is required (4).

CONCLUSION

In summary, we have described a case of isolated neonatal gastric perforation and ischemia, which is a rare entity with very high mortality and complication rates.

Recent reviews have suggested that the early diagnosis of neonatal gastric perforation can affect the outcome favorably. The initial management is directed towards stabilization of the patient. The proper therapeutic regimen includes fluid and electrolyte replacement, antibiotics and prompt surgical intervention.

REFERENCES

1. Lin CM, Lee HC, Kao HA, Hung HY, Hsu CH, Yeung CY, et al. Neonatal gastric perforation: report of 15 cases and review of the literature. *Pediatr Neonatol* 2008; 49: 65–70.
2. Duran R, Inan M, Vatansever U, Aladag N, Acunaş B. Etiology of neonatal gastric perforations: review of 10 years' experience. *Pediatr Int* 2007; 49: 626–30.
3. Dickens SV, Guy L, Francois IL, Arie LB. Neonatal gastrointestinal perforation. *J Pediatr Surg* 1992; 27: 1340–2.
4. Leone RJ, Krasna IH. Spontaneous neonatal gastric perforation: Is it really spontaneous? *J Pediatr Surg* 2000; 35: 1066–9.
5. Chouteau W, Green DW. Neonatal gastric perforation. *J Perinatol* 2003; 23: 345–7.
6. Ng PC, Brownlee KG, Dear PR. Gastroduodenal perforation in preterm babies treated with dexamethasone for bronchopulmonary dysplasia. *Arch Dis Child* 1991; 66: 1164–6.
7. Avery GB, Randolph JG, Weaver T. Gastric acidity in the first day of life. *Pediatrics* 1966; 37: 1005–7.
8. Pulzer F, Bennek J, Robel-Tillig E, Knüpfer M, Vogtmann C. Gastric perforation in a newborn. *Lancet* 2004; 363: 703.
9. Gathwala G, Rattan KN, Abrol P, Sodhi D. Spontaneous gastric perforation in a neonate. *Indian Pediatr* 1994; 31: 1013–5.
10. Grosfeld JL, Molinari F, Chaet M, Engum SA, West KW, Rescorla FJ, et al. Gastrointestinal perforation and peritonitis in infants and children: experience with 179 cases over ten years. *Surgery* 1996; 120: 650–5.
11. Peterson CM, Williams SJ. Spontaneous gastric perforation in the premature newborn. Report of survival. *J Natl Med Assoc* 1963; 55: 401–3.
12. Durham MM, Ricketts RR. Neonatal gastric perforation and necrosis with Hunt-Lawrence pouch reconstruction. *J Pediatr Surg* 1999; 34: 649–51.