

Expression of p53 protein in psoriasis

W. Baran, J. C. Szepietowski and G. Szybejko-Machaj

ABSTRACT

Introduction: Psoriasis is characterized by hyperproliferation and abnormal differentiation of keratinocytes, by the presence of inflammatory cell infiltrate in both the dermis and the epidermis and by alterations of capillaries. p53 protein is an important transcription factor which plays a central role in cell cycle regulation mechanisms and cell proliferation control.

Objectives: This study was performed to identify the expression and localization of p53 protein in lesional and non-lesional skin samples taken from psoriatic patients in comparison with healthy controls.

Material and methods: Sections of psoriatic lesional and non-lesional skin (n=18) were examined. A control group (n=10) of healthy volunteers with no personal and family history of psoriasis was also examined. The expression of p53 was demonstrated using the avidin – biotin complex immunoperoxidase method and the monoclonal antibody DO7. The count and localization of cells with stained nuclei was evaluated using a light microscope in 10 fields for every skin biopsy.

Results: In lesional psoriatic skin the count of p53 positive cells was significantly higher than in the skin samples taken from healthy individuals ($p<0.01$) and non-lesional skin taken from psoriatic patients ($p=0.02$). No significant difference between non-lesional psoriatic skin and normal skin was observed ($p=0.1$). A strong positive correlation between mean count and mean per cent of p53 positive cells was found ($p<0.0001$). P53 positive cells were located most commonly in the basal layer of the epidermis of both healthy skin and non-lesional psoriatic skin. In lesional psoriatic skin p53 positive cells were present in all layers of the epidermis.

Conclusion: P53 protein appears to be an important factor in the pathogenesis of psoriasis.

K E Y W O R D S

p53 protein,
psoriasis,
histochemistry

Introduction

p53 is a phosphoprotein, which shows transcription factor-like properties (1). In 1992 Lane (2) proposed a hypothesis that p53 protein acts as a “guardian” of the genome - its activation protects the organism from

Table 1. Average count and percentage (mean±standard deviation) of p53-positive cells.

	Mean count ± standard deviation	Mean percentage ± standard deviation
Psoriasis (lesional skin)	21,8 ± 21,2	9,5% ± 8,62
Psoriasis (non-lesional skin)	11,9 ± 16,9	8,71% ±10,36
Normal skin	4 ± 6,3	2,44% ±3,55

tumorigenesis. DNA damaging agents induce the activity of this protein, which leads to cell cycle arrest in the G1 or G2 phase, and in the case of ineffective DNA repair apoptosis is initiated (3).

A mutation in the p53 gene has been found in most human tumor types. p53 protein is constitutively expressed in almost all cells, but due to the short span of its half-life it is extremely difficult to detect a "wild-type" p53 in standard immunohistochemistry. The activated or mutated form accumulates in cells and immunohistochemical detection is possible (4).

Psoriasis is a benign skin disease characterized by hyperproliferation, abnormal differentiation of keratinocytes, by the presence of inflammatory cell infiltrate in both the dermis and the epidermis and by alterations to the capillaries (5). Many genes, particularly oncogenes and tumor suppressor genes, could be involved in the dysregulation of the cell-cycle (increased cell division), which is probably important in the development of psoriatic lesions (6,7).

Although p53 immunoreactivity has also been found in several inflammatory skin diseases, such as psoriasis, lichen planus, chronic dermatitis and lupus erythematosus (8), the results are frequently controversial. Therefore, the present study was undertaken to evaluate the expression of p53 in psoriatic skin.

Material and methods

Skin samples

Skin biopsies (scalpel biopsy – 10 mm length) were collected under local anesthesia (0,5% lidocaine) from eighteen psoriatic patients (9 females and 9 males) from lesional skin. None of the psoriatic patients (n=18) had received any topical treatment for at least two weeks prior to the study. Only emollients were allowed. None of the patients had been exposed to photochemotherapy or any other systemic antipsoriatic treatment for at least one month. Additionally, in seven of the 18 psoriatic patients (1 female and 6 males) biopsies from uninvolved skin from the back were also obtained.

Skin samples were also taken from 10 healthy volunteers (5 females and 5 males) with no personal or family history of psoriasis (control group). The specimens were fixed in 10% buffered formalin and embed-

ded in paraffin blocks. Written informed consent was obtained from all participants. The study was approved by the Commission of Bioethics at Wroclaw Medical University (KB 245/2004).

Immunohistochemical staining

The expression of p53 protein was demonstrated using the avidin – biotin complex immunoperoxidase method and the monoclonal antibody DO7 (Monoclonal Mouse Anti-Human p53 Protein, Clone DO7, DakoCytomation, Glostrup, Denmark, code.nr M7001,) that recognise both wild- and mutant-type p53 proteins.

Sections (5µm) were cut from the specimens and placed on poly-l-lysine (Sigma Chemicals, St.Louis, USA) coated glass slides. Sections were dewaxed through xylene and rehydrated in graded alcohol. Then specimens were treated with 3% hydrogen peroxide in methanol for 10 minutes to block endogenous peroxidase. For p53 analysis the sections were incubated with the monoclonal antibody DO7 for 10 minutes at room temperature. Excess antibodies were then washed off with Tris-buffered saline (TBS, DakoCytomation, Glostrup, Denmark, code.nr S3001) and incubated with a secondary biotinylated anti-rabbit antibody (LSAB2™ KIT, DakoCytomation, Glostrup, Denmark, code.nr K0675,) for 15 minutes. After being washed in TBS, the sections were incubated with the avidin-biotin complex for 15 minutes and diaminobenzidine (DAB, DakoCytomation, Glostrup, Denmark, code .nr K 3466) was used as the chromogen to yield a brown color. Then the slides were lightly counterstained with Mayer's haematoxylin, rinsed with water and covered with cover glass and Canada balsam.

A sample of esophageal carcinoma (carcinoma planoepitheliale akeratodes) that was strongly positive for p53 was used as a positive control. Negative controls were provided by performing the standard procedure, and leaving out incubation with the primary antibody.

Evaluation and statistical analysis

The positive keratinocyte nuclei count (10 fields for each slide, x400) and the percentage of keratinocytes with stained nuclei (5 fields for each slide, 1 field=100 cells) was estimated using a Nikon Eclipse E600 light microscope. Only cells with nuclear staining

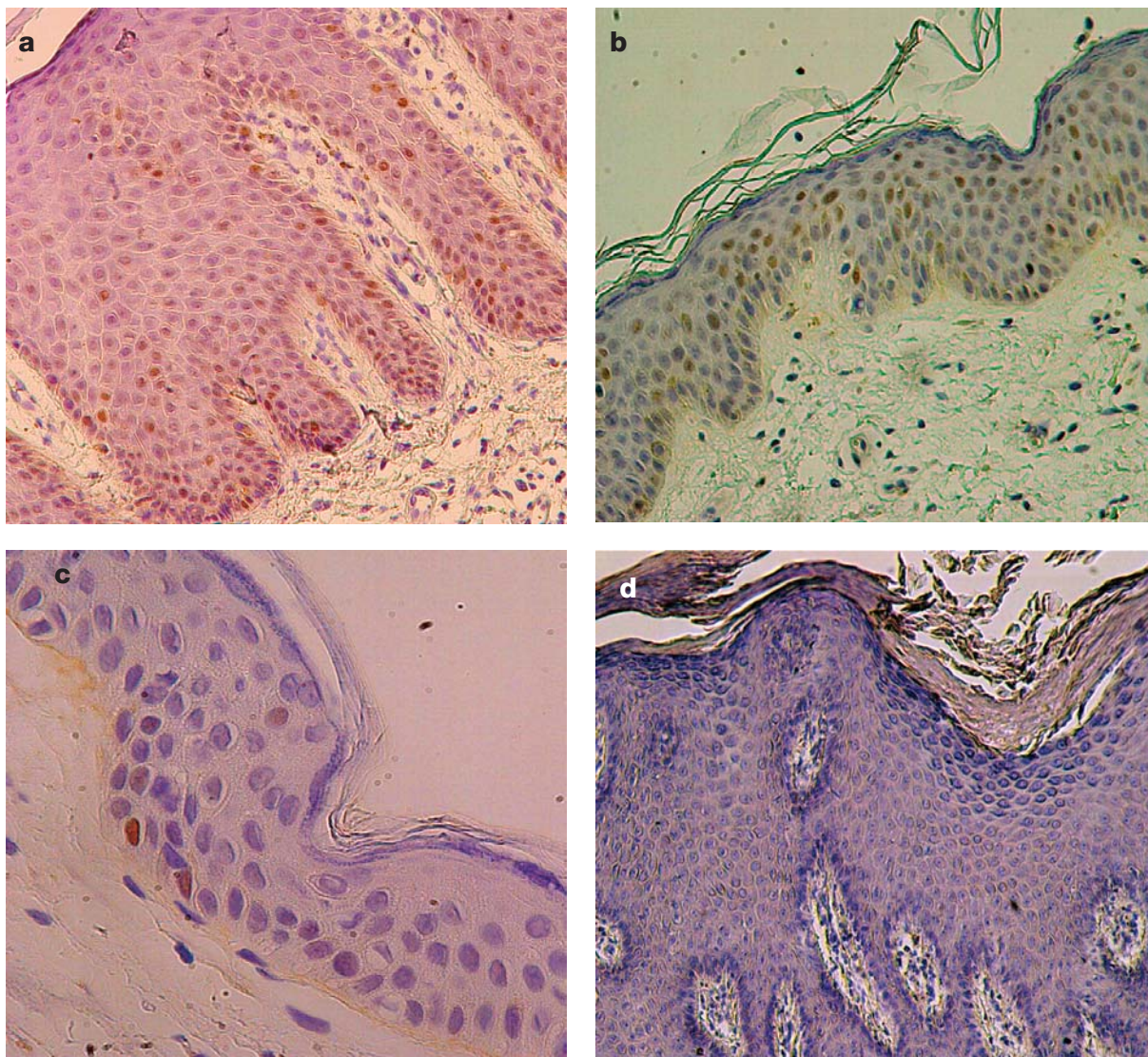


Figure 1. p53 immunoreactivity: A – lesional psoriatic skin (x200), B - non-lesional skin taken from psoriatic patient (x200), C – healthy control (x400), D – negative control, lesional skin (x100).

were taken into consideration. In addition, the localization of cells with stained nuclei was evaluated. Two groups of specimens were distinguished – one with p53 positive cells detected only in the basal layer of the epidermis, and a second group with stained cells in the basal and suprabasal layers of the epidermis.

Statistical analysis of the results was done using the U-Mann-Whitney test, Wilcoxon test, Chi-square test, Fisher test and Spearman rank test. Two-tailed p values of less than 0,05 were considered statistically significant.

Results

Immunoreactivity for p53 was seen only in the nuclei of the epidermal cells, and no stained cells were

observed in the dermis. p53 reactivity was observed almost in all samples (Figure 1) and only two normal skin specimens were negative. p53-positive cells showed various staining intensity, but negative ones were easily distinguishable from them.

The results for p53 positive cell-count and percentage in lesional and non-lesional skin taken from psoriatic patients, as well as those from healthy skin are shown in Table 1.

The mean count of p53 positive cells in lesional skin was higher (21.8 ± 21.2) than in non-lesional skin (11.9 ± 16.9) or in the control group (4.0 ± 6.3). The differences between lesional and non-lesional skin ($p=0.02$) as well as between lesional and healthy skin ($p<0.01$) were statistically significant. No significant difference between non-lesional and normal skin was observed ($p=0.1$).

Table 2. Localization of p53 positive cells, count and percentage of specimens.

	p53 positive cells only in the basal layer	p53 positive cells in the basal and suprabasal layers
Psoriasis (lesional skin)	4 (22,2%)	14 (77,8%)
Psoriasis (non-lesional skin)	4 (57,1%)	3 (42,9%)
Normal skin	6 (75%)	2 (25%)

The average percentage of the p53 positive keratinocytes was higher in lesional skin ($9.5\% \pm 8.62$) compared to non-lesional skin ($8.71\% \pm 10.36$) and biopsies taken from healthy volunteers ($2.44\% \pm 3.55$). The difference between lesional and normal skin was statistically significant ($p < 0.01$), as was that between lesional and non-lesional skin ($p = 0.04$). No significant difference between non-lesional and normal skin was found ($p = 0.06$).

A strong positive correlation between the mean count and the percentage of p53 immunoreactive cells was observed ($R = 0.95$; $p < 0.0001$) (Figure 2). The age of the patients, the type of psoriasis (early or late onset of disease) and the duration of the illness related poorly to the number and percentage of p53 positive cells (data not shown).

p53-positive keratinocytes in normal skin samples were located predominantly in the basal layer of the epidermis, but in lesional skin p53-positive nuclei could be seen also in suprabasal layers of the epidermis and this difference was statistically significant ($p = 0.02$) (Table 2).

Discussion

Using sensitive immunohistochemical assay we found p53 protein expression in lesional and non-lesional psoriatic skin, and in skin samples taken from healthy individuals. The mean count and percentage of cells with stained nuclei was significantly higher in the specimens from lesional psoriatic skin than in other samples. p53 positive cells were predominantly located in the basal layer in normal skin and in the basal and suprabasal layers in psoriatic lesional skin.

The first publication to discuss p53 and psoriasis appeared in 1989, when Tadani et al. (9) reported p53 nuclear expression in psoriatic skin. In contrast to these findings, a few years later Moles et al (10) used similar antibodies but did not find p53 positive cells either in lesional or non-lesional skin biopsies taken from psoriatic patients. Later studies performed by Helander et al. (11), Soini et al. (1) and Hannuksela-Svahn et al. (12) confirmed the presence of p53 positive keratinocytes in psoriatic epidermis. In the latest study Batinac et al.

(8) examined p53 expression in lesional psoriatic skin, normal skin and skin samples from neoplastic diseases: basal cell carcinomas and squamous cell carcinomas. In a similar way to our study, nuclear staining was detected in normal and psoriatic skin samples with the same distribution: p53 immunoreactivity was demonstrated in the epidermis of psoriatic skin in the basal and suprabasal layers and only in the basal layer in normal skin. The difference in p53 expression was, however, not significant. In carcinomas (basal cell carcinoma, squamous cell carcinoma) p53 expression was significantly stronger. An investigation of the expression of p53 in non-tumorigenic, pre-tumorigenic and tumorigenic hyperproliferative skin lesions was performed by Hussein et al. (13). They described the presence of p53 positive cells in psoriatic and normal skin, with a statistically stronger expression in lesional skin.

It is likely that increased expression of p53 in psoriatic skin is a physiological reaction indicating the attempt to counteract the proliferation and to repair DNA errors, and is most often expressed as an increased number of mitoses (12). The D07 monoclonal antibody detects both the wild-type and the mutated form of the p53 protein and it is possible that other factors, not only mutation, may account for the accumulation of this protein. It is also known that some viral proteins such as the large T anti-

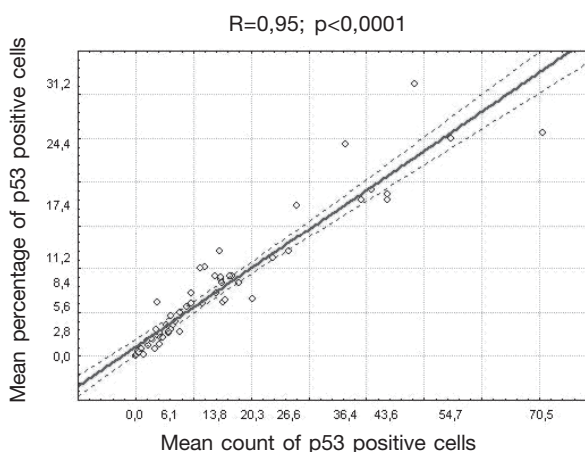


Figure 2. Correlation between mean count and mean percentage of p53 positive cells.

gen of the SV40 virus and non-viral proteins (mdm2 protein) may bind p53 and alter its half-life (1,14). That could explain the presence of p53 positive cells in viral skin lesions such as common warts, condylomata acuminata and epidermodysplasia verruciformis (13).

p53 is an important marker of active cycling cells in psoriasis. A large body of evidence indicates that the cell cycle time in psoriasis is normal and only increased recruitment of epidermal cells is responsible for the development of psoriatic lesions (5). New theories have been published (15,16) concerning the response of the

keratinocytes to DNA damaging factors, which seems to be different in this instance to that in other cells of the human body. Unique mechanisms are essential for the keratinocytes to preserve cutaneous homeostasis and maintain the structural integrity of the skin as a barrier between the organism and the environment. Our results may suggest that the cell cycle is disturbed in psoriatic epidermis but further studies are needed to determine definitively the molecular basis of cell cycle regulation in epidermal cells, and to continue to broaden our knowledge of the pathogenesis of psoriasis.

REFERENCES

1. Soini Y, Kamel D, Paakko P et al. Aberrant accumulation of p53 associates with Ki67 and mitotic count in benign skin lesions. *Br J Dermatol* 1994; 131: 514–20.
2. Lane DP. Cancer. p53, guardian of the genome. *Nature* 1992; 358: 15–6.
3. Batinac T, Gruber F, Lipozencic J et al. Protein p53 - structure, function, and possible therapeutic implications. *Acta Dermatovenerol Croat* 2003; 11: 225–30.
4. Hainaut P, Hollstein M. p53 and human cancer: the first ten thousand mutations. *Adv Cancer Res* 2000; 77: 81–173.
5. Kerkhof P. *Textbook of psoriasis*. Blackwell Publishing Ltd., Oxford: 2003; pp. 83–109.
6. Bishop JM. Molecular themes in oncogenesis. *Cell* 1991; 64: 235–48.
7. Marshall CJ. Tumor suppressor genes. *Cell* 1991; 64: 313–26.
8. Batinac T, Zamolo G, Jonjić N, et al. p53 protein expression and cell proliferation in non-neoplastic and neoplastic proliferative skin diseases. *Tumori* 2004; 90:120–7.
9. Tadini G, Cerri A, Crosti L, et al. P53 and oncogene expression in psoriasis. *Acta Derm Venereol (Stockh)* 1989; 146: 33–5.
10. Moles JP, Theillet C, Basset-Seguin N, et al. Mutation of the tumor suppressor gene TP53 is not detected in psoriatic skin. *J Invest Dermatol* 1993; 101:100–2.
11. Helander SD, Peters MS, Pittelkow MR, et al. Expression of p53 protein in benign and malignant epidermal pathologic conditions. *J Am Acad Dermatol* 1993; 29: 741–8.
12. Hannuksela-Svahn A, Paakko P, Autio P, et al. Expression of p53 protein before and after PUVA treatment in psoriasis. *Acta Derm Venereol (Stockh)* 1999; 79: 195–9.
13. Hussein MR, Al-Badaiwy ZH, Guirguis MN et al. Analysis of p53 and bcl-2 protein expression in the non-tumorigenic, pretumorigenic, and tumorigenic keratinocytic hyperproliferative lesions. *J Cutan Pathol* 2004; 31: 643–51.
14. Montenarh M : Biochemical properties of the growth suppressor- oncoprotein p53. *Oncogene* 1992; 7: 1673–80.
15. Qin JZ, Chaturvedi V, Denning MF et al.: Regulation of apoptosis by p53 in UV-irradiated human epidermis, psoriatic plaques and senescent keratinocytes. *Oncogene* 2002; 21: 2991–3002.
16. Nickoloff BJ: Creation of psoriatic plaques: the ultimate tumor suppressor pathway. A new model for an ancient T-cell-mediated skin disease. *Viewpoint. J Cutan Pathol* 2001; 28: 57–64.

AUTHORS' ADDRESSES

Wojciech Baran MD, PhD, Department of Dermatology, Venereology and Allergology, Wrocław Medical University, ul. Chalubinskiego 1, 50-368, Wrocław, Poland
Jacek C. Szepietowski MD, PhD, Professor, Vice Head, corresponding author, same address, e-mail: jszepiet@derm.am.wroc.pl
Grazyna Szybejko-Machaj MD, PhD, same address