

Standardized immunohistochemistry of estrogen receptors in human breast carcinoma in routinely processed tissue

Golouh R and Kljun A

Institute of Oncology, Department of Pathology, Ljubljana

The aim of this study was to determine the optimal method for estrogen receptor (ER) staining on routinely processed breast tumors. We tested different commercially available primary antibodies, different methods for tissue digestion and several detection systems on formalin-fixed, paraffin embedded tissue under conditions of our laboratory. All antibodies to ER tested (H222, ER1D5, D75, NCL-ER-P31, and 1D5), gave positive results at least under some conditions of retrieval and/or heavy salt enhancement. Proteolytic enzyme pretreatment, microwave irradiation and heavy metal ions had various influence on intensity of final color products depending mostly on primary antibody tested. We have found that immunohistochemical assessment of estrogen receptor status using Dako 1D5 primary antibody, microwave heat induced epitope retrieval, and Streptavidin-peroxidase protocol, performed by an automatic immunostainer has many advantages over other antibodies and methods tested.

Key words: breast neoplasms; receptors, estrogen; immunohistochemistry

Introduction

The value of the estrogen receptor (ER) assay to predict breast cancer response to therapy and overall survival has been established by an extensive literature on the subject over last few decades (1,2,3). The widely used biochemical assay is based on the ligand binding, dextran-coated charcoal (DCC) using tissue homogenates. This method is generally regarded as the standard against which new methods are measured (4,5). Unfortunately, biochemical methods

require substantial amount of fresh tissue, that has to be collected immediately after surgery and transported on ice. As the method is destructive of the tissue, the assessment of actual tumor content of the specimen is not possible (6). Furthermore, biochemical assay in very small tumors and retrospective analyses of fixed material are impossible.

The first step to solve these problems was the development of monoclonal antibodies to ER that has allowed the use of immunohistochemical techniques to visualize the receptors in tissue sections. It should now be possible to perform the study on scant material that otherwise would be insufficient for biochemical assay and to evaluate the degree of intratumoral heterogeneity.

Correspondence to: Prof Golouh Rastko, M. D., Ph. D. The Institute of Oncology, Zaloška c. 2, 61000 Ljubljana, Slovenia.

UDC: 618.19-006.6-07

Among the well defined antibodies, the rat monoclonal antibody H222 raised by Greene and coworkers and commercially available as a kit by Abbott Laboratories was recommended initially for use on frozen sections (7). As frozen section has its drawbacks, in second step, efforts have subsequently been made to make this antibody effective on paraffin-embedded tissue (8,9). So far, the Abbott H222 antibody is well characterized and immunohistochemical results have been found repeatedly to correlate well with biochemical methods of assessing ER status. However, this antibody requires an overnight incubation and in different laboratories the results of staining were not reproducible. With the advent of new antibodies to ER, different techniques used, and diverse cut-off points established for evaluating the results, standardization of ER immunostaining protocol has been strongly advocated (4).

The aim of this study was to test different approaches to ER immunostaining on routinely processed breast tumors and to determine the optimal method under conditions of our laboratory.

Material and methods

Breast tumor tissue

As routine fixation and processing are by definition heterogeneous and may have unpredictable effects on the immunohistochemical results (4) we tried to avoid this variability. In our institution, all breast specimens were received fresh on the ice immediately after surgical removal, and examined by surgical pathologist.

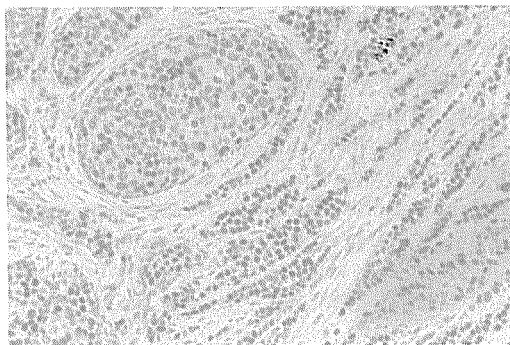


Figure 1. Immunostaining for estrogen receptors with Dako 1D5. Note the intense nuclear staining in cells of both, infiltrating and intraductal component of ductal carcinoma and the absence of cytoplasmic staining. Microwave pretreatment, automatic stainer.

Routinely, and for the purpose of this study, a portion of tumor tissue was snap frozen in liquid nitrogen and submitted for DCC assay. At the same time, an additional piece of tumor was fixed for period not exceeding 24 hours, using 10% neutral-buffered formalin at room temperature. In the tissue processor (Hypercenter, Shandon), the material underwent dehydration, clearing and paraffin infiltration. The tissue was then embedded in blocks, and 3-micron sections were cut and mounted on Silane (Sigma) coated slides.

ER staining procedure

Monoclonal antibodies. Five different monoclonal antibodies to ER were tested (Table 1).

Preparation of paraffin-embedded sections. The slides were dried in a 56°C oven overnight; then they were deparaffinized and rehydrated in graded alcohols. After rehydration, endogenous

Table 1. ER primary antibodies tested

Clone	Source	Dilution	Incubation time	Temperature
H222	Abbot	Prediluted	Overnight	RT*
ER1D5	Immunotech	1 : 10	Overnight	4°C
D75	Courtesy of Dr GL Greene	1 : 100	Overnight	4°C
NCL-ER-P31	Novocastra	1 : 20	Overnight	RT
1D5	Dako	1 : 100	Overnight	4°C

RT – room temperature

* reincubation at 37°C, 2 hours

peroxidases were blocked by immersing the slides in 1% H₂O₂ in methanol for 15 minutes and washed well with phosphate buffer solution (PBS) before enzymatic, and in distilled water before microwave pretreatment.

Antigen retrieval The most controversial step in ER immunohistochemistry of paraffin-embedded tissue is, no doubt, the pretreatment of the sections. It is well known that many epitopes are sensitive to formalin fixation, often proportionally related to the duration of fixation, thus potentially causing unsuspected false-negative immunostains (10).

For the purpose of this study we applied two different methods of antigen retrieval. The first one, proteolytic enzyme treatment of formalin-fixed tissue sections was found to enhance immunoreactivity (11,12). In this study a series of enzymes was tested for enzymatic digestion (Tab 2).

As enzymatic digestion is effective with only limited fraction of currently used diagnostic antibodies, the second method using microwave radiation of sections has been stated to improve immunostaining in a broader group of antigens (13). To this end, we have used a microwave

oven (M752, Miele, 850 W). Slides in the citrate buffer, pH 6.0, were exposed to heating at power setting of 750 W in three intervals of 5 minutes.

Completion of staining procedure. The remainder of the staining procedure followed our routine procedure for different detection systems or a method supplied by manufacturer (Abbott) for ERICA kit.

In this study, three immunohistochemical detection systems were tested in combination with different antibodies (Tab 3).

As heavy metal ions have long been proposed as a means to increase intensity of final color products (12,14), we also tested the influence of copper, nickel, cobalt, and osmium salts on ER staining intensity.

In the first part of the study, all procedures tested were performed manually. Ideally, a single method should be adopted and standardized for routine day-to-day staining within a laboratory. The chosen method should then be performed in identical fashion on every run. This is best achieved by automation, which offers levels of quality and consistency far better than that achievable by manual methods (15).

Table 2. Tissue enzymatic digestions tested

Enzyme	Source	Dilution	Time, min	Temperature
Protease XIV	Sigma	0.1 %	30	37°C
Protease 1	Sigma	0.1 %	30	37°C
Protease K	Sigma	0.25 mg/ml	5	RT
+ DNase	Sigma	5 mg/ml	15	RT
Ficin	Sigma	Undiluted	30	37°C

RT – room temperature

Table 3. Detection systems tested

System	Primary antibody	Secondary antibody	Chromogen
PAP	H 222	Goat anti-mouse	DAB
ABC	H 222	Biotinylated rabbit anti-mouse	DAB
	D 75		
	ER 1 D5		
	I D5		
	NCL-ER-P31		
StrAP	I D5	Biotinylated rabbit anti-mouse	DAB

PAP – peroxidase-antiperoxidase

ABC – avidin-biotin complex

StrAP – streptavidin-peroxidase

DAB – 3,3'-diaminobenzidine tetrahydrochloride

Table 4. ER Streptavidin-peroxidase protocol (Dako, modified)

Step No.	Step name	Duration min:sec
1	Buf 1	00:10
2	Pad 1	00:29
3	Buf 1	00:10
4	Pad 1	00:29
5	Buf 1	00:10
6	Pad 1	00:29
7	Buf 1	00:10
8	Pad 1	00:45
9	AB 1	25:00
10	Pad 1	00:29
11	Buf 1	00:10
12	Pad 1	00:29
13	Buf 1	00:10
14	Pad 1	00:29
15	Buf 1	00:10
16	Pad 1	00:29
17	Buf 1	00:10
18	Pad 1	00:29
19	Buf 1	00:10
20	Pad 2	00:45
21	AB 2	25:00
22	Pad 2	00:29
23	Buf 1	00:10
24	Pad 2	00:29
25	Buf 2	00:10
26	Pad 2	00:29
27	HP block	02:30
28	Pad 2	00:29
29	HP block	02:30
30	Pad 2	00:29
31	HP block	02:30
32	Pad 2	00:29
33	Buf 2	00:10
34	Pad 2	00:29
35	Buf 2	00:10
36	Pad 2	00:29
37	Buf 2	00:10
38	Pad 2	00:45
39	StrAP	25:00
40	Pad 3	00:29
41	Buf 2	00:10
42	Pad 3	00:29
43	Buf 2	00:10
44	Pad 3	00:29
45	Buf 3	00:10
46	Pad 3	00:29
47	Buf 3	00:10
48	Pad 3	00:29
49	Buf 3	00:10
50	Pad 3	00:45
51	Chrom	05:00
52	Pad 3	00:29
53	Buf 3	00:10
54	Pad 3	00:45
55	Chrom	05:00

Step No.	Step name	Duration min:sec
56	Pad 3	00:29
57	Buf 3	00:10
58	Pad 3	00:45
59	Chrom	05:00
60	Pad 3	00:29
61	Buf 3	00:10
62	Pad 4	00:29
63	Buf 3	00:10
64	Pad 4	00:29
65	Buf 3	01:00
66	Pad 4	00:29
67	Buf 3	00:10
68	Pad 4	00:29
69	Buf 3	01:00
70	Pad 4	00:29
71	Buf 2	01:00
72	Pad 4	00:29
73	Buf 2	00:10
74	Pad 4	00:29
75	H ₂ O	00:10
76	Pad 4	00:29
77	H ₂ O	00:10
78	Pad 4	00:29
79	H ₂ O	00:29

Buf – buffer

Chrom – chromogen (DAB)

StrAP – streptavidin-peroxidase

Thus, in the second part of the study, ER immunostaining was performed on the DAKO TechMate 500 immunostainer. This system uses the capillary reaction to draw up reagents to cover the specimens on the specially prepared slides. Prior to staining, routinely fixed paraffin-embedded tissue sections were subjected to antigen retrieval in microwave oven. For the staining of ER, both the original DAKO reagent kit and Streptavidin-peroxidase protocol were used. The step names, number of steps, reagents and incubation times for the individual step are listed on Table 4. However, instead of the original prediluted primary antibody, the antibody used was DAKO 1D5, 1:150. Additionally, in the step 65, originally prescribed hematoxylin was substituted by buffer 3. Final counterstaining with hematoxylin was performed manually.

Controls. Only nuclear immunostaining was interpreted as positive result. Cytoplasmic reactivity, if any, was ignored. As a positive control,

a case of invasive breast carcinoma of known positive ER reactivity determined by DCC assay was included in all batches of paraffin-embedded material to ensure consistency of staining between batches. Cells in the same section, not expected to give positive reactivity with the antibody in question (stromal cells, lymphocytes, etc.), served as intrinsic negative controls.

A specimen was considered "ER positive" by biochemical assay if the result was more than 10 pmol/g protein. For the purpose of this study, a series of "ER positive" tumors from different patients was tested.

Scoring. The staining results were assessed semi-quantitatively according to the percentage of stained tumor cells and the intensity of the staining, using a scale of 1-3 for each of these two components (16). The resulting two figures were multiplied by each other, and the final result expressed as follows: negative (no staining or only an occasional positive cell); weakly positive (+, total score = 1-3); positive (+ +, score 4-6); strongly positive (+ + +, score more than 6).

Results

Positive immunostaining of nuclei was seen in both malignant and benign epithelial cells. Most cases show mild variation in staining intensity, but in few cases there was considerable hetero-

geneity of staining both in tumor and in normal breast epithelium.

All five antibodies to ER tested, gave positive results at least under some conditions of retrieval and/or heavy salt enhancement. The intensity of nuclear staining, however, showed great variations depending on the antibody applied (Table 5).

Analysis of our results confirmed the superiority of monoclonal antibody 1D5 for immunohistochemical determination of ER. In comparison to other antibodies, clone 1D5 not only produced the greatest intensity of staining, that was most extensive, but also gave no background or any cytoplasmic staining. The results were even better when staining had been performed automatically (Fig. 1). The second best results were achieved by ER1D5 and H222. The staining with the latter was acceptable only after protease K + DNase pretreatment. Generally, unsatisfactory stainings showed negative or weak staining of nuclei and extensive background staining of collagen and fat.

Proteolytic enzyme pretreatment gave different results. Protease K and DNase pretreatment resulted in notable enhancement of immunostaining with the antibody H222, whereas ER1D5, and NCL-ER-P31 proved to be less sensitive to this enzyme. Parallel to that, ficin pretreatment gave better staining with H222 compared to ER1D5 and D75. On the other hand, the staining with NCL-ER-P31 and ficin

Table 5: Results of ER staining in formalin-paraffin sections

Antibody	H222	ER1D5	D75	NCL-ER-P31	1D5*	1D5**
Protease K + DNase	+ +	+	ND	+	ND	ND
Protease K + DNase + Os	+ + +	ND	neg	+	ND	ND
Protease K + DNase + Ni	+ +	ND	neg	+	ND	ND
Protease K + DNase + Cu	ND	ND	neg	+	ND	ND
Ficin	+ +	+	ND	neg	ND	ND
Ficin + Os	+ + +	ND	neg	neg	ND	ND
Ficin + Ni	+ +	ND	neg	neg	ND	ND
Ficin + Cu	+ +	ND	neg	neg	ND	ND
MW	+	+ + +	ND	+ +	+ +	+ + +
MW + Os	+ +	ND	+	+ +	+ + +	ND
MW + Ni	ND	ND	+	+ +	+ + +	ND
MW + Cu	ND	ND	+	+ +	+ + +	ND

* manually; ** automatically; Os - Osmium; Ni - Nickel; Cu -Copper; MW - microwave; ND - not done

pretreatment proved to be completely negative.

In our experiment, microwave irradiation produced intense staining with the ER1D5 and 1D5 antibody. However, it only enhanced staining with NCL-ER-P31 and H222. Contrary to that, staining with D75 after microwave pretreatment remained negative.

Copper, nickel, cobalt, and osmium had various influence on intensity of final color products. Among them, the nickel-DAB product provided the highest detection efficiency. Copper-DAB product resulted an indistinct gray black color of nuclei thus providing insufficient contrast after subsequent hematoxylin counterstaining.

Discussion

The application of a suitable immunohistochemical method for assessing of ER in breast cancer on formalin-fixed tissue, contrary to more traditional method based on biochemical assay of estradiol binding in tissue homogenates, has been strongly advocated. The latter method has the disadvantage of being costly, requiring a fairly large amount of tissue homogenate, and being affected by bound estrogen receptor from high endogenous levels of estradiol in premenopausal women.

Immunohistochemistry, on the other hand, would eliminate the need for fresh tissue and has several other advantages. This method is applicable to formalin-fixed, routinely processed tissue and allows ER status to be assessed on the same blocks as those used for histopathological assessment of tumor without preselection of tissue for separate frozen section. This is particularly important in increasingly more frequent small tumors where separate samples for tissue diagnosis and biochemical assessment of ER cannot be taken, as well as in impalpable mammographically detected or unexpected malignancy cases where the carcinoma may be grossly invisible and the only source for ER determination remains paraffin block with microscopically identified tumor tissue. This method also allows improved morpho-

logy and better representation of the tumor, its use in archival material, not to mention the inclination of practicing pathologists to interpret the immunohistochemical findings on paraffin slides.

As immunohistochemistry is extremely technique-dependent, consistent quality can be significantly more difficult to achieve than with other staining techniques. The immunohistochemical ability to stain for cellular proteins is equally dependent on two factors: preservation of the proteins in tissue sections after fixation and processing and quality of the reagents, mainly antibodies, chosen for immunostaining. Pathologists are faced with the decision to expend valuable time and resources on in-house testing of different antibodies, processings and optimizing the procedures. The same holds for ER immunostaining, where the standardization of quality is still a problem even within individual laboratories and reproducibility in general practice is poor.

In this study we decided to compare different commercially available ER antibodies, different methods for tissue digestion, and different detection systems to determine the optimal method for ER immunostaining on formalin-fixed, paraffin-embedded tumor tissue. The comparison of our results showed that the best and most reproducible staining for ER can be achieved using standardized formalin fixation, together with Dako 1D5 primary antibody, microwave antigen retrieval, and Streptavidin-peroxidase protocol performed by an automatic immunostainer. The method we have described is technically easy and rapid to perform, not requiring overnight incubation procedure and gives reproducible results. Indeed, at our Department this method has now been adopted for all cases of primary breast carcinoma, allowing inclusion of ER status as a part of surgical pathology report.

It is beyond the scope of this study to identify a valid cut-off for positivity of ER status using Dako 1D5. Goulding et al found a good correlation in an assessment of ER using Dako 1D5 and Abbott H222 monoclonal antibody. However, in some cases a marked discrepancy was

observed between the scores obtained. This may be attributed to the recognition of different epitopes by the two antibodies (17,18). Similar discrepancies have been observed by others. With the use of the 1D5 antibody a significant increase in the sensitivity of ER determination has been noted together with a more significant correlation with overall survival and disease-free survival than showed previous results with Abbott H222 (19,20).

Moreover, recent data by Battifora and his group indicate that ER staining by Dako 1D5 on archival tumor samples followed by quantification of ER positivity by computerized image analyzer can give even stronger correlation with overall and disease-free survival in breast cancer patients (21).

With the present study we show again that reproducible results in immunohistochemistry are based on controlled conditions and can be achieved mainly on trial and error basis in an individual laboratory, and that no golden rules can be offered.

In conclusion, we have found that assessment of ER status using Dako 1D5 antibody, microwave antigen retrieval, and Streptavidin-peroxidase protocol performed by an automatic immunostainer has many advantages over other antibodies and methods tested.

Acknowledgment

This study was supported by the Institute of Oncology, Ljubljana (Grant No 03 Z 7/C-94).

References

- Lippman ME, Allegra JR. Receptors in breast cancer. *N Engl J Med* 1987; **299**: 930-3.
- Wittliff JL. Steroid-hormone receptors in breast cancer. *Cancer* 1984; **53**: 630-43.
- Thorpe SM, Rose C, Bruun Rasmussen B, Mouridsen HT, Bayer T, Keidling N. Prognostic value of steroid hormone receptors: multivariate analysis of systematically untreated patients with node negative primary breast cancer. *Cancer Res* 1987; **47**: 6126-33.
- Frigo B, Scopsi L, Faber M, Gobbo M, Rilke F. Application of an estrogen receptor-immunocytochemical assay primary monoclonal antibody kit to paraffin-embedded human breast tumor tissue. Personal experience and a review of the literature. *Appl Immunohistochem* 1993; **2**: 136-42.
- Battifora H, Mehta P, Chul Ahn, Esteban JM. Estrogen receptor immunoassay in paraffin-embedded tissue. A better gold standard? *Appl Immunohistochem* 1993; **1**: 39-45.
- Wilbur DC, Willis J, Mooney RA, Fallon MA, Moynes R, di Sant'Agnese PA. Estrogen and progesterone receptor detection in archival formalin-fixed, paraffin-embedded tissue from breast carcinoma: a comparison of immunohistochemistry with the dextran-coated charcoal assay. *Modern Pathology* 1992; **5**: 79-84.
- Greene GL. Application of immunochemical techniques to the analysis estrogen receptor structure and function. In: Litwack G ed. *Biochemical actions of hormones*, vol II. New York: Academic Press, 1984; 207-39.
- Shimada A, Kimura S, Abe K, et al. Immunocytochemical staining of estrogen receptor in paraffin sections of human breast cancer by use of monoclonal antibody: comparison with that in frozen sections. *Proc Natl Acad Sci USA* 1985; **82**: 4803-7.
- Shintaku P, Said JW. Detection of estrogen receptors with monoclonal antibodies in routinely processed formalin-fixed paraffin sections of breast carcinoma. Use of DNase pretreatment to enhance sensitivity of the reaction. *Am J Clin Pathol* 1987; **87**: 161-7.
- Battifora H, Kopinski M. The influence of protease digestion and duration of fixation on immunostaining of keratins: a comparison of formalin and ethanol fixation. *J Histochem Cytochem* 1986; **34**: 1059-100.
- Cohen C, Unger ER, Sgoutas D, Bradley N, Chenggis M. Automated immunohistochemical estrogen receptor in fixed embedded breast carcinoma. *Am J Clin Pathol* 1991; **95**: 335-9.
- Elias JM, Heimann A, Cain T, Margiotta M, Gallery F, Gomes C. Estrogen receptor localization in paraffin sections by enzyme digestion, repeated applications of primary antibody and imidazole. *J Histotechnol* 1990; **13**: 29-33.
- Gown AM, de Wever N, Battifora H. Microwave-based antigenic unmasking. A revolutionary new technique for routine immunohistochemistry. *Appl Immunohistochem* 1993; **1**: 256-66.
- Grogan TM. Automated immunohistochemical analysis. *Am J Clin Pathol* 1992; **98**(4Suppl 1): S35-8.
- Scopsi L, Larsson LI. Increased sensitivity in peroxidase immunocytochemistry. A comparative study of a number of peroxidase visualization methods employing a model system. *Histochemistry* 1986; **84**: 221-30.
- Soomro S, Shousha S, Sinnott HD. Oestrogen and progesterone receptors in screen-detected breast

- carcinoma: an immunohistological study using paraffin sections. *Histopathology* 1992; **21**: 543-7.
17. Snead DRJ, Bell JA, Dixon AR, et al. Methodology of immunohistochemical detection of oestrogen receptor in human breast carcinoma in formalin fixed, paraffin embedded tissue: A comparison with frozen section morphology. *Histopathology* 1993; **23**: 233-8.
 18. Anderson J, Orntoft T, Skovgaard Poulson H. Semiquantitative oestrogen receptor assay in formalin-fixed paraffin sections of human breast cancer tissue using monoclonal antibodies. *Br J Cancer* 1986; **53**: 691-4.
 19. Esteban JM, Ahn C, Battifora H, Mehta P. Biological significance of quantitative estrogen receptor immunohistochemical assay by image analysis in breast cancer patients. *Am J Clin Pathol* 1994; **102**: 158-62.
 20. Pellicer EM, Sundblad A. Evaluation of antibodies to estrogen receptors. Letter. *App Immunohistochem* 1994; **2**: 141.
 21. Esteban JM, Kandalaf PL, Mehta P, Odom-Maryon TL, Bacus S, Battifora H. Improvement on the quantification of estrogen and progesterone receptors on paraffin-embedded tumors by image analysis. *Am J Clin Pathol* 1993; **99**: 32-8.