

# Efficacy and durability of radiopaque gelified ethanol in management of herniated discs

Dimitrij Kuhelj<sup>1</sup>, Anita Dobrovec<sup>2</sup>, Igor Jozef Kocijancic<sup>1</sup>

<sup>1</sup> Clinical Radiology Institute, University Medical Centre Ljubljana, 1000 Ljubljana, Slovenia

<sup>2</sup> Celje General Hospital, Department of Radiology, 3000 Celje, Slovenia

Radiol Oncol 2019; 53(2): 187-193.

Received 21 February 2019

Accepted 25 April 2019

Correspondence to: Assist. Prof. Dimitrij Kuhelj, M.D., Ph.D., Councilor, Clinical Radiology Institute, University Medical Centre Ljubljana, Zaloška cesta 7, SI-1000 Ljubljana, Slovenia. Phone: +386 41 882 991; Fax: +386 1 522 24 97; E-mail: dimitrij.kuhelj@guest.arnes.si

Disclosure: No potential conflicts of interest were disclosed.

**Background.** Percutaneous image-guided intradiscal injection of gelified ethanol was introduced to treat herniated disc disease lately. The aim of the study was to assess clinical efficacy and durability over a 36 months' period.

**Patients and methods.** Eighty-three patients (47 males, 36 females, mean age 48.9 years (18–79 years) were treated between May 2014 and December 2015 for 16 cervical and 67 lumbar chronic contained disc herniations. For pain assessment evaluation, the visual analog scale (VAS) was used. Physical activity, the use of analgesics, patients' satisfaction with the treatment results and patient's willingness to repeat the treatment were also evaluated.

**Results.** Fifty-nine patients responded to questionnaire. 89.8% had significant reduction in VAS after 1 month ( $p < 0.001$ ); 76.9% of patients with cervical symptoms and 93.5% of patients with lumbar symptoms. In cervical group it remained stable, while in lumbar group VAS decreased even more during 36 months ( $p = 0.012$ ). Single patient had spinal surgery. Moderate and severe physical disability prior to treatment (96.6%) was reduced to less than 30% after 12 months. The majority of active patients returned to their regular job (71.1%); 78% needed less analgesics. Only 5.1% patients were not satisfied with the treatment and 10.2% would not repeat the treatment if needed.

**Conclusions.** Percutaneous image-guided intradiscal injection of gelified ethanol is safe, effective and durable therapy for chronic contained cervical and lumbar herniations. Due to minimal invasiveness and long-lasting benefits, this kind of treatment should be proposed to designated group of patients as first-line therapy.

Key words: herniated discs; intradiscal injection; gelified ethanol

## Introduction

Number of adults burdened by acute and chronic back pain is rising in prevalence in the industrialized Western societies lately.<sup>1</sup> Disability with physical and cognitive consequences of the back pain usually leads to long-lasting treatment span, along with the cost of lost productivity, resulting in a substantial societal cost. Deterioration of the intervertebral disk quality with decrease in disc hydration and height reduction with eventual disk bulging, which further affects spatial relationship of the surrounding anatomic structures, primarily muscles and ligaments. Consequently, it may, later in life, lead to severe health issues related to spi-

nal stenosis. The corresponding pain is caused by injury of the nociceptive nerve receptors that get injured and exposed to inflammatory substances in the course of disc degeneration. Hence, the main purpose of the treatment is to lower the intra-discal pressure.<sup>2</sup> Discogenic brachialgia and sciatica can be, from the pathophysiological point of view, characterized as a combination of mechanical nerve disruption, inflammation and up regulated immune response.<sup>3</sup>

Treatment armamentarium for the intervertebral discogenic pain ranges from conservative treatment, minimally invasive interventional treatments up to the total surgical disc excisions and arthrodesis. Surgical treatment is still considered

to be the main treatment choice after failure of conservative therapy. It however results in significant range or readmissions (up to 14.7%) within 30 days.<sup>4</sup> Also, spinal surgery shows no long-term difference when compared with the conservative treatment.<sup>5</sup> Suboptimal surgical outcomes resulted in development of a wide range of minimally invasive image-guided techniques, all of which are based on percutaneous introduction of trocar into the fibrous ring through which chemical, thermal or ablative devices are introduced. All these techniques target reduction of intra-discal pressure. Chemonucleolysis was introduced in 1963 by Smith<sup>6</sup> and was the treatment of choice for more than 2 decades, primarily based on intradiscal injection of chymopapain, achieving high level of treatment success rate, ranging between 80–90% in cervical and lumbar hernias.<sup>7–11</sup> This substance was removed from the market due to safety concerns, mainly anaphylaxis issues.<sup>12</sup> Ethanol substituted chymopapaine as the chemical basis of the interventional chemonucleolysis procedures lately.<sup>13–15</sup> On the contrary to the chymopapaine, pure alcohol did not cause allergic reactions. There were however significant drawbacks linked to the ethanol utilization with uncontrolled leaks of highly liquid non-radio opaque chemical.<sup>12</sup> DiscoGel<sup>®</sup> substance, an ethanol based derivate with ethyl

cellulose (Gelscom<sup>®</sup>, France), used in our study, replaced pure alcohol by adding ethyl cellulose to increase viscosity and Tungsten powder making DiscoGel<sup>®</sup> diffusion visible on fluoroscopy. This results in slower and controlled substance diffusion, without loosing hydrophilic properties of alcohol. Migration of the water from the periphery towards the center of the disc leads to disc decompression and reduction of intradiscal pressure.

## Patients and methods

### Patient selection

Eighty-three consecutive patients, treated by a single interventional neuroradiologist in University Medical Centre Ljubljana and General Hospital Murska Sobota between May 2014 and Dec 2015 were included in the study.

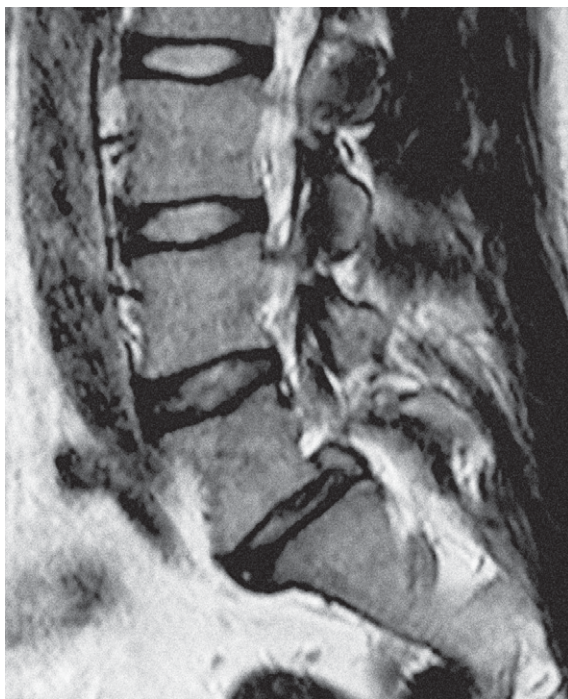
There were 47 male and 36 female patients, age 18–79, mean age 48.9 years treated for persistent pain, present for more than 6 months and not responding to conservative management. Sixteen patients were treated for refractory neck pain and/or brachialgia, while refractory lower back pain and/or sciatica was a primary complaint of 67 patients.

Magnetic resonance imaging (MRI) performed before the procedure confirmed a contained disc rupture and disc degeneration in all included patients (Figure 1). Contained disc rupture was defined as herniated disc bulging into the spinal canal that is still contained by posterior longitudinal ligament; without discal extrusion or sequestration.<sup>16</sup> Additionally, physical examination by the operator was performed prior to the therapy.

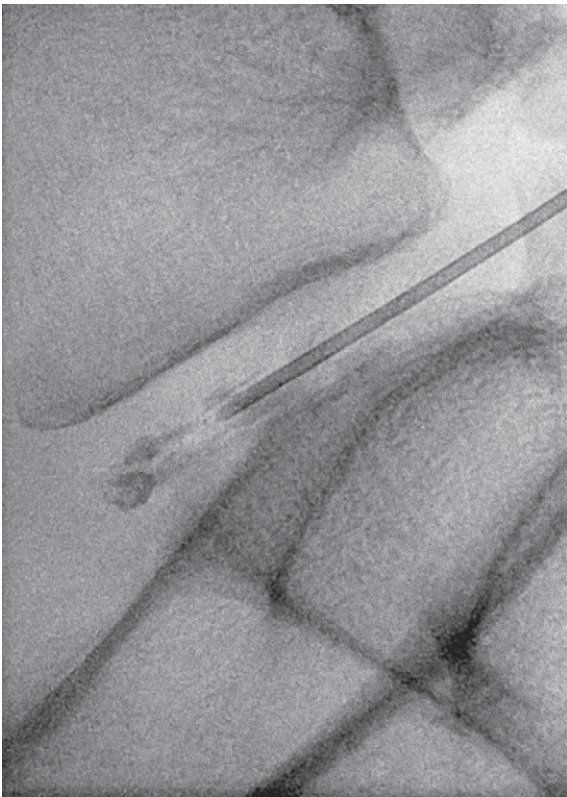
The study protocol was approved by National Ethical Committee (KME 44/06/16); all patients signed informed consent and Helsinki Declaration was followed. Data gathering was performed by questioners, sent to patients 1, 6, 12, 24 and 36 months after the treatment. The data collection was concluded on September 30<sup>th</sup> 2018.

### Treatment planning and delivery

The treatment was performed on fixed angiographic systems, with low frame rate fluoroscopic imaging guidance and under the strict aseptic conditions. All procedures were performed in local anesthesia. Patients with lower back involvement were treated in comfortable lateral decubitus position on their symptomatic side; patients with cervical symptoms were positioned supine. The access was lateral oblique to the disc, 22 Gauge needle



**FIGURE 1.** MR of lumbosacral spine showing herniation on level L5–S1.

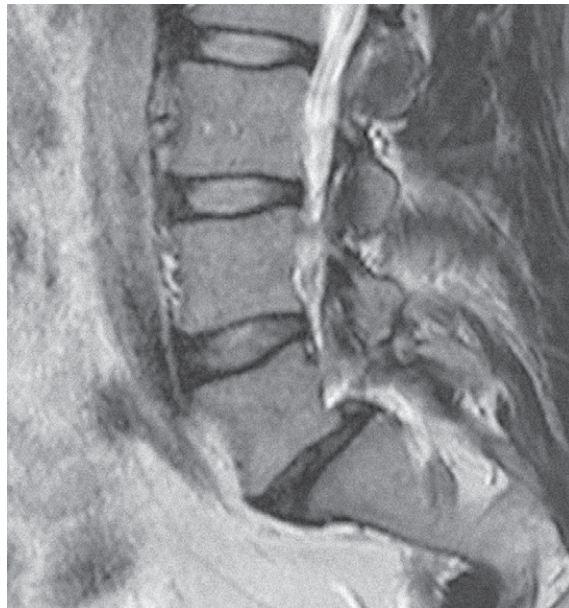


**FIGURE 2.** Fluoroscopic image during DiscoGel® application on level L5–S1.

was used for tract infiltration with 1% Lidocaine® (skin, tract and facet joints). Then 18 Gauge needle was inserted into median and posterior part of the disc and antibiotic prophylaxis with 40 mg of Gentamycin was applied. DiscoGel® was injected slowly and fractionally (0.1 ml during 30 s period) (Figure 2). The expected dosage of DiscoGel® for lumbar spine was 0.6–0.8 ml and up to 0.3 ml for cervical spine. Control of early leakage outside the disc was achieved by fluoroscopic monitoring. The needle was left in place for 2 minutes after the application to prevent late leakage. Patients were hospitalized up to 24 hours.

### Patients' assessment and follow up

Pain intensity was recorded by Visual Analogue Scale (VAS), 0 representing no pain and 10 representing the worst pain imaginable. Pain reduction, expressed as the mean VAS value of all patients was measured prior to the treatment and monitored over 36 months with 5 assessment points: after 1 month, 6 months, 12, 24, and 36 months, respectively. Physical activity of patients was evaluated



**FIGURE 3.** MR control 27 months after application of DiscoGel® showing marked reduction of herniation on level L5–S1.

over 12 months' period. It was distributed in 4 different categories: serious limitations (chair-bound or bed-bound), moderate limitations (seated work with very little option to move around), mild limitations (light work) and no limitations (strenuous work). The use of analgesics was assessed, as was return to fully productive life. Patients' satisfaction with treatment and willingness to repeat the treatment were also recorded. CT and/or MRI follow-up scans were performed only in cases of failure and in certain patients on their or referring physicians' request (Figure 3).

### Statistical analysis

Analysis was performed on the data collected before the treatment and in five designated periods for VAS and up to 12 months for mean physical activity. Descriptive statistics such as mean and range were calculated and displayed.

Statistical significance of VAS reduction 1, 6 and 36 months after the treatment were evaluated by pooled variance t-test. P values < 0.05 were considered as significant.

## Results

Out of 83 patients, included in the study (47 male and 36 female patients, age 18–79, mean age 48.9



**TABLE 1.** The No. of levels treated in patients with herniated discs

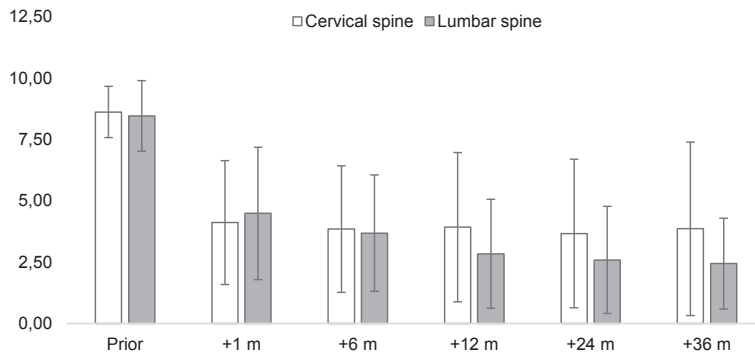
Single level	Two levels	Three levels	Four levels
46 pts (55.5%) (C -10 pts/ L-36 pts)	27 pts (32.5%) (C- 3 pts/ L-24 pts)	9 pts (10.8%) (C- 3 pts/ L-6 pts)	1 pt (1.2%) (L- 1 pt)

C = cervical spine; L = lumbar spine; pt = patient; ptc = patients

**TABLE 2.** The distribution of most commonly affected spine segments

Lumbar spine	L4–L5 (45 pts; 67.2%)	L5–S1 (30 pts, 44.8%)
Cervical spine	C5–C6 (11 pts, 69%)	C3–C4/ C6–C7 (5 pts, 31%)

C = cervical spine; L = lumbar spine; ptc = patients

**FIGURE 4.** Reduction of VAS score during observational period- the difference is statistically significant already 1 month after treatment ( $p < 0,001$ ).

m = month(s).

years), majority was treated on a single level and less than 1/3 of patients were treated on two levels. Only 12% of patients were treated on three or four levels (Table 1). Some patients were treated on a single or on a multiple sessions, due to patients' disposition. The distribution of most common affected segments of the spine is presented in Table 2.

All-together 59 patients (71.1%) responded to questioners, 21 patients with lumbar pathology and 3 with cervical pathology were not accessible to follow up.

**TABLE 3.** Mean VAS reduction (radicular pain in parenthesis)

	CERVICAL SPINE	LUMBAR SPINE
Prior to therapy	8.6 (8,0)	8,5 (8,0)
After 1 month	4.1 (no data)	4,5 (3,7)
After 6 months	3,8 (6,3)	3,7 (3,3)
After 1 year	3,9 (7,3)	2,8 (2,6)
After 2 years	3,7 (6,8)	2,6 (2,4)
After 3 years	3,9 (7,3)	2,4 (2,1)

VAS = visual analog scale

Pain reduction was noted in 53 patients (89.8%), while it persisted in 6 patients. In cervical group the pain was reduced in 10/13 patients (76.9%) while in lower back group the pain was reduced in 43/46 pts (93.5%). The reduction was significant in all patients already after 1 month ( $p < 0,001$ ). VAS reduction remained stable in cervical group for the whole observational period, while additional VAS reduction was observed in patients with lower back pathology ( $p = 0,012$ ) (Figure 4).

The only patient operated from the group was a patient with cervical involvement, operated two years after percutaneous treatment.

Mean reduction of VAS is represented in Table 3. The mean VAS was reduced in cervical involvement for 4.7 points after 6 months, remaining constant until 36 months. In patients with lower back involvement the mean VAS decreased for 5.7 points in 6 months and for 6.7 in 36 months. Similar results were recorded in radicular pain group where mean VAS decreased for 5.4 points in 12 months and 5.9 points in 36 months. Less remarkable results were recorded in cervical radicular pain, where mean VAS lowered for 0.7 points after a year and remaining fairly constant during 36 months.

Evaluation of physical activity, presented in Table 4 showed that 96.6% of patients were seriously to moderately disabled prior to treatment and this reduced post-procedurally to approximately 42 % in 6 months' time, further reducing to less than 30 % one year after the procedure.

**TABLE 4.** Mean physical activity

	Serious limitations	Moderate limitations	Mild limitations	No limitations
Prior to therapy	38/59 (64.4%)	19/59 (32.2%)	2/59 (3.4%)	0
6 months after	3/59 (5.1%)	22/59 (37.3%)	26/59 (44.1%)	8/59 (13.5%)
After 1 year	2/59 (3.4%)	15/59 (25.4%)	32/59 (54.2%)	10/59 (16.9%)

Apart from retired patients (14 pts, 23.7%), the majority of patients returned to their regular job (32 pts, 71.1% of working population), while 6 patients (13.3%) were retired and 7 patients (15.6%) required easier job assignments.

In the post-treatment period more than 3/4 of patients reduced the amount of analgesics as presented in Table 5, while only about 5% needed higher doses. The same percentage of patients treated was also not satisfied with the treatment, as shown in Table 6.

More than 3/4 of the patient population expressed willingness to repeat the treatment if and when deemed needed and about 10% were unwilling to repeat the treatment again (Table 7). The willingness for treatment repetition was lower in patients with cervical pathology (Table 8).

The only postprocedural complication reported was postpunctional syndrome with intracranial hygroma in one patient. It was resolved by surgical drainage. There was no collection locally at the site of the puncture and patient had history of trauma, so the connection with the procedure is difficult to be established.

## Discussion

In the most Western societies low back and neck pain are the leading cause of disability, increasing more than 17% in 10 years' time.<sup>17</sup> Lumbar and cervical disc herniations with radiculitis are considered as one of the most prevalent conditions of back pain. Many minimally invasive therapeutic options were proposed as alternative to surgical management, that is not ideal. Our data confirmed efficacy of percutaneous treatment with Radiopaque Gelified Ethanol in management of herniated discs, resulting in almost 90% of patients treated benefited from such minimally invasive treatment with minimal number of complications. The results proved durable, since benefit extended into a third year after our minimally invasive therapy.

The distribution of discs affected in our patients was similar to other reports; L5/S1 and L4/L5 being the most commonly affected in lower back, while C6/C6 being the most affected in cervical spine.<sup>18,19</sup>

Our results are comparable to results reported by Theron initially<sup>19</sup> (82–91.4% success rate) and confirmed by numerous reports lately.<sup>20-24</sup> We recorded better data in lumbar region (pain was reduced in 93.5% of patients), since in cervical area the pain was reduced in 76.9% of patients. No relevant pain relief in 10.2% of our patients is also

TABLE 5. The use of analgesics after the treatment

Lesser usage	Equal usage	More usage
46/59 (78%)	10/59 (16.9%)	3/59 (5.1%)

TABLE 6. Satisfaction with the treatment

Extremely satisfied	Very satisfied	Moderately satisfied	Not satisfied
35/59 (59.3%)	16/59 (27.1%)	5/59 (8.5%)	3/59 (5.1%)

TABLE 7. Willingness to repeat the treatment in all patients

Very willing	Potentially willing	Not willing
45/59 (76.3%)	8/59 (13.5%)	6/59 (10.2%)

TABLE 8. Willingness to repeat the treatment- cervical

Very willing	Potentially willing	Not willing
9/13 (69.2%)	1/13 (7.7%)	3/13 (23.1%)

similar to reports from majority of studies except report by Leglise<sup>25</sup>, reporting treatment failure rate of 64%, requiring secondary treatment in a cohort of 25 patients. High failure rate reported by Leglise was not confirmed by other authors and neither by our data. However, this report proves that percutaneous treatment with DiscoGel<sup>®</sup> does not interfere with secondary procedures in cases of failure seen also in a single operated patient from our series.

Physical disability is extremely important for patients' quality of life. Our data showed that serious and moderate physical impairment prior to treatment (almost 97% of patients) was converted into mild impairment in more than half of patients after 12 months and even in additional 16.9% of patients presenting no physical limitations at all after the treatment. It is noteworthy mentioning that none of the patients from our cohort was able to perform physical activity without limitations and only a few were able to perform moderate activity prior to treatment. This was converted to more than 70% of patients performing activity without or with only moderate limitations already 12 months after therapy. The practical application of these data resulted in majority of patients (more than 70% of working population) returning to their

previous work. In addition, the use of analgesics was reduced in almost 80% of patients, lowering the costs and reducing potential complications of such therapy. Active life has also an important economic impact on society, reducing disability and raising productivity, since majority of our patients were active population (mean age 48.9 years).

Based on good results and minimal invasiveness of the treatment, our data showed that vast majority of our patients would be willing to repeat the treatment. Since the results are poorer in patients with cervical pathology, especially radicular, less patients from this group were willing to repeat the treatment.

Complications were minimal, one patient had postpunctional syndrome not necessarily attributed to the procedure itself since there was previous history of trauma. No infections or bleedings were reported, only one patient required surgical therapy after the procedure.

Most of the studies published so far focused on immediate or short-term follow-up, reporting results up to 1 year.<sup>18,20,21,23,24,26</sup> Longer follow-up was reported in Croatian multicentric study<sup>27</sup>, however the patients' cohort was smaller than in our study and there were only four patients followed longer than 24 months. Since discal degeneration is a chronic, progressive disease that permanently disables patients and negatively influences their quality of life, long-term results of the treatment are extremely important. In terms of durability, pain reduction was extended into second and third year after the treatment, in patients with lumbar symptoms the pain was further reduced after 36 months. Beneficial long-term effects in both groups showed VAS reduction in patients with lower back pathology around 70% after 3 years and in patients with cervical symptoms the reduction was about 50%. Least marked results were detected in patients with cervical radicular involvement, since overall VAS reduction was about 10%. There were only three patients in this cohort so it is hard to draw firm conclusions. Further studies will have to confirm these biases.

The vast majority of patients treated experienced significant improvement in the post-treatment period; excellent results were achieved in lumbar region, while in cervical region, especially in patients with radicular involvement, pain reduction was less marked. Intra-procedural patient compliance was very high due to minimally invasive percutaneous approach, non-traumatic lesion access, very good procedural cosmetic and virtually no infection or blood loss. The hospitalization time

was minimized to 24h post-procedural monitoring, short recovery time and return to full productive life proved patient-friendly. Also, our results showed long-term durability of the procedure in all patients, especially in those with lower-back symptoms, improving even after 12 months.

The major drawback of our study is that the number of patients included, especially in cervical group is relatively low. Larger cohort might show different results. More than 1/4 of patients did not respond to questioner, so we were able to follow up only 59 patients for the designated period. Observational character of the study could also not exclude additional external parameters (such as different techniques for pain reduction including physical activity, exercises, additional or alternative analgetics, acupuncture etc.) possibly influencing results, especially long-term VAS reduction. A large double-blinded randomized study would be helpful in confirming our data.

## Conclusions

Minimally invasive percutaneous treatment with DiscoGel® in our patient cohort showed very good clinical outcome. The procedure can be considered as a relatively economic, providing a good option for patients with small and medium sized cervical and lumbar herniations that could avoid primary open surgical approach.

## Acknowledgment

The study was not founded by the third party. Authors would like to express their gratitude to Urban Zdešar, M.Sc., physicist for his help in statistical analysis and Draženko Babić, M.D. for his contribute in manuscript.

## References

1. Institute of Medicine. Committee on Advancing Pain Research. *Relieving pain in America: a blueprint for transforming prevention, care, education, and research*. Washington, DC: The National Academies Press; 2011. doi: 10.17226/13172
2. Ray PP. Intervertebral disc: anatomy-physiology-pathophysiology-treatment. *Pain Pract* 2008; **8**: 18-44. doi: 10.1111/j.1533-2500.2007.00171
3. Russell WHJ, Perry AB. Treatment of disk disease of lumbar spine. In: Winn HR, editor. *Youmans neurological surgery*. 5th edition. Philadelphia (PA): WB Saunders; 2004. p. 4513-20.
4. Cusimano MD, Pshonyak I, Lee MY, Ilie G. Causes of 30-day readmission after neurosurgery of the spine. *J Neurosurg Spine* 2016; **24**: 281-90. doi: 10.3171/2015.4.SPINE15445.

5. Weinstein JN, Lurie JD, Tosteson TD, Skinner JS, Hanscom B, Tosteson AN, et al. Surgical vs nonoperative treatment for lumbar disk herniation: the Spine Patient Outcomes Research Trial (SPORT) observational cohort. *JAMA* 2006; **296**: 2451-9. doi: 10.1001/jama.296.20.2451
6. Smith L. Enzyme dissolution of the nucleus pulposus in humans. *JAMA* 1964; **187**: 137-40. doi: 10.1001/jama.1964.03060150061016
7. Theron J, Blais M, Casasco A, Courtheoux P, Adam Y, Derlon JM, et al. Therapeutic radiology of the lumbar spine. Disk chemonucleolysis, infiltration and coagulation of posterior articulations. *J Neuroradiol* 1983; **10**: 209-30. PMID: 6355403
8. Krause D, Drape JL, Jambon F, de Souza-Lima A, Tongio J, Maitrot D, et al. Cervical nucleolysis: indications, technique, results. 190 patients. *J Neuroradiol* 1993; **20**: 42-59. PMID: 8492175
9. Gogan WJ, Fraser RD. Chymopapain: a 10-year, double-blind study. *Spine (Phila Pa 1976)* 1992; **17**: 388-94. PMID: 1579872
10. Smith L. Chemonucleolysis. Personal history, trials, and tribulations. *Clin Orthop Relat Res* 1993; **287**: 117-24. PMID: 8448928
11. Smith L. Enzyme dissolution of the nucleus pulposus in humans. *JAMA* 1964; **187**: 137-40. doi: 10.1001/jama.1964.03060150061016
12. Knezevic NN, Mandalia S, Raasch J, Knezevic I, Candido KD. Treatment of chronic low back pain - new approaches on the horizon. *J Pain Res* 2017; **10**: 1111-23. doi: 10.2147/JPR.S132769
13. Riquelme C, Musacchio M, Mont'Alverne F, Tournade A. Chemonucleolysis of lumbar discs herniation with ethanol. *J Neuroradiol* 2001; **28**: 219-29. PMID: 11924136
14. Bennedbak FN, Nielsen L, Hegedüs L. Effect of percutaneous ethanol injection therapy versus suppressive doses of L-thyroxine on benign solitary solid cold thyroid nodules; a randomized trial. *J Clin Endocrinol Metab* 1998; **83**: 830-35. doi: 10.1210/jcem.83.3.4673
15. Doppman JL, Oldfield EH, Heiss JD. Symptomatic vertebral hemangiomas: treatment by means of direct intralésional injection of ethanol. *Radiology* 2000; **214**: 341-48. doi: 10.1148/radiology.214.2.r00fe46341
16. Silber JS, McGraw KJ and Lippert JA. Section II: Treatment of discogenic back pain. In: McGraw KJ, editor. *Interventional radiology of the spine: image-guided pain therapy*. New York: Springer; 2004. p. 167-80. doi: 10.1007/978-1-59259-418-4
17. GBD 2015 Disease and Injury Incidence and prevalence Collaborators. Global, regional, and national incidence, prevalence, and years lived with disability for 310 diseases and injuries, 1990-2015; a system analysis for the Global Burden of Disease Study 2015. *Lancet* 2016; **388**: 1545-602. doi: 10.1016/S0140-6736(16)31678-6
18. Gangi A, Tsoumakidou G, Buy X, Cabral JF, Garnon J. Percutaneous techniques for cervical pain of discal origin. *Semin Musculoskelet Radiol* 2011; **15**: 172-80. doi: 10.1055/s-0031-1275601
19. Touraine S, Damiano J, Tran O, Laredo JD. Cohort study of lumbar percutaneous chemonucleolysis using ethanol gel in sciatica refractory to conservative treatment. *Eur Radiol* 2015; **25**: 3390-7. doi: 10.1007/s00330-015-3740-1
20. Stagni S, de Santis F, Cirillo L, Dall'Olio M, Princiotta C, Simonetti L, et al. A minimally invasive treatment for lumbar disc herniation: DiscoGel® chemonucleolysis in patients unresponsive to chemonucleolysis with oxygen-ozone. *Interv Neuroradiol* 2012; **18**: 97-104. doi: 10.1177/159101991201800113
21. de Seze M, Saliba L, Mazaux JM. Percutaneous treatment of sciatica caused by a herniated disc: an exploratory study on the use of gaseous discography and DiscoGel® in 79 patients. *Ann Phys Rehabil Med* 2013; **56**: 143-54. doi: 10.1016/j.rehab.2013.01.006
22. Guarneri G, De Dominicis G, Muto M. Intradiscal and intramuscular injection of DiscoGel®: radiopaque gelified ethanol - pathological evaluation. *Neuroradiology J* 2010; **23**: 249-52. doi: 10.1177/197140091002300216
23. Bellini M, Romano DG, Leonini S, Grazzini I, Tabano C, Ferrara M, et al. Percutaneous injection of radiopaque gelified ethanol for the treatment of lumbar and cervical intervertebral disk herniations: experience and clinical outcomes in 80 patients. *AJNR Am J Neuroradiol* 2015; **36**: 600-5. doi: 10.3174/ajnr.A4166
24. Sayhan H, Bayaz SG, Ulgen AM, Yuca MF, Taomak Y. Long-term clinical effects of DiscoGel for cervical disc herniation. *Pain Physician* 2018; **21**: E71-8. PMID: 29357343
25. Leglise A, Lombard J, Moufid A. Discogel in patients with discal lumboscoliotica. Retrospective results in 25 consecutive patients. *Orthop Thraumatol Surg Res* 2015; **101**: 623-6. doi: 10.1016/j.otsr.2015.05.007
26. Theron J, Guimaraens L, Casasco A, Sola T, Cuellar H: Percutaneous treatment of lumbar intervertebral disk hernias with radiopaque gelified ethanol: a preliminary study. *J Spinal Dis Tech* 2007; **20**: 526-32. doi: 10.1097/BSD.0b013e318033e860
27. Houra K, Perovic D, Rados I, Kvesic D. Radiopaque gelified ethanol application in lumbar intervertebral soft disc herniations: Croatian Multicentric Study. *Pain Med* 2018; **19**: 1550-8. doi: 10.1093/pm/pnx270