

**Roy Chan**  
**Michael Newton**  
**Kazunori Nosaka\***

## MEASUREMENT OF BICEPS BRACHII MUSCLE CROSS-SECTIONAL AREA BY EXTENDED-FIELD-OF- VIEW ULTRASOUND IMAGING TECHNIQUE

### MERJENJE PREČNEGA PRESEKA MIŠICE BICEPS BRACHII S TEHNIKO ULTRAZVOČNEGA SLIKANJA Z RAZŠIRJENIM VIDNIM POLJEM

#### ABSTRACT

This study investigated the reliability of the extended-field-of-view (EFOV) ultrasonography technique and its validity against magnetic resonance imaging (MRI) for biceps brachii muscle cross-sectional area (CSA) assessment, and applied the method to examine changes in CSA following 10 sets of 3 maximal eccentric contractions of the elbow flexors. Biceps brachii CSA was assessed using both EFOV and MRI techniques at the mid-point of the upper arm. A Pearson product moment analysis showed a high correlation ( $r = 0.99$ ) between the EFOV and MRI measures; however, the CSA obtained from the EFOV ( $12.5 \pm 6.3 \text{ cm}^2$ ) was smaller ( $P = 0.004$ ) than that of MRI ( $12.9 \pm 6.1 \text{ cm}^2$ ). The reliability of the EFOV technique was assessed using the same scan image tracing twice (between-traces) and two images scanned from the same site (between-scans), and using the images taken from the same site one hour apart (between-measures). An Intra-class correlation (ICC) analysis showed good reliability ( $R = 1.0$ ) for both between-traces and between-scans, and coefficient of variation (CV) was less than 0.1 %. The reliability was also high for the measurements taken one hour apart ( $R = 0.99$ ,  $CV = 0.7$  %). These results show that EFOV is a valid and reliable method to assess biceps brachii CSA, but EFOV could give a smaller (~1 %) CSA than MRI. However, brachialis CSA was difficult to assess in this method, because of the limitation of the scanning technique. Biceps brachii CSA was increased ( $P < 0.05$ ) immediately ( $8.7 \pm 5.8$  %) and 4 days ( $7.7 \pm 6.0$  %) following eccentric exercise of the elbow flexors, illustrating muscle swelling.

*Key words:* Ultrasonography; Magnetic resonance image; Eccentric exercise; Elbow flexors; Upper arm circumference

*Edith Cowan University, School of Exercise and Health Sciences, Joondalup, WA, Australia*

*Corresponding address:*

Kazunori Nosaka, PhD  
School of Exercise and Health Sciences  
Edith Cowan University  
270 Joondalup Drive,  
Joondalup, Western Australia 6027  
Phone: (61 8) 6304 5655  
Fax: (61 8) 6304 5036  
Email: k.nosaka@ecu.edu.au

#### IZVLEČEK

V raziskavi smo preučevali zanesljivost ultrazvočne tehnike z razširjenim vidnim poljem (EFOV) in njeno veljavnost v primerjavi s slikanjem z magnetno resonanco (MRI) pri oceni prečnega preseka (CSA) mišice biceps brachii, metodo pa smo uporabili za preučitev sprememb v CSA po 10 sklopih treh maksimalnih ekscentričnih krčenj upogibalk komolca. CSA mišice biceps brachii smo ocenili z uporabo tehnik EFOV in MRI na srednjem predelu nadlahti. Analiza Pearsonovega korelacijskega koeficienta je pokazala visoko korelacijo ( $r = 0.99$ ) med rezultati EFOV in MRI; vendar pa je bila CSA, pridobljena iz EFOV ( $12,5 \pm 6,3 \text{ cm}^2$ ), nižja ( $P = 0.004$ ) kot pri MRI ( $12.9 \pm 6.1 \text{ cm}^2$ ). Zanesljivost tehnike EFOV smo ocenjevali tako, da smo dvakrat uporabili enako sledenje posnetkov (primerjava sledenja), dva posnetka istega mesta (primerjava posnetkov) in posnetke istega mesta v razmaku ene ure (primerjava mer). Analiza intraklasne korelacije (ICC) je pokazala visoko zanesljivost ( $R = 1,0$ ) tako pri primerjavi sledenja kot posnetkov, koeficient variacije (CV) pa je bil nižji od 0,1 %. Zanesljivost meritev v razmaku ene ure je bila prav tako visoka ( $R = 0,99$ ;  $CV = 0,7$  %). Ti rezultati kažejo, da je EFOV veljavna in zanesljiva metoda ocenjevanja CSA mišice biceps brachii, vendar pa je CSA pri EFOV lahko nižji (~1 %) kot pri MRI. Zaradi omejitev pri tehniki slikanja, je bilo s to metodo težko oceniti CSA mišice brachialis. CSA mišice biceps brachii se je povečal ( $P < 0,05$ ) takoj ( $8,7 \pm 5,8$  %) ter štiri dni po naporu ( $7,7 \pm 6,0$  %), kar kaže na otekanje mišice.

*Ključne besede:* ultrazvok, slikanje z magnetno resonanco, ekscentrična vaja, upogibalke komolca, obseg nadlahti

## INTRODUCTION

In order to evaluate the effect of resistance training on muscle hypertrophy or to assess muscle atrophy with aging, measurement of muscle cross-sectional area (CSA) is imperative (Reeves, Maganaris, & Narici, 2004). Computed tomography (CT) or magnetic resonance imaging (MRI) techniques have been considered as the “gold standard” for CSA measures; however, both techniques are costly and time-consuming (Ahtiainen et al., 2010; Noorkoiv, Nosaka, & Blazevich, 2010). An alternative technology for CSA measures is B-mode ultrasonography, which is relatively less expensive and easily accessible (Ahtiainen et al., 2010; Noorkoiv et al., 2010; Reeves et al., 2004).

Ultrasound extended-field-of-view (EFOV) is a relatively new technique and can form a panoramic image over an area larger than what the traditional ultrasound window can contain. With this technique, as the ultrasound transducer is moved along the region of interest, new imaging frames are combined with previous frames (Weng et al., 1997). Noorkoiv et al. (2010) assessed the reliability and validity of EFOV against CT for quadriceps muscle CSA at 10, 20, 30, 40 and 50% between the central point of the patella and the medial aspect of the anterior superior iliac spine. They reported that the differences in CSA between EFOV and CT were 0.6–4.3% depending on the sites (greater differences for smaller CSAs), and intra- and inter-experimenter reliability ranged 0.6–2.7%. They concluded that EFOV was a valid and reliable tool for assessing quadriceps muscle CSA, and noted that EFOV could provide even more accurate estimates of anatomical CSA of muscles than CT.

It seems reasonable to assume that the EFOV technique can be used to assess CSA of other muscles, but to the best of our knowledge, only the knee extensors have been examined. Noorkoiv et al. (2010) stated that it was difficult to obtain good images when the whole transducer sensor area could not be contacted to the skin without applying pressure on the tissue. It is important to clarify whether EFOV technique can be used for small muscles. Since the surface of the elbow flexors is curvier than the knee extensors, it was assumed that obtaining good EFOV images might be challenging. Therefore, the present study evaluated the EFOV technique for the measurement of CSA of elbow flexor muscles for its validity against MRI measures and intra-tester reliability.

It has been reported that muscle swelling is present for several days following eccentric exercise and is accepted as one of the indications of muscle damage (Chleboun, Howell, Conatser, & Giesey, 1998; Clarkson, Nosaka, & Braun, 1992; Foley, Jayaraman, Prior, Pivarnik, & Meyer, 1999). Previous studies assessed muscle swelling by measuring limb circumference using a tape measure (Paddon-Jones & Abernethy, 2001) and/or muscle thickness using B-mode ultrasound images after eccentric exercise (Nosaka & Newton, 2002b). However, to evaluate muscle swelling more accurately, it is better to measure muscle CSA. Thus, if EFOV can reliably measure CSA of the elbow flexors, it is possible to assess muscle swelling more precisely. Using the established EFOV technique, the present study examined changes in biceps brachii CSA before and for 4 days following eccentric exercise of the elbow flexors, and the relationship between the upper circumference that is often used in the previous studies to assess muscle swelling after eccentric exercise and CSA assessed by EFOV were analysed.

## MATERIALS AND METHODS

### Subjects

Six healthy men (age =  $27.5 \pm 1.9$  yr, height =  $170.0 \pm 10.0$  cm, weight =  $74.0 \pm 12.5$  kg) were recruited for this study to examine the validity and reliability of the EFOV measures. Participants were screened with a medical questionnaire to affirm that they had not suffered from any musculoskeletal injury of the upper extremities. Potential risks and requirements of this study were outlined in an informed consent form document and a written consent was obtained from the participants before their participation in the study. The study was approved by the Human Research Ethics committee at Edith Cowan University.

### Extended-field-of-view imaging

Prior to data collection, the investigator practiced the EFOV technique on several individuals on many occasions until the image was deemed to be acceptable (e.g., whole biceps brachii muscle could be seen with a complete border of the humerus bone). It was found to be impossible to obtain the entire brachialis muscle image by this technique, because the investigator could not move the ultrasound probe around the upper arm of a participant with applying the same pressure throughout the scan. However, it was possible to trace the whole biceps brachii muscle (see Figure 1).

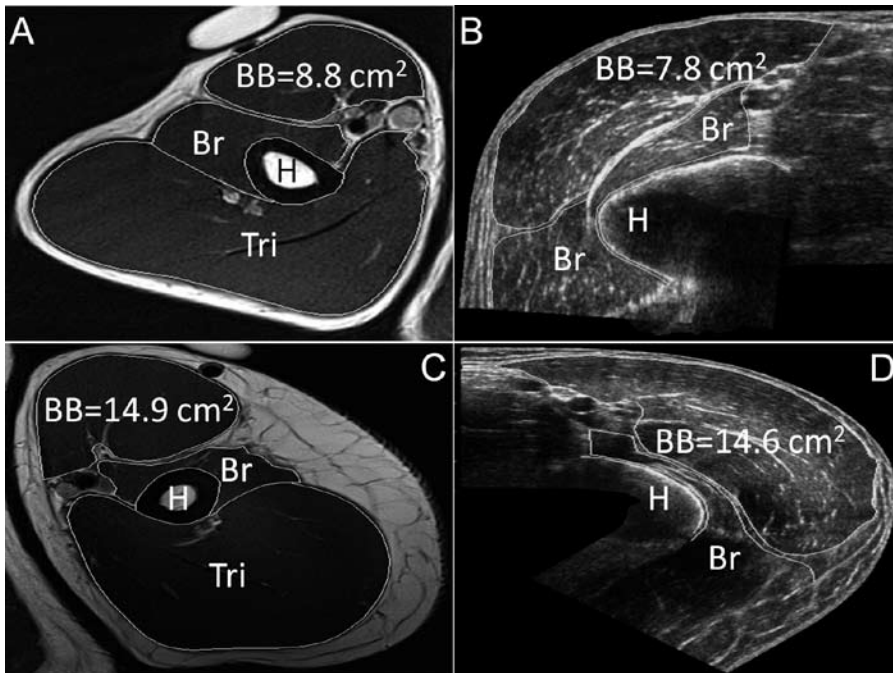


Figure 1: Corresponding axial plane images of the elbow flexors measured at 3 cm below the mid-point of the upper arm by MRI (A, C) and EFOV (B, D). A and B images were from the right arm of one participant, and C and D images were from the left arm of another participant. Major anatomical landmarks are identified; BB – biceps brachii, Br – brachialis, H – humerus, Tri – triceps brachii.

For the CSA measures by the EFOV technique, two regions at 0 cm and 3 cm below mid-point of upper arm were marked on both arms. These two regions were chosen because the largest biceps brachii CSA generally coincides within the 0-cm and 3-cm region. Participants were seated in a comfortable position with arms resting at 90° of shoulder flexion and 0° elbow angle (i.e., straight arm) on a padded armchair. Pressure was applied minimally but consistently, avoiding compression of the muscle, and transmission gel was applied to aid in acoustic coupling. EFOV scans were obtained using an Aloka SSD- $\alpha$ 10 (Aloka Co. Ltd., Tokyo, Japan) with a 7.5 MHz 4.0 cm probe (UST-5412, Aloka Co. Ltd, Japan) by moving the probe along the marked lines axially from the medial aspect to the lateral aspect of the upper arm in a continuous single view (Figure 1). Scanning velocity was controlled to allow clear EFOV images and care was taken to avoid exerting too much pressure on the skin surface. Three scans were taken from each region, and the biceps brachii muscle was traced to calculate its CSA using a computer software program (Image J, version 0.0, National Institute of Health, USA).

### **Magnetic resonance (MR) imaging**

Multiple MR T1-weighted images were taken on the same day as the EFOV imaging approximately 2 hours after the EFOV images, using a Siemens Magnetom Espree 1.5T (Siemens AG, Erlangen, Germany). Participants were laid down with a magnetic coil placed around the arm of interest. Using a fish oil pill to demarcate the corresponding site at 3 cm below the mid-point of the upper arm, which was used for the EFOV scanning, MR images were taken with a scan slice thickness of 4 mm and an inter-slice gap of 0 mm (contiguous images). The biceps brachii muscle CSA was measured using the same software as that used for the EFOV images.

### **Validity and reliability of EFOV**

Both EFOV and MR images were taken from both arms for validity analysis using a Pearson product moment correlation test and a paired t-test. For EFOV, three scans were taken from the 0 cm and 3 cm regions from each arm and the two closest CSA results were used for further analysis. The intra-tester reliability of the EFOV technique was assessed in two ways; using the same scan image and tracing it twice (between-traces) and scanning two images from the same site (between-scans). The test-retest reliability was also assessed using the images taken from the same site one hour apart. Coefficient of variation (CV) and Intra-class correlation (ICC) were used to determine the between-trace, between-scan and between-time reliability. ICC values within the range of 0.8–1.0 were considered as “good” reliability (Cleophas, Zwinderman, Cleophas, & Cleophas, 2009).

### **Changes in biceps brachii CSA following eccentric exercise**

To assess CSA changes following exercise using the EFOV technique, 10 healthy men (age =  $26.1 \pm 4.1$  yr, height =  $173.1 \pm 6.1$  cm, weight =  $72.4 \pm 9.1$  kg) performed 3 sets of 10 maximal eccentric contractions of the elbow flexors on an isokinetic dynamometer (Cybex 6000, Lumex Inc. Runkonkoma, USA) with a HUMAC system (CSMI Medical Solutions, Massachusetts, USA) installed in a computer. Each participant was seated on a preacher curl bench that secured shoulder flexion angle at 45° and performed the eccentric exercise on an isokinetic dynamometer set to allow arm movements from full extension to full flexion while recording the force generation at the wrist during the contraction. During each eccentric contraction, the elbow joint was extended under maximal resistance from an elbow flexed (90°) to a full-extended position (0°)

at an angular velocity of  $30^{\circ} \text{ s}^{-1}$ . Between each contraction, a 9-s rest was provided during which the elbow joint was passively returned to the flexed position at a velocity of  $10^{\circ} \cdot \text{sec}^{-1}$ , and a 4-min passive rest was inserted between sets. The procedures for obtaining EFOV images were the same as those described above. The EFOV images were collected before, immediately after (within 10 min post-exercise) and 1 to 4 days following eccentric exercise to obtain biceps brachii CSA at the 0 and 3 cm regions. Two EFOV scans were taken from each site and the average of the two measures was used for further analysis. Upper arm circumference was measured twice for each site by a constant tension tape measure (Gulick Anthropometric Tape, North Coast Medical, USA) when the participants were standing with arms relaxed at their side in a neutral position (palms facing the thighs), and measurements were taken at the same sites as those used for the CSA measures. The average of the two measures was used for further analysis. The measurements of CSA and upper arm circumference were taken before, immediately after, and 1-4 days following exercise.

### Statistical Analysis

Changes in the CSA and upper arm circumference following eccentric exercise were analysed by a one-way repeated-measures analysis of variance (ANOVA). When the ANOVA showed a significant time effect, a Tukey post-hoc test was applied to compare the values between time points. The correlation between the relative changes in CSA and upper arm circumference from pre-exercise values was analysed by a Pearson product-moment correlation coefficient using the data from all time points (i.e., immediately post, 1-4 days post). Significance level was set at  $P < 0.05$ . The results are shown in mean  $\pm$  SD, unless otherwise stated.

## RESULTS

### Validity

The difference in CSA between the MRI ( $12.9 \pm 6.1 \text{ cm}^2$ ) and EFOV ( $12.5 \pm 6.3 \text{ cm}^2$ ) was small ( $0.4 \pm 0.3 \text{ cm}^2$ ) but significant ( $P=0.004$ ). The CSA measured by MRI was greater at both 0 cm ( $5.1 \pm 4.1\%$ ) and 3 cm ( $4.5 \pm 5.0\%$ ) sites compared with the EFOV values. Pearson product moment correlation indicated that CSA measured by EFOV was highly correlated with that by MRI ( $R=0.99$ ,  $P=0.004$ ).

### Reliability

The reliability was high as indicated by low CV and high ICC R-values for both 0 cm ( $CV=0.08\%$ ,  $R=1$ ) and 3 cm ( $CV=0.07\%$ ,  $R=1$ ) regions for between-traces. This was also the case for the between-scan (0 cm:  $CV=0.1\%$ ,  $R=1$ , 3 cm:  $CV=0.1\%$ ,  $R=1$ ). The test-retest reliability was high for the 0cm ( $CV=0.7\%$ ,  $R=0.99$ ) and 3 cm ( $CV=0.6\%$ ,  $R=0.99$ ) regions.

### Changes in biceps brachii CSA and upper arm circumference following eccentric exercise

Changes in the average CSA obtained from the 0 cm and 3 cm sites before, immediately after and 1-4 days following eccentric exercise are shown in Figure 2A. Both sites showed significant increases compared with the baseline values. The largest increase in CSA was found at 1 day post-exercise ( $12.6 \pm 7.5\%$ ) for the 0-cm site, and immediately post-exercise ( $9.2 \pm 5.9\%$ ) for the 3-cm site. The largest increase in circumference was observed immediately after exercise for

the 0-cm site ( $1.3 \pm 1.3\%$ ) and 2 days post-exercise for the 3-cm site ( $1.9 \pm 1.3\%$ ), and remained greater than the baseline values for 4 days following exercise (Figure 2B).

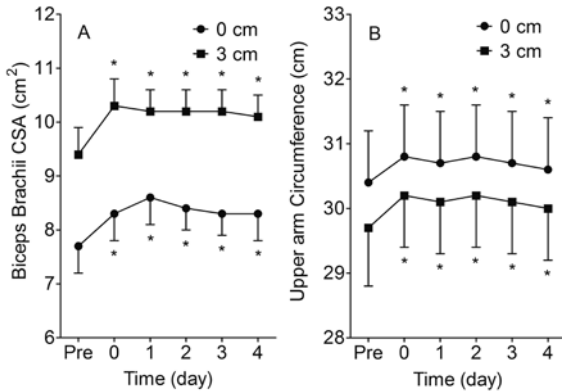


Figure 2: Changes (mean  $\pm$  SEM, n=10) in biceps brachii cross-sectional area (A) and upper arm circumference (B) at the mid-point (0 cm) and 3 cm below the mid-point (3 cm) before (pre), immediately after (0) and 1-4 days following 3 sets of 10 maximal eccentric contractions of the elbow flexors. \* indicates a significant ( $P < 0.05$ ) difference from the pre-values.

**Correlation between biceps brachii CSA and upper arm circumference changes**

As shown in Figure 3, the relative changes in CSA and upper arm circumference from baseline were significantly ( $P < 0.001$ ) but poorly correlated ( $r = 0.43$ ). This was also the case for the analysis for each site separately (0 cm:  $r = 0.43$ , 3 cm:  $r = 0.50$ ,  $P < 0.001$ ). An increase in CSA did not necessarily correspond to an increase in upper arm circumference, and vice versa.

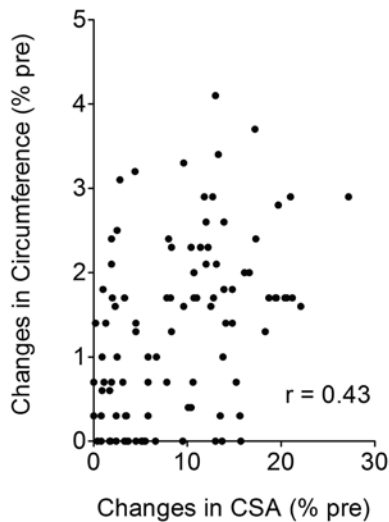


Figure 3: Correlation between biceps brachii cross-sectional area (CSA) and upper arm circumference changes following eccentric contractions of the elbow flexors (0 and 3 cm regions, immediately post and 1-4 days post exercise, 10 participants:  $2 \times 5 \times 10 = 100$  pair samples).

## DISCUSSION AND CONCLUSION

The results showed that the EFOV technique was valid and reliable for measuring biceps brachii CSA at the mid-arm regions. Although the difference was small, the CSA obtained from the EFOV was approximately 1% smaller than that assessed by MRI. When the EFOV technique was applied to assess changes in biceps brachii CSA following eccentric exercise of the elbow flexors, increases in the CSA were found; however, the changes in CSA were poorly correlated with the changes in upper arm circumference.

It should be noted that the EFOV technique was unable to capture the whole brachialis muscle to measure its CSA in the present study. In order to obtain the whole brachialis muscle image, the transducer has to be moved from the medial to lateral aspect of the upper arm, which we found was not possible. In the present study, the transducer (3.6 cm in width) did not allow us to obtain images from participants with small upper arms, because the transducer was unable to glide through the cross section of the arm without deviating from the scanning plane. A smaller transducer (e.g. 2 cm) may be able to overcome this shortcoming; however such transducer is not currently available. The average biceps brachii CSA value measured at 3 cm (~12.5 cm<sup>2</sup>) in the present study was similar to that reported by Kanehisa et al. (1994) who used a specially designed ultrasonic system. McCall et al. (1996) also reported similar biceps brachii CSA (11.8 ± 2.7 cm<sup>2</sup>) to that of the present study using MRI for men prior to resistance training program.

The present study found that the biceps brachii CSA assessed by EFOV was smaller than that by MRI. Noorkoiv et al. (2010) compared the CSA of quadriceps muscles at 10, 20, 30, 40 and 50% of the length between the centre of the patella and the medial aspect of the anterior superior iliac spine using EFOV and CT, and found that CSA was smaller for the EFOV measures when compared with CT at the 10 and 20% regions. They stated that the reason for the difference between the techniques was due to the different measuring planes used, such that the CT measures perpendicular to the measurement table while the EFOV measures perpendicular to the muscle. Ahtiainen et al. (2010) reported that EFOV technique systematically underestimated the CSA of vastus lateralis muscle compared with MRI, as MRI measures in the vertical axis and perpendicularly to the measurement table, but EFOV measures perpendicular to the skin. In the present study, it was noted that participants with smaller biceps brachii CSA had curvier surfaces. In these instances, the EFOV technique was probably more appropriate as the biceps brachii had to be scanned at a slight angle perpendicular to the skin in contrast to the vertically scanned MR images.

The present study showed that the biceps brachii CSA assessed by the EFOV technique was reliable; however, it is important to note that measurement errors could easily occur when scanning EFOV images and tracing a biceps brachii muscle on an EFOV image. In the present study, the investigator practiced EFOV scanning technique many times before actually taking images for the present study. It is also important to know how an EFOV image shows a target muscle to be examined. As shown in Figure 1, the shape of muscles shown in the EFOV images is not the same as that shown in the MR images. The images obtained using EFOV are not as detailed as those taken using MRI or CT, showing only elbow flexor muscle compartment. Tracing a muscle accurately also requires practice; however, once the technique is established, the error involved in the tracing procedure is small. Thus, the EFOV technique could detect as small as a 1% change in biceps brachii CSA.

As shown in Figure 2, the biceps brachii CSA increased approximately 10% immediately after to 4 days following eccentric exercise of the elbow flexors. It has been well documented that muscle swelling is induced by eccentric exercise of the elbow flexors; however, previous studies used upper arm circumference measures (Chleboun et al., 1998; Nosaka & Clarkson, 1996; Nosaka & Newton, 2002a) and/or elbow flexors muscle thickness measures by B-mode ultrasound (Nosaka & Newton, 2002a; Nosaka, Newton, & Sacco, 2002) to quantify the magnitude of swelling. For example, Nosaka et al. (2002) found that upper arm circumference increased by 8.3 mm immediately after 24 repetitions of maximal eccentric exercise, with further increments of up to 14 mm 4 days after performing the exercise. In contrast, upper arm circumference in the present study showed 4-5 mm (1.3-1.7%) increase immediately after eccentric exercise, but no further increases were observed and the circumference recovered to baseline values at day 4 following exercise. It should be noted that CSA was greater at 3 cm compared with 0 cm site, but it was opposite for the upper arm circumference. The greater upper arm circumference at the 0 cm site is likely due to the greater inclusion of the triceps brachii. The similar time course in the changes suggests that the cause of the increase is the same, but it should be noted that the magnitude of change was much greater for the CSA (average: 9.1 %) than upper arm circumference (average: 1.1%). This may be partially due to the difference in the area change versus length change such that a 10% change in length could result in a 21% change in area (e.g.  $5.5^2\pi/5^2\pi=1.21$ ). It is important to note that the changes in CSA and upper arm circumference were poorly correlated. As shown in Figure 3, there are many cases showing no increases in upper arm circumference, even when increases in CSA were evident. It appears that the circumference measure could not detect possible swelling as accurately as CSA. Although limb circumference is generally used to estimate muscle swelling, it cannot discriminate swelling in different muscle compartments within the same limb (Howell, Chleboun, & Conatser, 1993; Nosaka & Clarkson, 1996). Imaging of the muscle compartment by MRI, CT or ultrasound could provide a more direct way of assessing muscle swelling (Chleboun et al., 1998). Further study is necessary to investigate the relationship between limb circumference and CSA.

The EFOV technique is a valid and reliable method to assess biceps brachii CSA, and it is possible to detect 1% CSA change, thus it can be employed in studies examining changes in CSA over time. However, ample practice with scanning and tracing techniques are necessary to obtain accurate results. Muscle swelling after eccentric exercise of the elbow flexors was detected by increases in biceps brachii CSA using EFOV, however CSA changes were not highly correlated with the upper arm circumference changes. Therefore, to quantify muscle swelling after eccentric exercise it may be better to measure CSA than circumference, as the circumference measure has a greater possible margin of errors and the magnitude of change in upper arm circumference is smaller than that of CSA.

## REFERENCES

- Ahtiainen, J. P., Hoffren, M., Hulmi, J. J., Pietikainen, M., Mero, A. A., Avela, J., & Hakkinen, K. (2010). Panoramic ultrasonography is a valid method to measure changes in skeletal muscle cross-sectional area. *European Journal of Applied Physiology*, 108, 273-279.
- Chleboun, G. S., Howell, J. N., Conatser, R. R., & Giesey, J. J. (1998). Relationship between muscle swelling and stiffness after eccentric exercise. *Medicine and Science in Sports and Exercise*, 30, 529-535.
- Clarkson, P. M., Nosaka, K., & Braun, B. (1992). Muscle function after exercise-induced muscle damage and rapid adaptation. *Medicine and Science in Sports and Exercise*, 24, 512-520.



- Cleophas, T. J., Zwinderman, A. H., Cleophas, T. F., & Cleophas, E. P. (2009). *Statistic applied to clinical trials* (4th ed.). New York, USA: Springer Science+Business Media B.V.
- Foley, J. M., Jayaraman, R. C., Prior, B. M., Pivarnik, J. M., & Meyer, R. A. (1999). Mr measurements of muscle damage and adaptation after eccentric exercise. *Journal of Applied Physiology*, 87, 2311-2318.
- Howell, J. N., Chleboun, G., & Conatser, R. (1993). Muscle stiffness, strength loss, swelling and soreness following exercise-induced injury in humans. *Journal of Physiology*, 464, 183-196.
- Kanehisa, H., Ikegawa, S., & Fukunaga, T. (1994). Comparison of muscle cross-sectional area and strength between untrained women and men. *European Journal of Applied Physiology and Occupational Physiology*, 68, 148-154.
- McCall, G. E., Byrnes, W. C., Dickinson, A., Pattany, P. M., & Fleck, S. J. (1996). Muscle fiber hypertrophy, hyperplasia, and capillary density in college men after resistance training. *Journal of Applied Physiology*, 81, 2004-2012.
- Noorkoiv, M., Nosaka, K., & Blazevich, A. J. (2010). Assessment of quadriceps muscle cross-sectional area by ultrasound extended-field-of-view imaging. *European Journal of Applied Physiology*, 109, 631-639.
- Nosaka, K., & Clarkson, P. M. (1996). Changes in indicators of inflammation after eccentric exercise of the elbow flexors. *Medicine and Science in Sports and Exercise*, 28, 953-961.
- Nosaka, K., & Newton, M. (2002a). Concentric or eccentric training effect on eccentric exercise-induced muscle damage. *Medicine and Science in Sports and Exercise*, 34, 63-69.
- Nosaka, K., & Newton, M. (2002b). Is recovery from muscle damage retarded by a subsequent bout of eccentric exercise inducing larger decreases in force? *Journal of Science and Medicine in Sport*, 5, 204-208.
- Nosaka, K., Newton, M., & Sacco, P. (2002). Responses of human elbow flexor muscles to electrically stimulated forced lengthening exercise. *Acta Physiologica Scandinavica*, 174, 137-145.
- Paddon-Jones, D., & Abernethy, P. (2001). Acute adaptation to low volume eccentric exercise. *Medicine and Science in Sports and Exercise*, 33, 1213-1219.
- Reeves, N. D., Maganaris, C. N., & Narici, M. V. (2004). Ultrasonographic assessment of human skeletal muscle size. *European Journal of Applied Physiology*, 91, 116-118.
- Weng, L., Tirumalai, A. P., Lowery, C. M., Nock, L. F., Gustafson, D. E., Von Behren, P. L., & Kim, J. H. (1997). Us extended-field-of-view imaging technology. *Radiology*, 203, 877-880.