

# Progresivni mišični izpad zaradi hernije medvretenčne ploščice v nosečnosti: prikaz primera

## Progressive muscle weakness due to lumbar disc herniation in pregnancy: A case report

Avtor / Author

Ustanova / Institute

Gregor Rečnik<sup>1,2</sup>

<sup>1</sup>Univerzitetni klinični center Maribor, Klinika za kirurgijo, Oddelek za ortopedijo, Maribor, Slovenija ; <sup>2</sup>Univerza v Mariboru, Medicinska fakulteta, Maribor, Slovenija

<sup>1</sup>University Medical Centre Maribor, Division of Surgery, Departments Of Orthopaedics, Maribor, Slovenia; <sup>2</sup>University of Maribor, Faculty of Medicine, Maribor, Slovenia

### Ključne besede:

hernija diska, operacija hrbtenice, nosečnost

### Key words:

disc herniation, spine surgery, pregnancy

### Članek prispel / Received

5. 4. 2017

### Članek sprejet / Accepted

4. 10. 2017

### Naslov za dopisovanje /

#### Correspondence

Doc. dr. Gregor Rečnik, dr. med.

UKC Maribor,

Oddelek za ortopedijo

Ljubljanska 5, 2000 Maribor

Telefon +386 23211432

E-pošta: gregorrecnik@yahoo.com

### Izvleček

**Namen:** Ukleščenje korenine ledvene ga živca zaradi hernije medvretenčne ploščice se v nosečnosti redko pojavi. Ustrezno ukrepanje temelji na pomoči nosečnici in sočasni zaščiti ploda.

**Poročilo o primeru:** Predstavljen je primer 35-letne ženske v 15. tednu nosečnosti s hudo bolečino in z znaki progresivne mišične oslabelosti zaradi hernije medvretenčne ploščice na nivoju L4–L5. Z namenom odprave bolečin in preprečitve trajne nevrološke okvare je bila opravljena kirurška dekompresija.

**Zaključek:** Zdravljenje hernije medvretenčne ploščice v nosečnosti je v večini primerov konzervativno. Redko je v primeru nevarnosti trajne nevrološke okvare potreben operativni poseg, pri katerem moramo upoštevati specifičnosti fiziološkega stanja nosečnice in ploda.

### Abstract

**Purpose:** Low back pain with radiculopathy caused by lumbar disc herniation is a rare presentation in pregnancy. Appropriate management is based on helping the gravida, while protecting her unborn offspring.

**Case report:** A case of a 35-year-old pregnant woman in the 15th week of pregnancy with disabling pain and progressive motor weakness due to L4–L5 disc herniation is presented. Surgical decompression was performed with an aim to alleviate disabling pain and improve muscle strength.

**Conclusions:** Treatment of disc herniation in pregnancy is conservative in the majority of cases. In the rare likelihood of permanent neurologic sequelae, surgical decompression is indicated, taking into account the specific physiologic condition of pregnancy.

## INTRODUCTION

Low back pain is a common complaint of pregnant women. Low back pain affects > 50% of pregnant women (1); however, radiculopathy caused by a lumbar disc herniation is rare, affecting 1 in 10,000 pregnancies (2), which is equal to 2 cases among 20,000 pregnant women who deliver babies in Slovenia annually (3). The standard mode of treatment for this low back pain is conservative with physiotherapy, rest, analgesia, and epidural injections, which is successful in approximately 85% of patients (4). Only 15% of patients (approximately 1 parous woman every 3–4 years in Slovenia) are believed to develop the cauda equina syndrome or a progressive neurologic deficit, which are indications for surgical treatment due to the possibility of irreversible neurologic sequelae that might ensue (5). Since 1992, 22 reports of spine surgery for disc herniation in pregnant women have been reported in the literature, along with some important issues to be considered (5).

## CASE REPORT

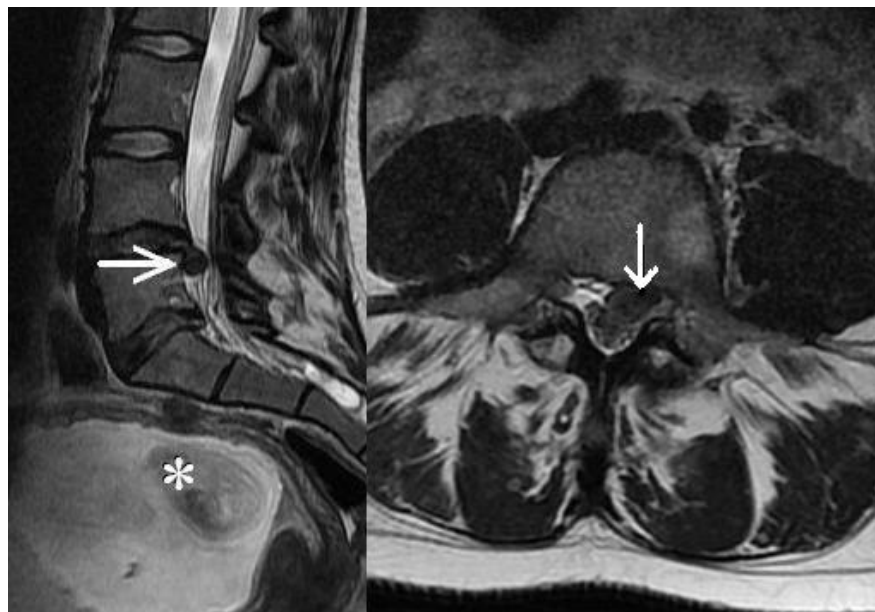
A 35-year-old patient in the 15th week of pregnancy presented to the Emergency Orthopedic Department with a 4-week history of back and left leg pain. She had been treated conservatively by her general practitioner (GP) with rest and an analgesic; physiotherapy was deemed intolerable. Reference by the GP was made due to an inability to perform dorsiflexion of her left foot and toe, which occurred 2 days earlier. She reported slight improvement of the left leg pain (Visual Analogue Scale – VAS 8/10), but her back and buttock pain worsened (VAS 10/10), resulting in significant disability (Oswestry Disability Index – ODI 0.92). At the time of presentation, she was unable to sit on a chair, she was able to walk with considerable difficulty, and enormous effort was needed to lie down on an examining table. The left straight leg raise test was positive at 30°. Hyposensitivity was noted on the lateral side of the leg and medial side of the foot, with weakness of the extensor hallucis longus muscle (grade 1/5). The clinical suspicion of L5 neural root damage due

to a left-sided L4–L5 herniated disc was confirmed with an MRI without the use of a paramagnetic contrast agent (Figure 1). After consulting an anesthesiologist and a gynecologist, conservative and operative treatment options with the benefits and drawbacks were discussed with the patient. The patient made an informed decision to proceed with urgent surgery to restore the progressive neurologic deficit of the left foot and to alleviate disabling pain. An uneventful 30 min microdiscectomy was performed with the patient in the standard prone knee-to-chest position under general anesthesia. The spine segment involved was determined with standard anatomic landmarks without the use of conventional fluoroscopy. The patient reported immediate relief of leg pain and her muscle strength improved within the next 3 days (up to grade 4/5), at which time she was released from the hospital. An obstetric ultrasound was performed the day following surgery that confirmed fetal well-being.

The remainder of the pregnancy was uneventful under close monitoring by her treating obstetrician. The patient had additional post-operative physiotherapy with good resolution of the neurologic symptoms and lumbar spine-related disability (VAS [leg pain] 2/10; VAS [back pain] 2/10; ODI 0.21) at the 2-month follow-up. The patient made an informed decision to deliver the baby via elective cesarean section; however, an emergency cesarean delivery was performed at 38 weeks gestation due to abnormalities in the cardiotocography consistent with fetal distress. At the time of delivery, a nuchal cord was noted. At the time of delivery, the neonate's vital signs were normal, and crying was immediate and spontaneous. The mother and infant were discharged on the 3rd postpartum day.

## DISCUSSION

The pathophysiology of low back pain in pregnancy is a combination of impaired motor control and biomechanical causes. With advancing pregnancy, the abdominal muscles stretch and there is a significant reduction in the strength and coordination of the lumbopelvic muscles, thus producing pelvic girdle pain. The enlarging uterus also increases the abdomi-



**Figure 1.** Sagittal and transverse images of the lumbar spine MRI in a primigravida at 15 weeks gestation (asterisk) demonstrating large left-sided disc herniation at the L4–L5 level (arrow) causing significant pain and motor weakness (grade 1/5) due to compression of the L5 nerve root.

nal sagittal diameter, causing a clear shift in the center of gravity anteriorly, with an increased axial load on the intervertebral disc (6). A previously degenerated disc might consequently rupture and herniate, causing significant disability due to sciatica.

When low back pain with or without radiation to the lower limbs is the main symptom in the absence of motor weakness, severe cauda equina syndrome, or spinal cord compromise, conservative treatment, including bed rest, analgesics, muscle relaxants, and physical therapy, is suggested. With this approach, most pregnant women can deliver their fetuses without complications and an elective surgical intervention post-delivery, if deemed necessary (7). The absolute indications for a herniated lumbar disc operation in pregnant women are not different from the general population, and consist of cauda equina syndrome and progressive motor weakness. Due to high levels of maternal stress, which increases the risk of abortion or preterm delivery, incapacitating pain unresponsive to conservative treatment is also a reasonable indication for surgery (8). In our clinical case, obvious

disability due to aggravating pain accompanied by a progression of a motor deficit in the leg might have been an early sign of further neurologic deterioration. Taking into account significant spinal canal compression visible on a MRI, development of a cauda equina syndrome would be likely.

It has been suggested that performing a MRI during the first trimester of pregnancy should be avoided due to the ongoing process of organogenesis, although no studies demonstrating harmful effects of MRI on the fetus have been presented. Use of a paramagnetic contrast agent, however, has been advised against because animal studies have demonstrated increased rates of spontaneous abortion, and skeletal and visceral abnormalities with the use of gad-

olinium (9).

Anesthesia management is aimed at maternal safety, optimal analgesia, and prevention of hypotension, hypoxia, and preterm labor. Pregnant patients pose unique risks during general anesthesia, which might include potential drug exposure of the fetus, directing many to use regional anesthesia instead. No study has found an association between improved fetal outcome and any specific anesthetic technique, with a warning on the use of benzodiazepines, which can cause fetal malformations (10). Endoscopic discectomy, which has also been successfully used in this group of patients, has an additional advantage of not requiring general or epidural anesthesia (11). Mastering this specific surgical technique with additional technical requirements is unusual in an average-size spine setting.

Positioning the pregnant patient on the operating table has been one of the main issues of surgery, because most surgeons, the authors included, are only familiar with the prone position. In our case, a decision was made to use prone knee-chest positioning with ab-

dominal decompression, which is not recommended after 12 weeks gestation, but it is an acceptable option during the first and early second trimester (12). The left lateral decubitus position is usually recommended in the latter half of the second trimester to avoid aortocaval compression at which time delivery of the fetus cannot yet be performed (7). We believe adopting an unfamiliar left lateral decubitus position was unnecessary, and with the possibility of learning-curve-complications, unjustified in our patient at 15 weeks pregnancy. With patients in the third trimester, a cesarean section is usually recommended when feasible, followed by a microscopic discectomy in the prone position (5).

According to the NASS - SMaX (North American Spine Society - Sign, Mark and X-ray) protocol, intra-operative X-ray confirmation of the involved lumbar segment is obligatory to ensure that the proper surgical level is identified (13). Although a single diagnostic X-ray procedure with exposure < 5 rads has

not been associated with harmful fetal anomalies or pregnancy loss (14), a decision was made in our case to avoid fluoroscopy. Classical anatomic landmarks (the iliac crest line and palpating for the second inter-laminar space cranial of the sacrum - both indicating the L4-L5 level) were successfully used to determine the appropriate level for the skin incision (15).

## CONCLUSION

Surgical management of a lumbar disc herniation in pregnant women is uncommon and should not be overlooked. Conservative treatment has been shown to be successful in a majority of cases; however, taking into consideration the appropriate indications, diagnostic options, use of fluoroscopy, and positioning of the patient and anesthesia, the procedure should not be delayed when absolutely indicated, as permanent neurologic sequelae might occur.

## REFERENCES

1. Matthews LJ, McConda DB, Lalli TAJ, Daffner SD. Orthostetrics: Management of orthopedic conditions in the pregnant patient. *Orthopedics* 2015; 38 (10): e874-80. doi: 10.3928/01477447-20151002-53
2. LaBan MM, Perrin JCS, Latimer FR. Pregnancy and the herniated lumbar disc. *Arch Phys Med Rehabil* 1983; 64 (7): 319-21.
3. Republika Slovenija. Statistični Urad: <http://www.stat.si/StatWeb/News/Index/5730>
4. Fager CA. Observations on spontaneous recovery from intervertebral disc herniation. *Surg Neurol* 1994; 42: 282-6.
5. Ardaillon H, Laviv Y, Arle JE, Kasper EM. Lumbar disc herniation during pregnancy: a review on general management and timing of surgery. *Acta Neurochir (Wien)* 2017; doi: 10.1007/s00701-017-3098-z.
6. Bhardwaj A, Nagandla K. Musculoskeletal symptoms and orthopaedic complications in pregnancy: pathophysiology, diagnostic approaches and modern management. *Postgrad Med J* 2014; 90 (1066): 450-60.
7. Di Martino A, Russo F, Denaro L, Denaro V. How to treat lumbar disc herniation in pregnancy? A systematic review on current standards. *Eur Spine J* 2017; doi: 10.1007/s00586-017-5040-8
8. Pike IL. Maternal stress and fetal responses: evolutionary perspectives on preterm delivery. *Am J Hum Biol* 2005; 17: 55-65.
9. Wang PI, Chong ST, Kielar AZ, Kelly AM, Knoepp UD, Mazza MB et al. Imaging of pregnant and lactating patients: part 1, evidence-based review and recommendations. *AJR Am J Roentgenol* 2012; 198 (4): 778-84.
10. Iyilikci L, Erbayraktar S, Tural AN, Celik M, Sannav S. Anesthetic management of lumbar discectomy in a pregnant patient. *J Anesth* 2004; 18 (1): 45-7.
11. Han IH. Pregnancy and spinal problems. *Curr*

- Opin Obstet Gynecol 2010; 22 (6): 477–81.
12. Han IH, Kuh SU, Kim JH, Chin DK, Kim KS, Yoon YS et al. Clinical approach and surgical strategy for spinal diseases in pregnant women: A report of ten cases. *Spine (Phila Pa 1976)* 2008; 33 (17): E614–E619.
  13. Wong DA. Open Lumbar Microscopic Discectomy. In: *Spine Surgery – tricks of the trade*. 2nd ed. Vaccaro AR, Albert TJ, eds. Thieme. New York, 2009: pp. 119–21.
  14. ACOG Committee on Obstetric Practice. Number 299, September 2004. Guidelines for diagnostic imaging during pregnancy. *Obstet Gynecol* 2004; 104 (3): 647–51.
  15. Kanas M, Kunzle H, Martins DE, Kirsch LA, Puersta EB, Wajhenberg M. Discectomy during pregnancy: Case report and review of the literature. *Global Spine J* 2015; 5; 130–4.