

THE INSTITUTE OF ONCOLOGY, LJUBLJANA, YUGOSLAVIA

## **NORMAL TISSUE TOLERANCE FOR INTRAARTERIAL REGIONAL CHEMOTHERAPY COMBINED WITH IRRADIATION**

by

S. Plesničar, M. Auersperg, M. Us-Krašovec and M. Erjavec

UDK: 616.13-031.61-085.28 + 615.849:611-31-018

### **Introduction**

This report is concerned with the treatment of head and neck tumors using a combination of chemotherapy followed by percutaneous irradiation.

Several reports have been published describing the technique and experience in the simultaneous use of chemotherapy and irradiation. (Langdon, E. A. et al. 1963, Friedman, M., and Daly, J. F. 1967, von Essen, C. F. et al. 1968, Jesse, R. H. et al. 1969). With some exception the limiting factor in the attempt to combine a regression inducing dose of chemotherapeutic agent with cancericidal irradiation was the effect on the normal surrounding tissue which defines the limit of the dose. (Berry, R. J. 1968.) Such effects have not been observed when using a sequential approach, i. e. firstly the application of chemotherapy by intraarterial infusion followed, after an interval of two weeks, by percutaneous irradiation, (Johnson, R. O. et al. 1965). Following this line and in order to increase the maximum effect on the tumor, our treatment program consisted in the simultaneous application of two cytostatic drugs which lasted intermittently from 7 to 24 days, followed by a rest period of two to three weeks and thereafter combined with the full course treatment with percutaneous tele-gamma therapy.

### **Material and methods**

The report is based on 22 cases with malignant neoplasms all of them squamous cell carcinomas of the tongue, base of the tongue and floor of the mouth. In accordance with classification recommended by UICC they were classified as stage III and IV.

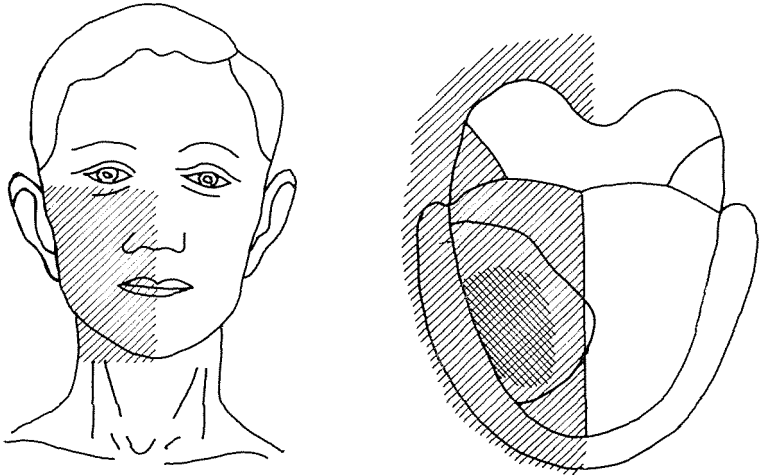


Fig. 1. Schematic representation of infused area, via temporal artery.

The intraarterial infusion has been applied through the insertion of a Teflon catheter (AB Stille = Werner, Stockholm, Outer diam.: 1,10/1,20, inner diam.: 0,75/0,85) via the superficial temporal artery. Using this approach the mucous is well perfused, but usually no uptake of the dye has been observed in the central necrotic area of the tumor. The position of the catheter was checked by using Patent blue dye as well as by isotope scanning with MARA I-131 (Fig. 1).

Methotrexate has been applied in doses varying from 100 to 300 mg together with Proresid in doses from 2000 to 6000 mg. The controls of the effect has been performed by repeated aspiration biopsies showing morphological changes on malignant cells consisting in (1) enlargement of the cells, (2) vacuolisation of the cytoplasm, (3) disruption of cellular membranes, and (4) disintegration of nuclei (Fig. 2).

### Observations

The mucositis which appears during the application of chemotherapy consists of injection of the mucous membrane, with whitish and yellowish membranes, sometimes with small erosions. These changes could appear even after a single application of chemotherapy but when treatment is stopped usually disappeared rather quickly. The tumor regression is considered as good: in 11 out of 15 cases a 50% reduction of the tumor size has been observed, this correspond to the group III according to the classification proposed by Cachin. The rest period lasted from two to three weeks thus permitting the complete disappearance of symptoms as well as improvement of patients general conditions.

The irradiation which followed has been carried out with cobalt unit using two opposite portals covering the primary and the first lymph node

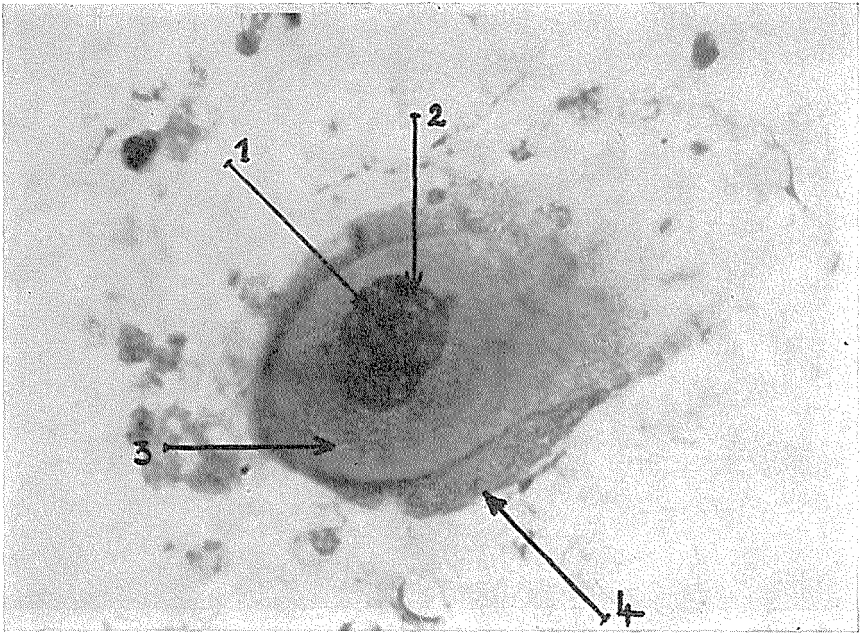


Fig. 2. Squamous cancer cell after SP-I, 4000 mg, methotraxate 150 mg, i. a., showing nuclear enlargement and corrugation of nuclear membrane (1), nuclear vacuolisation (2), cytoplasmic vacuolisation (3) and pycocytosis (4). M. G. G.  $45 \times 8$ .

drainage system. The field size was usually 8 cm per 10 cm, daily dose varying from 150 to 180 rads with a total dose of 6000 rads.

At the dose of 3000 rads a moderate reaction appeared consisting of injection of the mucous together with small patchy pseudomembranes. These changes remained constant through the treatment period. When compared the infused and irradiated mucous membrane no observable differences were noted. The irradiation treatment course remained relatively mild. Even after the dose of 6000 rads has been applied the reaction was essentially the same.

The tumor regression was complete in the treated cases after the completion of the treatment. In none of the cases the treatment has been interrupted (Fig. 3 and 4).

### Discussion

According to our experiences the full dose percutaneous irradiation could be applied in cases where the tumor area has been treated by intra-arterial infusion with a combination of two cytostatic drugs. Therefore it would be of interest the possible evaluation of the total applied dose when only irradiation would have been used.

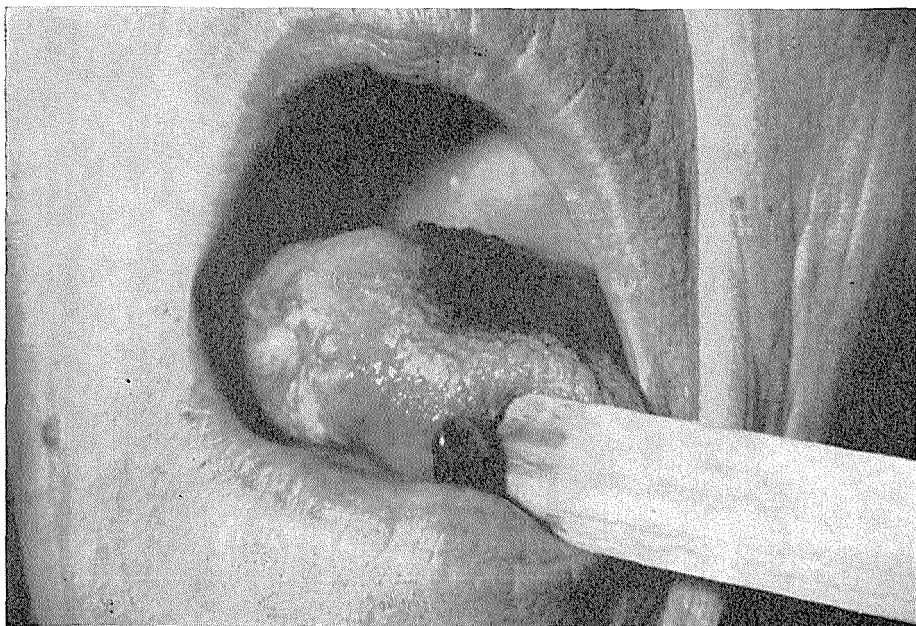


Fig. 3. Representative case of carcinoma of the tongue, before treatment.

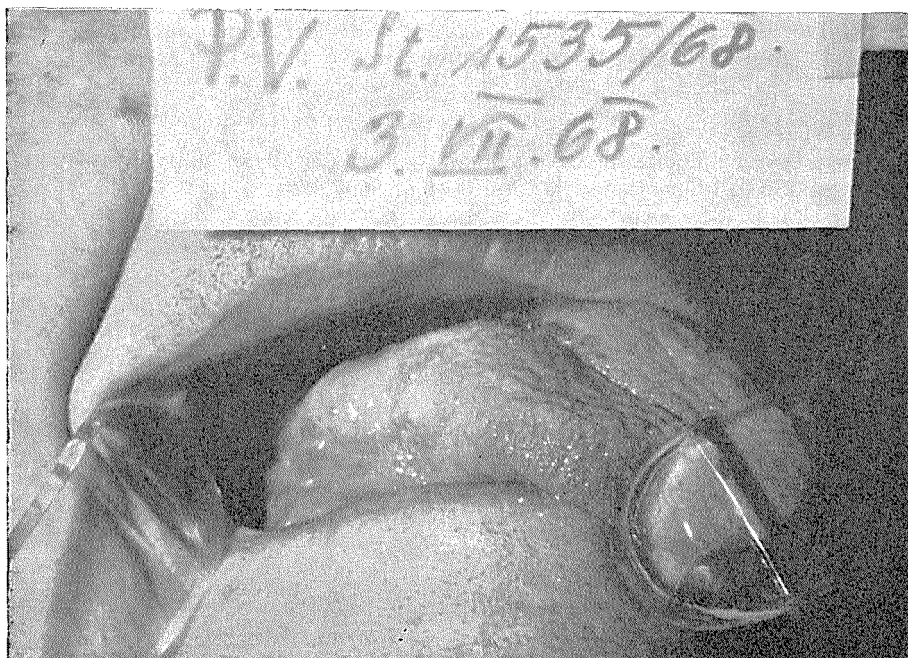

Fig. 4. The same case one month after completed treatment with intraarterial chemotherapy, combined with percutaneous irradiation.

We compared the used treatment scheme to what is called in radiotherapy the split-course technique. According to the Strandquist lines the applied chemotherapy leading to local mucositis would correspond to a radiation dose of 4000 rads for a minimum treatment time being 7 days and to 6000 rads for 24 days treatment period. Together with the irradiation dose the total dose would have been 10 000 rads in 69 days or as a maximum 13 000 rads in 86 days. According to this hypothetical calculation the tumor received supralethal doses which are sufficient for sterilizing the malignancy. On the other hand we do not know very much about the reacting capacity of the surrounding tissue which is essential for tumor healing. In this direction further work is necessary.

### Summary

The authors have reported the treatment scheme and early results in the treatment of head and neck tumors with intraarterial regional infusion with chemotherapy combined with percutaneous irradiation. They have found that a full course radiation treatment could be applied in previously treated area with chemotherapy.

### Povzetek

V svojem delu avtorji poročajo o kombinirani metodi zdravljenja malignomov ustne votline z uporabo intraarterielne aplikacije citostatikov in zatem sledečega obsevanja. Ugotove, da je mogoče potem ko je bila aplicirana doza citostatikov, ki povzroča klinično opazno regresijo tumora, dodatno obsevat i spolno tumorsko dozo.

### Literature

1. Jesse, R. H., Goepfert, H., Lindberg, R. D., and Johnson, R. H.: Combined intra-arterial infusion of radiotherapy for the treatment of advanced cancer of the head and neck. *Am. J. Roentgenol.*, 1969, 105, 20—25.
2. Johnson, R. O., Ksiken, W. A., and Curreri, A. R.: Squamous cell carcinoma of the oral cavity. *Arch. Surg.*, 1965, 90, 760—763.
3. Berry, R. J.: Some observations on the combined effects of X-rays and methotrexate on human tumor cells »in vitro« with possible relevance to their most useful combination in radiotherapy. *Am. J. Roentgenol.* 1968, 102, 509—518.
4. Von Essen, C. F., Joseph, L. B. M., Simon, G. T., Singh, A. D., and Singh, S. P.: Sequential chemotherapy and radiation therapy of buccal mucosa carcinoma in South India. *Am. J. Roentgenol.*, 1968, 102, 530—540.
5. Friedman, M., and Daly, J. F.: The treatment of squamous cell carcinoma of the head and neck with methotrexate and irradiation. *Am. J. Roentgenol.*, 1967, 99, 289—301.
6. Langdon, E. A., Ottoman, R. E., Rochlin, D. B., and Smart, O. R.: Early results of combined radiation and chemotherapy in the treatment of malignant tumors. *Am. J. Roentgenol.*, 1963, 81, 1008—1013.