

Keratosi palmoplantari varians of Wachters in a patient with acanthosis nigricans and linear and whorled nevoid hypermelanosis

M.D. Pavlović, L.O. Kandolf, L. Zolotarevski and R.D. Zečević

SUMMARY

Keratosi palmoplantari varians of Wachters is a rare hereditary palmoplantar keratoderma with no associated disorders. The genetic basis of the disease is not yet known. We describe a man with this type of keratoderma associated with linear and whorled nevoid hypermelanosis and idiopathic-type acanthosis nigricans. The absence of these associated disorders in other family members affected by keratoderma suggests that there is no related genetic origin for the two conditions.

Introduction

The keratosi palmoplantari varians of Wachters or *keratosi palmoplantari areata et striata* (MIM no. 148 700) is a rare autosomal dominant palmoplantar keratosis originally described in 1920s independently by Fuchs, Brunauer and Siemens (1). In 1963 Wachters noted a great inter- and intrafamilial variability of the clinical features, and added the adjective *varians*.¹ In 1996, Lucker and Steijlen (2) reported a patient with both keratosi palmoplantari varians and keratosi palmoplantari punctata. This genodermatosis, more frequent in males, belongs to the nummular palmoplantar keratoses with no associated features, according to a classification put forward by Lucker et al (3). Linear and nummular circumscribed keratoses are localized to the palms and soles, and only rarely appear on the elbows, knees or Achilles tendons. Apart from mild palmoplantar

hyperhidrosis, no other associated features have been described in patients with Wachters' keratoderma (4).

Here we report an unusual case of keratosi palmoplantari varians (Wachters) associated with acanthosis nigricans and linear and whorled nevoid hypermelanosis.

Case report

A 39-year-old farmer was referred to our department for massive hyperkeratotic lesions on his palms and soles. On examination, thick yellowish keratotic plaques were seen mostly over the pressure points and lateral margins of his soles (Fig. 1). On the palms, hyperkeratotic papules and plaques in a linear arrangement were distributed over the thenar and hypothenar eminences, along volar as-

KEY WORDS

palmoplantar keratoderma Wachters, acanthosis nigricans, linear and whorled nevoid hypermelanosis

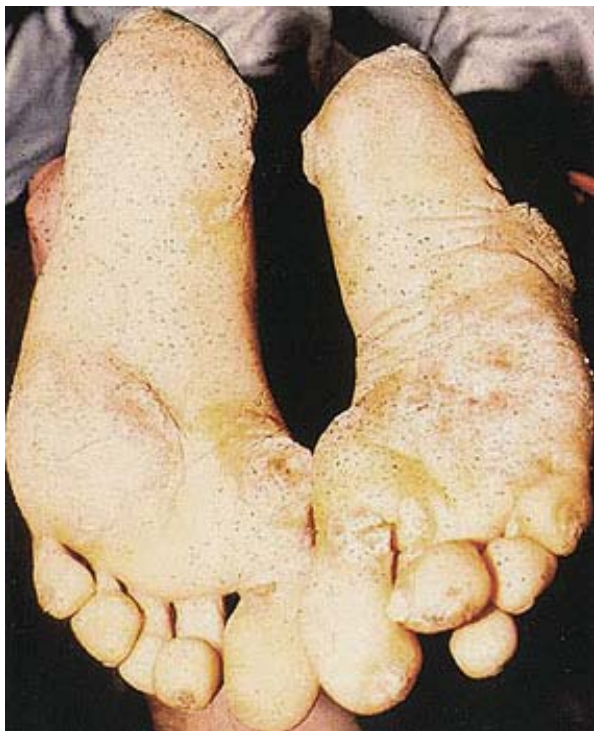

Figure 1. Nummular keratotic plaques on pressure points on soles.

pects of his fingers and the lateral margins of his index fingers (Fig. 2). The fourth and fifth fingers of the left and the third finger of the right hand presented no hyperkeratotic lesions. There were no nail involvement or dis-

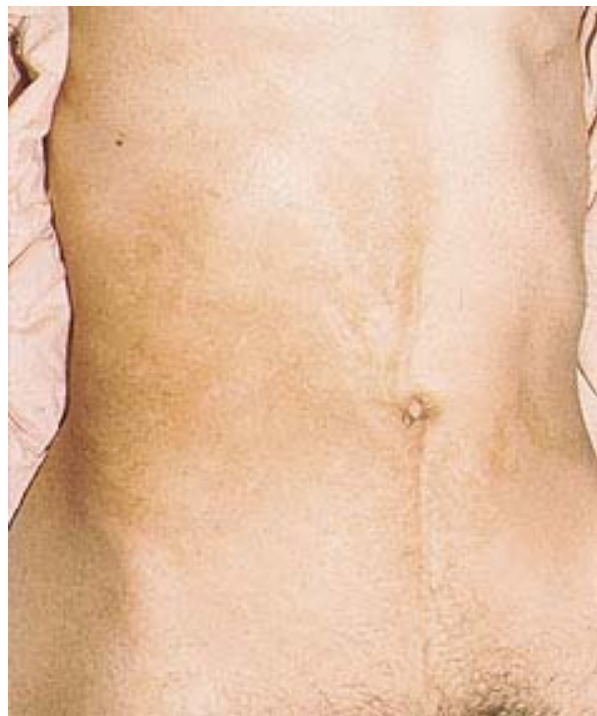

Figure 3. Streaks of hyperpigmented coalescing macules on the lateral trunk.

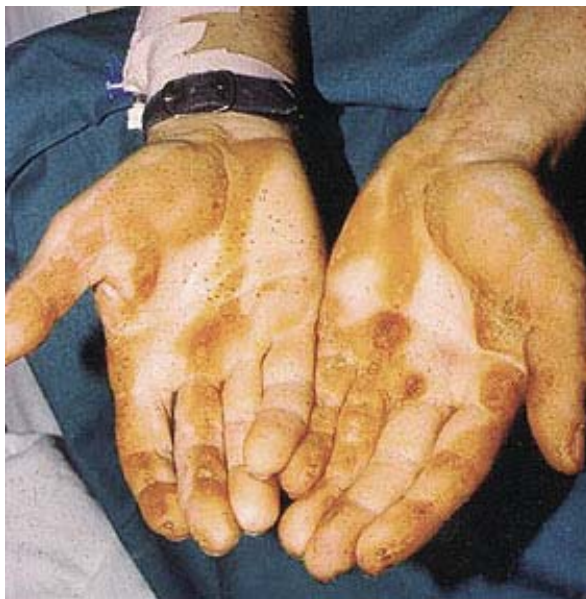

Figure 2. Linearly arranged lesions on hands.

tant keratotic changes. The lesions were painless but the patient complained of difficulties in extending fingers and wearing shoes. Hyperpigmented velvety papules coalescing into plaques could be seen in skin folds, including

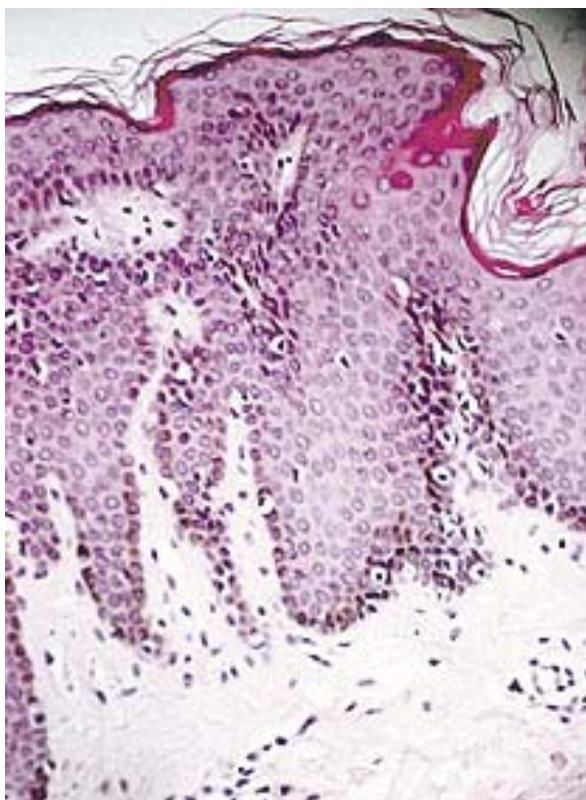


Figure 4. Biopsy specimen of a hyperpigmented macule showing a slight lentiginous hyperpigmentation of the basal layer of epidermis (original magnification H&E, x400).

the neck, axillae and groin. Dark-brown macules without surface alterations were seen distributed over his flanks and abdomen in the form of streaks, some of them clearly corresponding to Blaschko lines (Fig. 3). The remainder of the physical examination was unremarkable. The patient did not remember exactly when the lesions started to appear, and he only vaguely recollected that the keratotic and pigmentary changes were expressed when he was 3 or 4 years old. He had, however, noted the lesions in the skin folds around puberty. He denied the post-inflammatory nature of the hyperpigmentation. His father and father's nephew had nummular keratotic lesions only on their soles without other cutaneous changes.

Laboratory studies included complete blood cell counts, urinalysis, a panel of serum chemistry, serum glucose, oral glucose tolerance test, C-peptide and insulin levels. Results of all the tests were within a normal range. Histological examination of a skin biopsy specimen from his sole revealed profound orthohyperkeratosis, hypergranulosis and acanthosis. There were no epidermolytic hyperkeratosis nor any conspicuous dermal inflammatory infiltrate. The second biopsy was taken from the hyperpigmented area on the trunk. The specimen showed a mild (lentiginous) epidermal hyperplasia with a prominent melanin pigmentation and a slightly increased number of melanocytes within the basal layer of the epidermis (Fig. 4).

The hyperkeratotic hand and foot lesions were first removed mechanically, to be followed up with the application of keratolytic ointments. The patient was instructed to use the ointments regularly and pare the keratotic material off the affected skin.

Discussion

Keratosis palmoplantaris variants of Wachters is classified among the hereditary localized forms of nummular-linear type with no associated features (3). Nummular keratotic lesions on the sole, papular keratotic hand lesions arranged linearly, the onset in the early childhood, a positive family history with likely autosomal dominant inheritance, and the histological findings lead us to the conclusion that our patient was suffering from this rare type of palmoplantar keratoderma. The genetic basis of Wachters keratoderma is still not known. There is also no general agreement concerning the keratoderma of Wachters. While Griffiths et al consider it a separate nosologic entity (5), Braun Falco et al consider it as a striate palmoplantar keratoderma (6). Recently various mutations in genes coding for desmoglein 1, desmolakin and keratin 1 were found in some families with focal PPK (7). Thus both allelic and genetic heterogeneity may help to explain the clinical variability so typical for Wachters keratoderma, which is now definitely classified within focal PPKs (8). It is inherited as an autosomal dominant trait. In our case at least two other members of his family were affected with the keratoderma.

The two other cutaneous symptoms, acanthosis nigricans and epidermal hyperpigmentation, have not so far been described in patients with the Wachters keratoderma. The hyperpigmented macules distributed along the Blaschko lines correspond histologically to slightly increased melanocyte numbers and to an increased presence of melanin (Fig. 4). Cases of palmoplantar keratoderma associated with reticular pigmented dermatosis and macular hyperpigmentation have been described, the latter known as hyperkeratosis-hyperpigmentation syndrome (9-11). Neither hyperpigmentation nor palmoplantar keratoderma in our patient corresponded to these descriptions. Kalter et al. (12) described two cases of congenital, asymmetric, epidermal hypermelanosis with hyperpigmented macules appearing gradually after birth as streaks and whorls of macules or linear, reticulate whorls along Blaschko's lines. The process appeared to stabilize 6 to 12 months after birth. Histologic studies revealed increased epidermal melanocytes, irregular basal layer hyperpigmentation, and normal melanosomes. The authors have concluded that these and several similar case reports can be characterized by the onset at a few weeks of age, the sporadic involvement of males and females, evolution, then stability or fading after 1 to 2 years, asymmetric streaks and whorls along Blaschko's lines composed of 1- to 5-mm macules forming reticulated configurations, and sparing of mucous membranes, palms, soles, and eyes. There appears to be no incontinence of pigment or melanin accumulation in dermal macrophages. Congenital anomalies may be seen. Unfortunately, we could not elicit reliable data from our patient and his parents with regard to the precise time of onset of the pigmentary changes although they claimed that they had appeared when he was around 3 years of age. No congenital anomalies were present in our patient. Those of his family that are affected by keratoderma do not present pigmentary changes.

Acanthosis nigricans may represent a cutaneous marker of insulin resistance or malignancy, and may be drug-induced, idiopathic or associated with a number of syndromes (13). Despite a thorough search we could not find any underlying cause or association of acanthosis nigricans in our patient. According to laboratory results his disorder was not accompanied by detectable insulin resistance.

Conclusion

We presented a case study of a peculiar association of nummular palmoplantar keratoderma of Wachters type, linear and whorled nevoid hypermelanosis and acanthosis nigricans. The latter two conditions have not so far been reported as occurring together with Wachters keratoderma.

REFERENCES

1. Steijlen PM, Lucker GPH. Palmoplantar keratoses. In: Harper J, Oranje A, Prose N. Textbook of pediatric dermatology. Oxford: Blackwell Science, 2000: 1121-47.
2. Lucker GPH, Steijlen PM. Keratosis palmoplantaris varians et punctata. Klinische Variabilität eines einzigen genetischen Defectes? Hautarzt 1996; 47: 858-9.
3. Lucker GPH, Van de Kerkhof PCM, Steijlen PM. The hereditary palmoplantar keratoses: an updated review and classification. Br J Dermatol 1994; 131: 1-14.
4. Paoli S, Mastrolorenzo A. Keratosis palmoplantaris varians of Wachters. J Eur Acad Dermatol Venereol 1999; 12: 33-7.
5. Griffiths WAD, Judge MR, Leigh IM. Disorders of keratinisation. In Rook et al Textbook of Dermatology, Champion RH et al Eds, Blackwell, 1998, p.1563.
6. Braun Falco O, Plewig G, Wolf HH, Burgdorf WHC. Dermatology, 2nd ed., Springer, Berlin, 2000.
7. Arthur EA, Brod BA, Kantor GR. Palmoplantar keratoderma associated with dermatopathia pigmentosa reticularis: successful treatment with etretinate. Int J Dermatol 1995; 34: 645-6.
8. Kroll AL. Keratodermas. In Dermatology, Bologna JL, Jorizzo JL, Rapini RP eds. Osby, London 2003; 809-22.
9. Arthur EA, Brod BA, Kantor GR. Palmoplantar keratoderma associated with dermatopathia pigmentosa reticularis: successful treatment with etretinate. Int J Dermatol 1995; 34, 645-6.
10. Bu TS, Kim YK, Whang KU. A case of dermatopathia pigmentosa reticularis. J Dermatol 1997; 24: 266-9.
11. Figuera LE, Rodriguez-Castellanos MA, Gonzalez-Mendoza A, Cantu JM. Hyperkeratosis-hyperpigmentation syndrome: a confirmative case. Clin Genet 1993; 43: 73-5.
12. Kalter DC, Griffiths WA, Atherton DJ. Linear and whorled nevoid hypermelanosis. J Am Acad Dermatol 1988; 19: 1037-44.
13. Houpt KR, Cruz PD, Jr. Acanthosis nigricans. In: Freedberg IM, Eisen AZ, Wolff K, Austin KF, Goldsmith LA, Katz SI, Fitzpatrick TB, eds. Dermatology in General Medicine. New York, McGraw Hill, 1999: 2121-6.

A U T H O R S '
A D D R E S S E S

Miloš Pavlović MD, PhD, Assistant Professor, Dept Dermatology and Venereology, Military Medical Academy, Crnotravska 17, 11002 Belgrade, Serbia & Montenegro
Lidija O. Kandolf MD, MSc, same address
Lidija Zolotarevski MD, MSc, Institute of Pathology and Forensic Medicine, Military, same address
Radoš Zečević MD, PhD, Dept Dermatology and venereology, same address