

## **Prikaz primera**

### *Case report*

### ***Minilaparotomy for repair of ruptured abdominal aortic aneurysm. Case report***

## **Zdravljenje po rupturirani anevrizmi abdominalne aorte z minilaparotomijo: prikaz primera**

**Tomislav Klokočovnik**

Department of Cardiovascular Surgery, University Medical Center Ljubljana

Avtor za dopisovanje (*correspondence to*):

Klokočovnik T., dr. med., Department of Cardiovascular Surgery, University Medical Center Ljubljana, 7 Zaloška, 1000 Ljubljana, Slovenia; tel: + 386 15224941; + 386 41787902, fax: + 386 15224941, e-mail: tomi.klokocovnik@siol.net

Prispelo/Received: 11.2.2206

### ***Abstract***

*We report on a 56-year-old patient with ruptured abdominal aortic aneurysm (RAAA). Endoaneurysmorrhaphy using the minilaparotomy approach was used to reduce surgical trauma due to intraoperative bowel manipulation, and to prevent postoperative adynamic ileus that prolongs postoperative recovery. The patient's postoperative course was uneventful and he was discharged home on the 3<sup>rd</sup> postoperative day.*

**Key words.** *Minimally invasive technique, ruptured aortic aneurysm, minilaparotomy.*

## **Izveček**

Prikaz primera 56-letnega bolnika z rupturirano anevrizmo abdominalne aorte (RAAA). Operirali smo ga z novo, manj invazivno kirurško tehniko, minilaparotomijo. Pri takem operativnem pristopu zmanjšamo kirurško poškodbo tkiva, se izognemo manipulaciji črevesja in tako preprečimo pooperativni paralitični ileus, ki je pogost zaplet pri klasični operaciji RAAA. Pooperativno zdravljenje je potekalo brez zapletov in bolnik je bil odpuščen v domačo nego tretji dan po operaciji.

**Ključne besede.** Minimalna invazivna tehnika, rupturirana anevrizma abdominalne aorte, minilaparotomija.

## ***Introduction***

A standard median laparotomy affords good visualization of the abdominal aorta, and represents a gold standard for the RAAA repair (1). The so-called minilaparotomy, which we used in the patient with RAAA to reduce surgical trauma, provides good exposure of the operating field, similar to that afforded by the conventional procedure.

## ***Case report***

A 56-year-old man with a history of arterial hypertension was admitted to our institution in hypovolemic shock, with abdominal pain and general malaise. Physical examination revealed obesity (body weight 120 kg, height 182 cm, BMI 36.2 kg/cm<sup>2</sup>).

Doppler echography revealed a huge abdominal aortic aneurysm, greater than 10 cm in diameter, with an extraperitoneal haematoma. There was no time to perform a CT scan because of the aggravation of hypovolemic shock. The minilaparotomy technique was chosen in order to avoid intraoperative bowel manipulation and thereby reduce surgical trauma. The operation was done under general anaesthesia and with endotracheal intubation. A 10-cm incision made in the abdominal wall was held open with an abdominal retractor, and the bowel was retracted with abdominal compresses to expose the aorta. With this technique it is essential that the small bowel is held in the abdomen without traction. Then the retroperitoneum was incised above the aorta, and the neck of the infrarenal ruptured aneurysmal sac was exposed. After the administration of 5,000 units of heparin, the aneurysm was occluded

with standard De Bakey vascular clamps. Endoaneurysmorrhaphy was done using a 22-mm Vascutek tubular graft (Sulzer Vascutek Ltd.; Renfrewshire, Scotland, UK) (Figure 1).

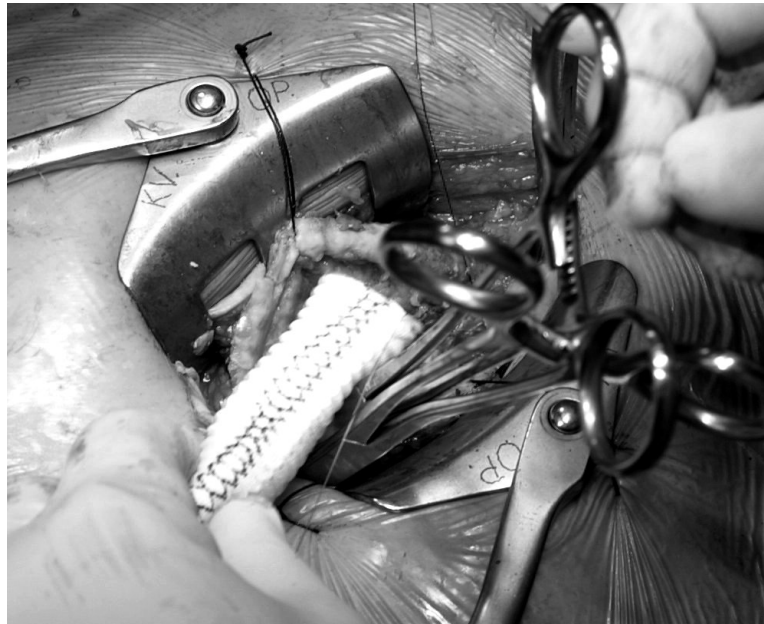
The mean occlusion time was 38 minutes. After incising the aneurysmal sac a parietal clot was removed, and the lumbar arteries were ligated. Then a tubular graft was sewn in place with continuous 2-0 Prolene suture. Clamps were released and blood was allowed to flow through the graft. The retroperitoneum was closed with continuous silk suture. No drainage tube was inserted into the wound. The wounds were closed in layers. The patient's postoperative course was uneventful. He was discharged home on the 3rd postoperative day.

## ***Discussion***

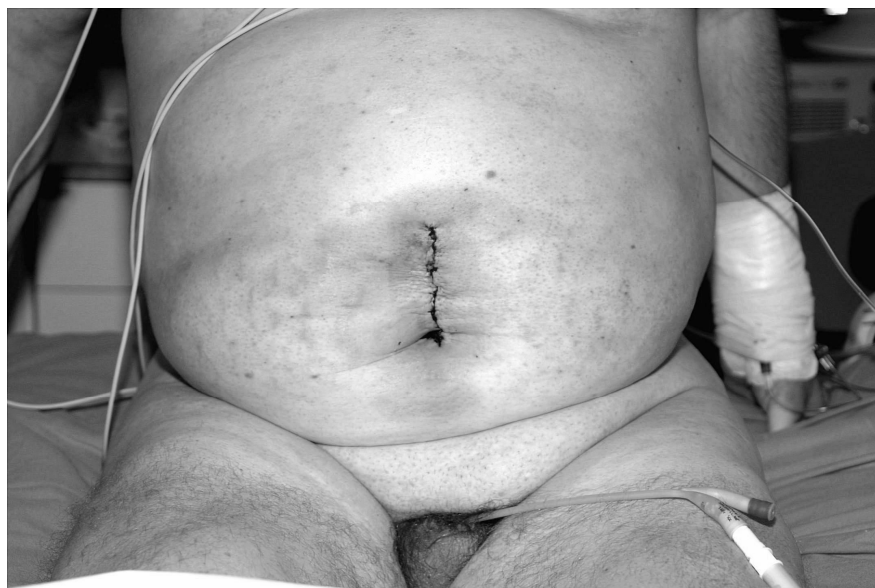The median laparotomy represents a gold standard for RAAA. It consists of an incision in the skin and fascia, approximately 30 cm long, and causes significant trauma with prolonged postoperative recovery (1,2). The long incision made in the skin and abdominal wall increases the risk of wound infection. Most patients develop postoperative adynamic ileus due to intraoperative extracavitary small-bowel retraction (3). This sequel markedly prolongs hospital stay and increases treatment costs. The minimally invasive approach for the treatment of abdominal aortic aneurysm and aortoiliac occlusive disease produces the same beneficial result as the standard median laparotomy (4,5). It provides good visualization of the surgical field, but affords slightly less maneuvering room to the operating surgeon. The postoperative scarring is minimal, similar to that resulting from much less extensive surgery

(Figure 2). The minilaparotomy approach can be used for the treatment of RAAA. The technique has so far been reserved for elective patients, but thanks to increasing surgeons' technical skills and because of its benefits for the

patient it would be reasonable to use it in emergency cases as well. The value of the minimally invasive approach for RAAA will have to be corroborated on larger series of patients.



**Figure 1**  
Minilaparotomy and Vasutec tubular graft



**Figure 2**  
The patient three days after operation

## *Literature*

1. Menard MT, Chew DKW, Chan RK, Conte MS, Donaldson MC et al. Outcome in patients at high-risk after open surgical repair of abdominal aortic aneurysm. *J Vasc Surg* 2003; 37: 285-93
2. Dardik A, Lin JW, Gordon TA, Williams M, Perler BA. Results of elective abdominal aortic aneurysm repair in the 1990s: a population based analysis of 2335 cases. *J Vasc Surg* 1990; 30: 985-5
3. Turnipseed WD. A less invasive minilaparotomy technique for repair of aortic aneurysm and occlusive disease. *J Vasc Surg* 2001; 33: 431-4
4. Klokocovnik T. Minilaparotomy for abdominal aortic aneurysm repair. *Tex Heart Inst J* 2001; 28: 183-5
5. Cerveira JJ, Halpern VJ, Faust G, Cohen JR. Minimal incision abdominal aortic aneurysmectomy. *J Vasc Surg* 2000; 32: 224-33