

Penetrantna poškodba torakalne aorte zaradi serijskega zloma reber

Delayed rupture of the descending thoracic aorta caused by penetrating intrathoracic injury from multiple rib fractures

Avtor / Author

Vojko Flis^{1,5}, Jože Antonič², Zvonko Borovšak³, Ivana Glumbić⁴,
Nina Kobilica¹

Ustanova / Institute

¹Univerzitetni klinični center Maribor, Kirurška klinika, Oddelek za žilno kirurgijo, Maribor, Slovenija, ²Univerzitetni klinični center Maribor, Kirurška klinika, Oddelek za torakalno kirurgijo, Maribor, Slovenija, ³Univerzitetni klinični center Maribor, Kirurška klinika, Oddelek za intenzivno terapijo, Maribor, Slovenija, ⁴Univerzitetni klinični center Maribor, Oddelek za patologijo, Maribor, Slovenija, ⁵Univerza v Mariboru, Medicinska fakulteta, Maribor, Slovenija,

¹University Medical Centre Maribor, Department of Vascular Surgery, Maribor, Slovenia,

²University Medical Centre Maribor, Department of Thoracic Surgery, Maribor, Slovenia,

³University Medical Centre Maribor, Intensive care unit, Maribor, Slovenia, ⁴University

Medical Centre Maribor, Department of Pathology, Maribor, Slovenia, ⁵University of Maribor, Faculty of Medicine, Maribor, Slovenia

Ključne besede:

topa poškodba toraksa, zlom reber, penetrantna poškodba aorte

Key words:

blunt thoracic trauma, rib fractures, penetrant injury to aorta

Članek prispel / Received

28.03.2011

Članek sprejet / Accepted

03.05.2011

Naslov za dopisovanje /**Correspondence**

Doc.dr. Vojko Flis, dr.med.

Univerzitetni klinični center Maribor,
Ljubljanska 5, SI-2000 Maribor,
Slovenija

Telefon +386 23211291

E-pošta: vojko.flis@guest.arnes.si

Izvleček

Namen: Poškodbe prsnega koša se pojavljajo pri 10–15 % vseh poškodb. Tope poškodbe prsnega koša, ki jih spremljajo serijski zlomi reber, so obremenjene z visoko obolevnostjo in umrljivostjo. Nestabilne zlome prsnega koša lahko zdravimo konservativno z ustrezno analgezijo, asistirano ventilacijo in čiščenjem bronhialnih izločkov. Toda takšno zdravljenje ne preprečuje poškodb, ki se lahko pojavijo zaradi zlomljenih reber, ki štrljo v prsno votlino. Štrleče konice reber na levi strani prsnega koša lahko poškodujejo torakalno aorto. Take poškodbe so značilne za paravertebralne serijske zlome reber, za katere zaenkrat ne obstaja varen in splošno sprejet način osteosinteze.

Abstract

Purpose: Thoracic trauma comprises 10–15% of all traumas. Blunt chest trauma is a major cause of morbidity and mortality, especially in the presence of flail chest. Chest-wall instability may be treated conservatively with analgesia, assisted ventilation and clearing of bronchial secretions. However, such treatment does not prevent additional injuries from broken ribs. It was thought that penetrating intrathoracic aortic injury after rib fractures was rare, but with emerging new cases the question of surgical stabilization of flail chest is reopened.

Case report: We describe a patient with flail chest injury on both sides who incurred a significant rib pen-

Poročilo o primeru: Prikazan je primer 68-letnega moškega z obojestranskim serijskim zlomom reber in nestabilnim prsnim košem. Poškodba je bila zdravljena z asistirano ventilacijo. Nekaj dni po poškodbi so zlomljena rebra v višini šestega in sedmega rebra levo predrila descendentno aorto in moški je umrl med oživiljanjem in prevozom v operacijsko dvorano zaradi hemoragičnega šoka.

Zaključek: Paravetebralni serijski zlomi reber na levi strani prsnega koša lahko povzročijo penetrantno poškodbo torakalne aorte. Za take poškodbe zaenkrat ne obstaja varen in splošno sprejet način osteosinteze.

etrating injury to the aorta days after the initial trauma. The thoracic surgeon did not decide on surgical fixation of the chest wall. Because of the flail chest, he remained intubated and mechanically ventilated. The patient was admitted to the ICU (Intensive Care Unit). The patient died after failed cardiac resuscitation during transportation to the operating room.

Conclusion: Although surgical fixation of flail chest segments can have potential advantages, there is no commonly accepted and safe procedure for fracture fixation of posterior rib fractures. A specific rib plate for posterior rib fractures that takes into account the structural properties and fixation constraints of ribs to reduce the prevalence of complications has yet to be constructed.

INTRODUCTION

Thoracic trauma comprises 10–15% of all traumas. Seventy percent of thoracic traumas are blunt and the remainder are penetrating injuries (1, 2). Blunt chest trauma is a major cause of morbidity and mortality, especially in the presence of flail chest (3); the therapeutic approach to flail chest has been extensively reported. Chest-wall instability may be treated conservatively with analgesia and clearing of bronchial secretions (4). However, the treatment of severe flail chest when respiratory failure develops, despite aggressive conservative management, remains controversial. Some authors advocate prolonged intubation and mechanical respiration (internal fixation) whereas others favour external stabilization by surgical repositioning and osteosynthesis of broken ribs (3, 5).

It has been argued that surgical stabilization of an unstable chest wall markedly reduces the duration of ventilatory support, duration of stay in the intensive care unit (ICU), and morbidity, as well as preventing post-traumatic restriction of the chest wall and pulmonary vasculature (3). Less attention has been paid to the advantages that early surgical stabilization may bring brought in terms of preventing additional injuries from broken ribs (6). It was thought that

penetrating intrathoracic aortic injury was rare after rib fractures (7–10). However, there are new, emerging cases (11, 12) that reiterate the need for an open discussion about the indications and potential advantages of surgical stabilization of the chest wall. There is no unanimous view on the indications for surgical stabilization of the chest wall. However, serious medical questions could emerge if the death of a patient occurs days after an accident where a known medical treatment potentially exists.

We describe a patient with flail chest injury who incurred a significant rib penetrating injury to the aorta days after the initial trauma. The patient died after failed cardiac resuscitation during transportation to the operating room.

CASE REPORT

A 68-year-old male was found under a tree in a crashed automobile. He had been trapped for a period of time. He was conscious (Glasgow Coma Scale –GCS– 14) with dyspnoea, complaining of right chest pain. His heart rate was 104 bpm and blood pressure was 86/60 mmHg. On clinical examination, deforma-

tion of the chest on the right side was seen. Breathing sounds were diminished bilaterally and subcutaneous emphysema was palpable over the entire posterior right side of the chest cavity.

On chest radiography, bilateral multiple rib fractures with flail chest were seen on the right side. Pulmonary contusion with haemothorax right and pneumothorax left and right were also described. A chest tube was placed on both sides. The patient was haemodynamically unstable and saturation was 92%. An abdominal ultrasound was normal and a spiral CT done. The investigation revealed fracture of the left femur and lumbar transverse processes fractures. Multiple rib fractures were also evaluated (Fig. 1).

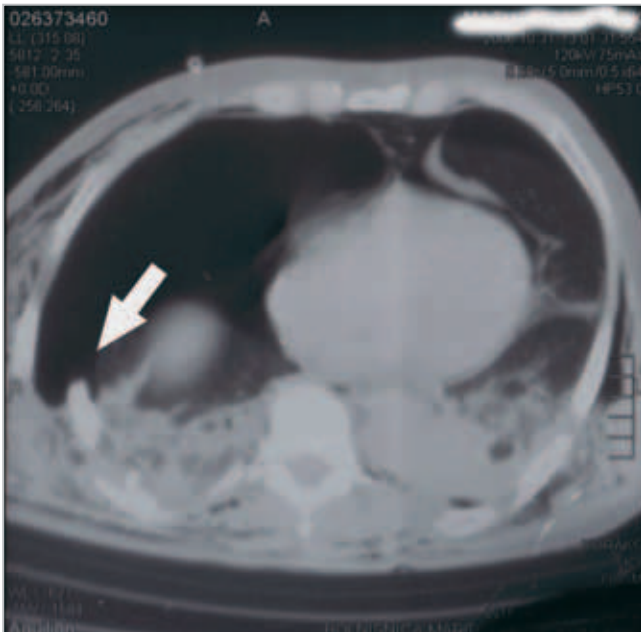


Figure 1. CT of the thoracic cage at hospital admission

The thoracic surgeon did not decide on surgical fixation of the chest wall. The patient was stabilized and internal fixation of the femur was carried out. Because of the flail chest, he remained intubated and mechanically ventilated. The patient was admitted to the ICU.

On days 1 and 2, the patient was haemodynamically stable. There were also signs of diminished hepatic function and kidney function. On day 3, there were

clinical and laboratory signs of developing sepsis. Antibiotics were added to therapy. He remained ventilator-dependent in the ICU. On day 8, after bed transfer and mobilization during CT examination, he became acutely unwell with significant haemodynamic compromise. The chest drain on the left side drained fresh blood (>1000 ml). The patient was resuscitated and rushed to the operating room. Cardiac standstill and circulatory collapse were noted in the operating theatre. The patient died soon after unsuccessful cardiac resuscitation.

Autopsy findings

The internal investigation revealed a punctuated rupture of the descending thoracic aorta at the level of the 7th rib on the left side. About 2000 ml of blood were found in the left thoracic cavity. Organ paleness consistent with exsanguination was observed. Fractures of the ribs were located on the right side of the chest in the scapular line from III to VIII, the mamillar line from II to VI, and in the paravetebral line from VI to IX. The 6th rib was fractured in three places and the 7th and 9th ribs were fractured in two places. On the left side, fractures were located from the 2nd to the 6th rib in the mamillar line and in the 7th to the 10th and the 12th rib in the paravertebral line (Fig. 2). The site of perforation was at the level of the 7th rib on the left side. There were no signs that it was an old perforation. All signs pointed to recent acute laceration of the thoracic aorta.

DISCUSSION

The strict definition of flail chest is fracture of at least four consecutive ribs in two or more places. A functional definition is an incompetent segment of chest wall large enough to impair respiration. Flail chest is a serious problem faced by patients with rib fractures because paradoxical chest movement causes a decrease in the vital capacity and therefore ineffective ventilation. This in turn results in pulmonary insufficiency. For the treatment of flail chest, surgical stabilization of the chest wall was introduced in 1960s. However, over the past two decades, volume-limited ventilation with internal pneumatic stabiliza-

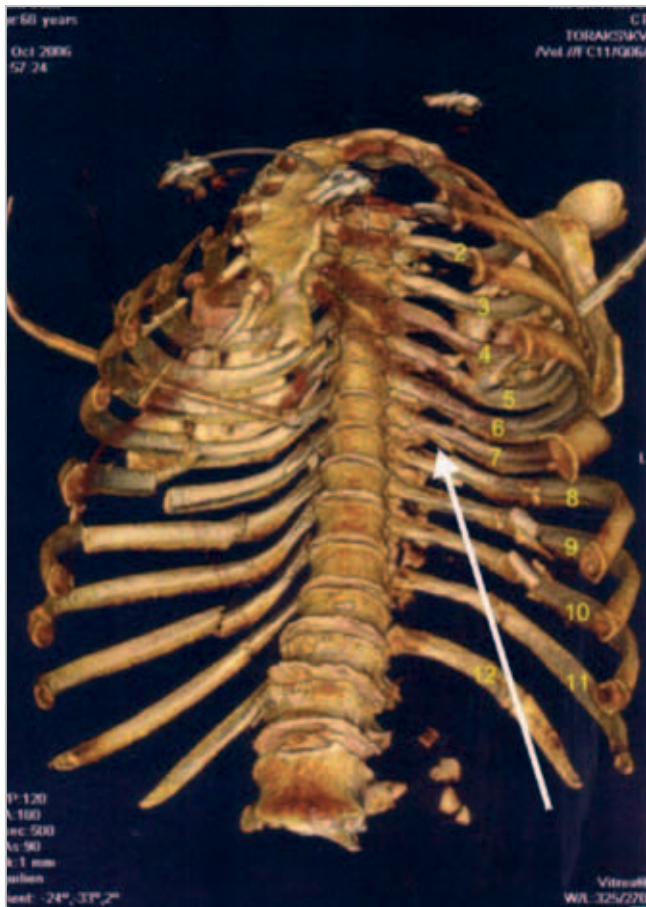

Figure 2. Three-dimensional CT reconstruction of the thoracic cage with broken ribs. Arrow denotes the location of the perforation.

tion has markedly reduced mortality and left surgical fixation usually for selected cases that need a thoracotomy for other reasons (1, 5, 14). Some authors argue that exception to conservative treatment may be found in selective cases if better cosmetic results are preferred (14).

However, the treatment of flail chest remains highly controversial for other reasons than cosmetic results (6, 15). Broken ribs within an unstable thoracic cage may extend the duration and extent of lung contusion and can lead to various accompanying thoracic injuries (6). Penetrating cardiopulmonary injuries with lung perforation, haemopericardium and cardiac contusion or perforation have been reported (6, 16, 17). The penetrating onset was usually not at the scene of the accident and may postpone hours or even days later

after none being concerned to the risks that are even aggravated by frequent bed transfer and mobilization.

Multiple rib fractures are important indicators of the severity of blunt trauma and occur in $\leq 10\%$ of cases admitted to Trauma Units. The likelihood of complications and other significant injuries increases with the increasing number of fractured ribs in the presence of flail chest (18). There is a recognized incidence of acute aortic penetrating injury secondary to fractured ribs (7–12). In all reported cases patients developed symptoms and signs of severe hypovolemia hours or even days after the accident. In 2 cases, complications occurred early after hospital admission (9, 10), and in the rest of the reported cases complications occurred days and even weeks after initial treatment (7, 8, 11, 12). Clinical and radiographic findings in each case were consistent with a new traumatic incident attributable to sharp lacerating surfaces of the broken ribs in the thorax, leading to penetrating injury of the thoracic aorta. The last 3 patients survived a secondary surgical procedure and repair of the aorta (11, 12), but some patients (including our case) died during transportation to the operating room. This raises the question that, if more aggressive management was undertaken, could the complications have been prevented? It may be argued that there is a small proportion of patients with such complications, but there is also a small proportion of patients with thoracic trauma and flail chest in whom surgical fixation is needed (19).

Indications for surgical stabilization of a flail chest are severe pulmonary restriction due to paradoxical movement of the flail chest segment, markedly overriding ribs, and severe instability and intrathoracic lesions which require thoracotomy (3, 6, 15, 20). However, the ideal indication and the timing for surgical intervention (early or secondary) remains controversial (20). The problems and risks of a surgical approach include the surgical trauma itself and the problems with fixation devices. Four categories of fixation devices for surgical fixation of the chest wall have been described: plates, intramedullary devices, vertical bridging and wiring. Special rib plates are

connected with loosening of the outermost screws, especially in osteoporotic ribs and because of a very low stiffness with unstable healing conditions (3, 21). Intramedullary devices provide little rotational stability and lack of secure fixation inside the canal can lead to wire migration (22). Various wiring and suturing techniques have been described (23, 24), but these techniques generally do not provide sufficient stability to the fracture (24). Various implants have been described that can bridge broken ribs (25, 26). These techniques do not accommodate the physiologic respiratory movement of the rib cage.

The common limitation to any plate design is the difficulty in stabilizing the posterior fractures that are the main cause of an immediate or delayed penetrating injury to the descending aorta. A general lack of commercially available plates for fixation of rib fractures

dictates the use of alternative plates with widely variable constitutive properties and uncertain outcome when used for posterior rib fractures (20).

CONCLUSION

In conclusion, although surgical fixation of flail chest segments can have potential advantages, there is no commonly accepted and safe procedure for fracture fixation of posterior rib fractures. A specific rib plate (especially for posterior rib fractures) that takes into account the structural properties and fixation constraints of ribs to reduce the prevalence of complications has yet to be constructed. However, the prognosis of such injuries with conservative treatment is poor, so there may be an advantage in a more aggressive initial approach despite the lack of specific fixation devices for posterior rib fractures.

REFERENCES

1. Sirmali M, Türüt H, Topçu S, Gülhan E, Yazici U, Kaya S, et al. A comprehensive analysis of traumatic rib fractures: morbidity, mortality and management. *European Journal of Cardio-Thoracic Surgery* 2003; 24(1): 133–8.
2. Poole, G., Fracture of the upper ribs and injury to the great vessels. *Surgery, Gynecology and Obstetrics* 1989; 169: 275–81.
3. Lardinois D, Krueger T, Dusmet M, Ghisletta N, Gugger M, Ris HB. Pulmonary function testing after operative stabilisation of the chest wall for flail chest. *European Journal of Cardio-Thoracic Surgery* 2001; 20: 496–501.
4. Lewis FJ, Thomas A, Schlobohm R. Control of respiratory therapy in flail chest. *Ann Thorac Surg* 1975; 20: 170–6.
5. Tanaka H, Yukioka T, Yamaguti Y, Shimizu S, Goto H, Matsuda H, et al. Surgical stabilization or internal pneumatic stabilization? A prospective randomized study of management of severe flail chest patients. *J Trauma* 2002; 52: 727–32.
6. Glinz W., Problems caused by the unstable thoracic wall and by cardiac injury due to blunt injury *Injury* 1986; 5: 322–6.
7. Kigawa I, Fukuda I, Fujii Y, Yamabuki K. A sharp edge of the fractured ribs caused the aortic injury at –body position change: a case report. *Kyobu Geka* 1992; 40: 1116–20.
8. Marco J, Gregory J. Posterior fracture of the left sixth rib causing late aortic laceration: case report. *J Trauma* 1997; 42: 736–7.
9. Hsu YP, Chen RJ, Bullard MJ, Fang JF, Lin BC. Traumatic thoracic aortic injury caused by a sharp edge of left fractured rib on body position change: case report. *Changeng Yi Xue Za Zhi* 1998; 21(3): 343–6.
10. Kern J, Chan BB, Kron IL, Young JS. Successful treatment of exsanguinating aortic injury from a fractured rib. *Am Surg* 1998; 64: 1158–60.
11. Iyoda A, Satoh N, Yamakawa H, Fujino M, Hiroshima K, Fujisawa K. Rupture of the descending thoracic aorta caused by blunt chest trauma: report of a case. *Surg Today* 2003; 33(10): 755–7.

12. Ashrafian H, Kumar P, Sarkar PK, DeSouza A. Delayed penetrating intrathoracic injury from multiple rib fractures. *J Trauma* 2005; 58: 858–9.
13. Thierauf A, Preuss J, Dettmeyer R, Madea B. Fatal rupture of an undiagnosed aneurysm of the splenic artery – Medico–legal implications. *Forensic Science International* 2007; 171(1):33–6.
14. Athanassiadi K, Gerazounis M, Theakos M. Management of 150 flail chest injuries: analysis of risk factors affecting outcome. *European Journal of Cardio–Thoracic Surgery* 2004; 26(2): 373–6.
15. Voggenreiter G, Neudeck F, Aufmkolk M, Obertacke U, Schmit–Neuerburg KP. Treatment outcome of surgical thoracic wall stabilization of the unstable thorax with and without lung contusion. *Unfallchirurg* 1996; 99(6): p. 425–34.
16. Glock Y, Roux D, Dalous P, Puel P. Embrochage ventriculaire gauche sur fracture de cote apres traumatisme derme thoracique: a propos dex cas. *Ann Chir* 1986; 40: 98–101.
17. Galvin I, Costa R, Murton M. Fractured rib with penetrating cardiopulmonary injury. *Ann Thorac Surg* 1993; 56: 558–9.
18. Lee RB, Bass SM, Morris JA jr, MacKenzie EJ. Three or more rib fractures as an indicator for transfer to a Level I trauma center: a population based study. *J Trauma* 1990; 30: 689–94.
19. Galan G, Penalver JC, Penalver F. Blunt chest injuries in 1696 patients. *European Journal of Cardio–Thoracic Surgery* 1992; 6: 284–7.
20. Engel C, Krieg JC, Madey SM, Long WB, Bottlang M. Operative chest wall fixation with osteosynthesis plates. *J Trauma* 2005; 58: 181–6.
21. Boetsch H, Rehm K. Biomechanische Untersuchungen an Rippenosteosynthesen. *Biomed Technik* 1981; 26: 296–301.
22. Ahmed Z, Mohyaddin Z. Management of flail chest injury: internal fixation versus endotrachela intubation and ventilation. *J Thorac Cardiovasc Surg* 1995; 110: 1676–80.
23. Albrecht F, Brug E. Zuggurtungsosteosynthese des Rippen und des Sternums bei instabiler Thoraxwand. *Zbl Chirurgie* 1979; 104: 770–6 .
24. Martin P, Godinou JC, Monod R, Cami M, Fleury JC, Leonardon P, et al. Costal stapling in severe thoracic trauma. *Nouv Presse Med* 1982; 11: 851–4.
25. Volkmer I, Krespis ESK. Der instabile Thorax, ein Beitrag zur operativen Behandlung. *Thoraxchirurgie* 1978. 26:275–9.
26. Sherman JE, Salzberg A, Raskin NM, Beattie EJ. Chest wall stabilization using plate fixation. *Ann Thorac Surg* 1988; 46: 467–9.