

Infliximab for treatment of resistant pyoderma gangrenosum associated with Crohn's disease

I. Ferkolj, A. Hočevár, R. Golouh, M. Dolenc Voljč

S U M M A R Y

We present the case of an 18-year-old woman with Crohn's disease manifested by diffuse abdominal pain, bloody diarrhea accompanied by arthralgia, and swelling of large joints. On the lateral aspect of her right ankle there was an hemorrhagic, necrotic bullous lesion measuring 3 × 4 cm, surrounded by cutaneous inflammation and erythema. Biopsy showed a neutrophilic abscess-like ulcerative skin inflammation, which was diagnosed as pyoderma gangrenosum. The patient was treated with high doses of parenteral methylprednisolone, but her condition failed to improve and infliximab, a TNF- α blocking agent, was instituted. An immediate response of Crohn's disease was observed and, over the next 5 weeks, the ulcer on her right ankle also healed completely.

Introduction

Pyoderma gangrenosum (PG) is a rare, probably immune-mediated ulcerating skin disease. In up to 50% of cases, PG is associated with an underlying systemic disorder, most commonly inflammatory bowel disease, connective tissue disease, or a hematological disorder (1). Therapeutic strategies have been based primarily on immunosuppressive therapy (2). Since the introduction of infliximab, a TNF- α blocking agent, in the treatment of various immune mediated diseases including Crohn's disease (CD), several retrospective reviews and studies have reported the efficacy of this biological therapy in PG as well (3).

We present a patient that developed PG as a complication of CD and was successfully treated with infliximab after all conventional therapy had proved

ineffective.

Case report

An 18-year-old woman with abdominal pain, bloody diarrhea, fever, and weight loss was diagnosed with CD in November 2003. Treatment with a combination of mesalazine and a short course of antibiotics (ciprofloxacin, metronidazole) resulted in a remission, which was maintained for nearly 2 years with low-dose mesalazine (800 mg t.i.d.). In September 2005, the patient developed a relapse, manifested by diffuse abdominal pain and bloody diarrhea (at least eight stools

K E Y W O R D S

pyoderma gangrenosum, Crohn's disease, infliximab

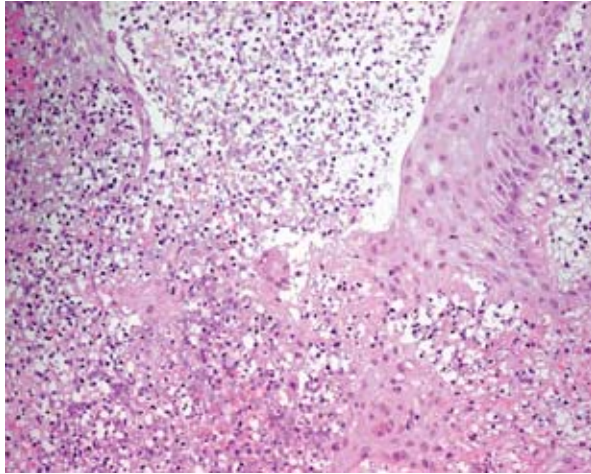


Figure 1. Epidermis and dermis with superficial necrosis and abscess formation.

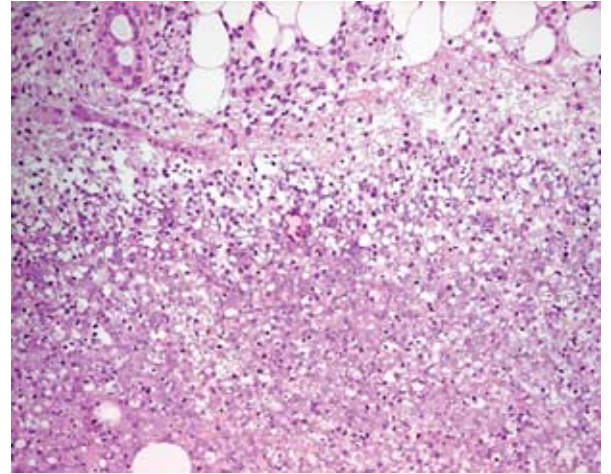


Figure 2. Acute necrotic focus within subcutaneous fat tissue.

per day) accompanied by arthralgia and swelling of large joints. After a month of unsuccessful corticosteroid therapy (methylprednisolone 40 mg daily) administered in an outpatient setting, she was admitted to our department.

On admission the patient was afebrile, and palpation of the left lower quadrant of her abdomen was painful. On the lateral aspect of her right ankle, there was a hemorrhagic, necrotic, bullous lesion measuring 1 × 2 cm, surrounded by cutaneous inflammation and erythema. The lesion had appeared 3 days before admission as a small painful papule. Biopsy (Figure 1, 2) showed an acute neutrophilic abscess-like ulcerative skin and subcutaneous inflammation, which was consistent with the diagnosis of PG. The patient was treated with parenteral methylprednisolone administered in

pulses of 500 mg each on 3 consecutive days, followed by oral methylprednisolone (60 mg/day) and azathioprine (150 mg/day). Her condition failed to improve. Because of persistent diarrhea she continued to lose weight (15 kg in 3 weeks), and the ulcer on her right ankle grew to the size of 3 × 4 cm and showed no signs of healing (Figure 3). After 3 weeks of the above immunosuppressive treatment, infliximab was instituted. It was administered according to the standard protocol, in a dose of 5 mg/kg given by infusion at weeks 0, 2, and 6. An immediate response was observed. A week after the first infusion, the patient left our hospital with no clinical signs of CD. Over the next 5 weeks, the ulcer on her right ankle healed completely (Figure 4). Since December 2005, infliximab has been administered at 8-week intervals in combination with azathioprine

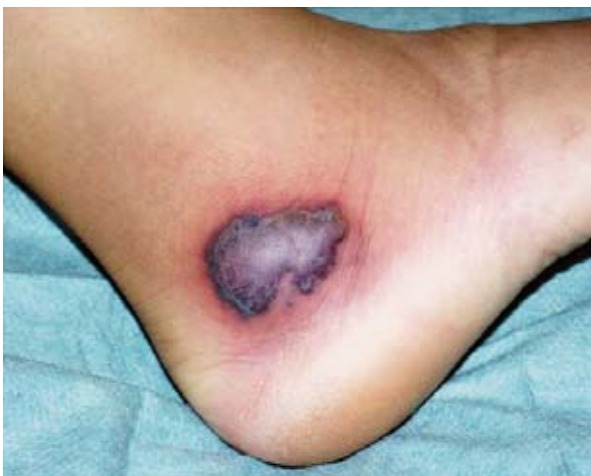

Figure 3. Pyoderma gangrenosum before treatment with infliximab.

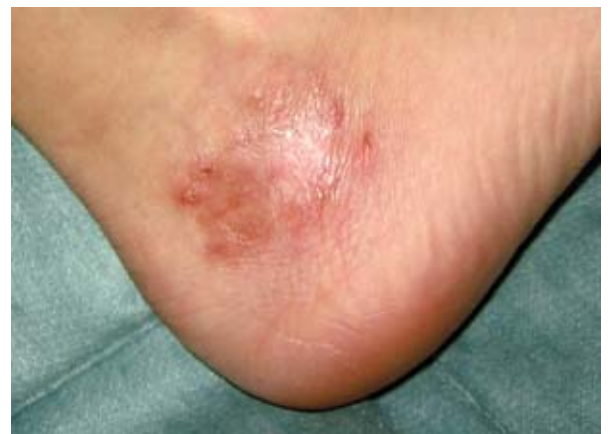

Figure 4. Pyoderma gangrenosum 6 weeks after the start of treatment with infliximab infusions (three doses).

(150 mg/day). At the time of reporting, both CD and PG are still in complete clinical remission.

Discussion

CD is a chronic inflammatory disease of unknown etiology, but an interplay of genetic, environmental, and immunological factors is crucial in its pathogenesis. Between 1 and 5% of patients with CD develop PG as an extraintestinal manifestation, which tends to occur mainly in colonic CD with penetrating complications (4, 5).

PG is a chronic noninfectious inflammatory skin lesion. Usually starting as a painful papule or pustule, it soon progresses to a rapidly expanding ulcer with undermined edges (6). The etiology of PG remains unknown, although an immunologically mediated pathogenetic mechanism has been hypothesized (7). The histological findings are also unspecific (8). Systemic immunosuppressive agents (glucocorticosteroids, azathioprine, cyclosporine, alkylating agents) are the mainstay of treatment but they are not always effective and their prolonged use may also be associated with significant side effects (2). Effective and safe treatment therefore remains a challenge.

Infliximab has been widely and successfully used for treatment of moderate to severe intestinal CD that

does not respond to first-line therapy. Recently, it has also been proposed for the treatment of extraintestinal manifestations of CD (3, 9).

In our patient both CD and PG responded dramatically to infliximab administration. We can only speculate to what extent the leg ulcer healed due to remission of the intestinal disease, and to what extent its resolution was due to the direct impact of infliximab on PG. However, the efficacy of infliximab as a treatment for PG has been demonstrated by molecular, biochemical, and clinical studies. Neutrophils are the main cells involved in attacking PG, and TNF- α seems to play a major role. It induces NF- κ B activation, augments neutrophil activation and chemotaxis through upregulation of chemokines and adhesion molecules, and induces reactive oxygen intermediate synthesis and lipid peroxidation (10). In addition, apoptosis of monocytes and activated T lymphocytes via the caspase pathway may be an important mechanism that could explain the powerful and sustained anti-inflammatory effect of infliximab in patients with chronic active CD (11, 12). Additional studies are needed to further clarify the relationships between PG, CD, neutrophils, and TNF- α .

In conclusion, treatment options for PG have greatly expanded with the introduction of TNF- α blocking agents. Our case report supports the use of infliximab as an alternative therapy for PG associated with CD when conventional treatment is ineffective.

REFERENCES

1. Crowson AN, Mihm MC Jr, Magro C. Pyoderma gangrenosum: a review. *J Cutan Pathol* 2003; 30: 97–107.
2. Reichrath J, Bens G, Bonowitz A, Tilgen W. Treatment recommendations for pyoderma gangrenosum: an evidence-based review of the literature based on more than 350 patients. *J Am Acad Dermatol* 2005; 53: 273–83.
3. Brooklyn TN, Dunnill MG, Shetty A, Bowden JJ, Williams JD, Griffiths CE, et al. Infliximab for the treatment of pyoderma gangrenosum: a randomised, double blind, placebo controlled trial. *Gut* 2006; 55: 505–9.
4. Menachem Y, Gotsman I. Clinical manifestations of pyoderma gangrenosum associated with inflammatory bowel disease. *Isr Med Assoc J* 2004; 6: 88–90.
5. Freeman HJ. Erythema nodosum and pyoderma gangrenosum in 50 patients with Crohn's disease. *Can J Gastroenterol* 2005; 19: 603–6.
6. Conrad C, Trueb RM. Pyoderma gangrenosum. *J Dtsch Dermatol Ges* 2005; 3: 334–42.
7. Su WP, Schroeter AL, Perry HO, Powell FC. Histopathologic and immunopathologic study of pyoderma gangrenosum. *J Cutan Pathol* 1986; 13: 323–30.
8. Hurwitz RM, Haseman JH. The evolution of pyoderma gangrenosum. A clinicopathologic correlation. *Am J Dermatopathol* 1993; 15: 28–33.
9. Rispo A, Scarpa R, Di Girolamo E, Cozzolino A, Lembo G, Atteno M, et al. Infliximab in the treatment of extra-intestinal manifestations of Crohn's disease. *Scand J Rheumatol* 2005; 34: 387–91.
10. Manna SK, Mukhopadhyay A, Aggarwal BB. Leflunomide suppresses TNF-induced cellular responses: effects on NF- κ B, activator protein-1, c-Jun N-terminal protein kinase and apoptosis. *J Immunol* 2000; 165: 5962–9.

11. Di Sabatino A, Ciccocioppo R, Cinque B, Millimaggi D, Morera M, Ricevuti L, et al. Defective mucosal T cell death is sustainably reverted by infliximab in a caspase dependent pathway in Crohn's disease. *Gut* 2004; 53: 70–7.
12. Shen C, Maerten P, Geboes K, Van Assche G, Rutgeerts P, Ceuppens JL. Infliximab induces apoptosis of monocytes and T lymphocytes in a human-mouse chimeric model. *Clin Immunol* 2005; 115: 250–9.

A U T H O R S ' A D D R E S S E S *Ivan Ferkolj, MD, PhD, Department of Gastroenterology, University Medical Centre, Division of Internal Medicine, Japljeva 2, 1000 Ljubljana, Slovenia, e-mail: ivan.ferkolj@kclj.si, corresponding author*
Alojzija Hočevar, MD, Department of Rheumatology, Medical Centre, Division of Internal Medicine, Vodnikova 62, 1000 Ljubljana, Slovenia
Rastko Golouh, MD, PhD, Department of Pathology, Institute of Oncology, Zaloška 2, Ljubljana, Slovenia
Mateja Dolenc Voljč, MD, PhD, dermatologist, Department of Dermatology, University Medical Centre, Zaloška 2, 1000 Ljubljana, Slovenia