

## Urticarial vasculitis reveals unsuspected thyroiditis

Olga Ferreira<sup>1</sup>✉, Alberto Mota<sup>1</sup>, Teresa Baudrier<sup>2</sup>, Filomena Azevedo<sup>2</sup>

### Abstract

A 38-year-old woman presented with erythematous, violaceous plaques with a serpiginous and unusual appearance located on the left shoulder, left thigh, and right buttock, evolving for 5 days, which eventually became generalized. A skin biopsy revealed leukocytoclastic vasculitis and a diagnosis of urticarial vasculitis was made. The complete blood count, biochemistry, complement levels, and other immunological test results were unremarkable. However, antithyroid antibody titers were increased. Despite having normal thyroid function tests and an absence of specific symptoms, the patient underwent a thyroid ultrasound, which revealed features of thyroiditis, and was subsequently referred to an endocrinologist. Several diseases can be associated with urticarial vasculitis, namely infections and autoimmune connective-tissue disorders such as systemic lupus erythematosus and Sjögren syndrome. Thyroiditis is an uncommon association.

Received: 16 December 2011 | Returned for modification: 3 February 2012 | Accepted: 28 February 2012

### Background

Urticarial vasculitis (UV) is a variant of leukocytoclastic vasculitis usually involving persistent hives. The normocomplementemic form usually follows a benign course and patients tend to have a skin-limited disease (1).

### Case report

A 38-year-old woman was referred to our department due to erythematous, violaceous plaques with a serpiginous appearance located on the left shoulder, left thigh, and right buttock, evolving for 5 days. Three days after first being noticed the lesions were widespread, sparing the face, palms, and soles, and an unusual pattern was evident (Fig. 1, Fig. 2).

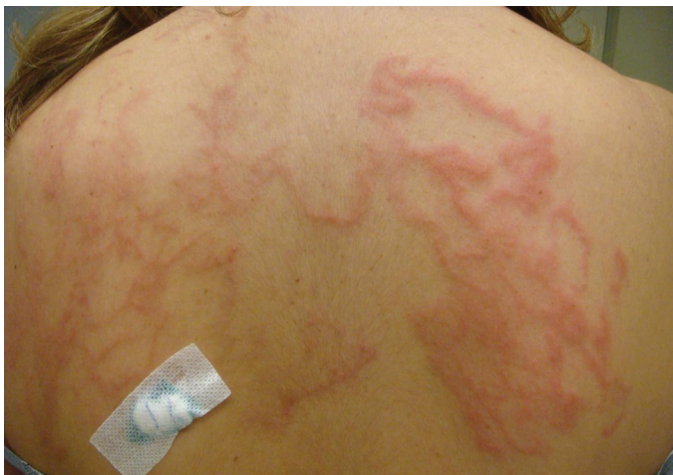

Figure 1 | Erythematous, violaceous plaques on the shoulders.

The patient denied joint, pulmonary, and gastrointestinal symptoms and also any recent drug intake. A skin biopsy was performed that revealed features of leukocytoclastic vasculitis with a predominant lymphocytic infiltrate (Fig. 3). The complete blood count, biochemistry, complement levels (C1q inhibitor-28mg/dL, C1q-20mg/dL, C3c-153mg/dL, C4-24mg/dL, C5-20mg/dL,

and CH50-238 UA), and other immunological tests (anti-nuclear, anti-DsDNA, anti-ENA, circulating immune complexes, and rheumatoid factor negative) were unremarkable and antithyroid antibodies were increased (antithyroglobulin-11.6UI/mL, antiperoxidase 50.2UI/mL). The patient was treated with prednisolone (1 mg/kg per day, slowly tapered) with resolution of skin lesions.

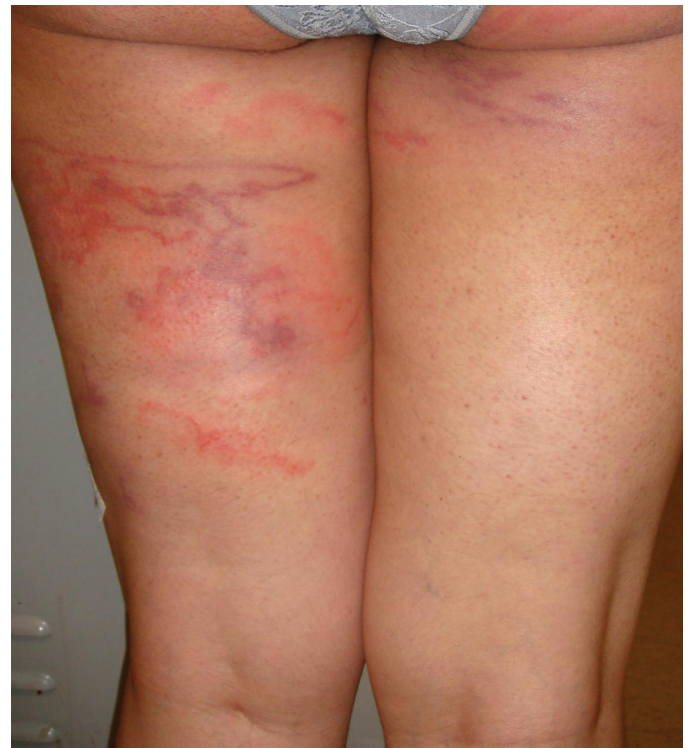

Figure 2 | Serpiginous lesions on the thighs.

Despite having normal thyroid function tests and an absence of specific symptoms, the patient underwent a thyroid ultrasound, which revealed features of thyroiditis, and was subsequently referred to an endocrinologist. A thyroid biopsy was not performed and the patient was assigned to regular follow-up with thyroid function within normal limits and elevated antithyroid antibodies.

<sup>1</sup>Department of Dermatology and Venereology, Centro Hospitalar de São João EPE and Faculty of Medicine of Porto, Porto, Portugal. <sup>2</sup>Department of Dermatology and Venereology, Centro Hospitalar de São João EPE, Porto, Portugal. ✉Corresponding author: ocsferreira@gmail.com

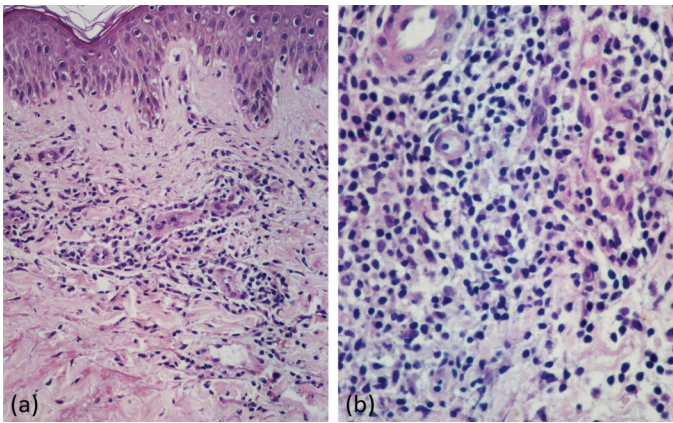


Figure 3 | Histopathology of lesion located on the shoulders (H&E: (a) 10 $\times$ , (b) 40 $\times$ ).

## Discussion

Classical urticarial vasculitis (UV) is described as an uncommon subset of chronic urticaria associated with leukocytoclastic vasculitis (2). It usually manifests as erythematous wheals resembling urticarial lesions lasting more than 24 hours (1–5), which may be accompanied by pruritus or more commonly by burning and painful sensations (1, 3). These lesions frequently resolve without residual changes, although hyperpigmentation or bruising may occur (6). Other skin lesions such as purpura, necrosis, ulcers, macular erythema, livedo reticularis, nodules, and bullae are rarely observed (1, 6). Frequently, cutaneous lesions are accompanied by systemic manifestations such as constitutional symptoms: arthralgia, arthritis or renal symptoms, and gastrointestinal, respiratory, ophthalmologic, or central nervous system symptoms and signs. Classical pathway complement levels divide UV into normocomplementemic (NUV) and hypocomplementemic (HUV) forms. Patients with NUV tend to have less frequent systemic involvement and a more benign prognosis than those with HUV, as was observed in our case (2).

UV diagnosis can be challenging because uncommon forms of presentation can occur; namely, erythema gyratum repens-like eruption (7). In our case, the patient showed a bizarre pattern of erythematous, violaceous plaques that on the first observation led us to suspect self-inflicted lesions or dermatitis factitia. However, skin biopsies were consistent with hypersensitivity vasculitis and therefore other differential diagnoses were excluded. Traditionally, the diagnosis of UV relies on urticarial lesions lasting longer than 24 hours and lesions that disclose histological features of leukocytoclastic vasculitis, with injury and swelling of endothelial cells, extravasation of erythrocytes, fragmentation of neutrophils with nuclear debris, and fibrin deposition in and around vessels (3, 4). Diagnostic biopsies should be performed on early lesions (3) because the infiltrate starts as a neutrophilic pro-

cess in the first 24 hours and is gradually replaced by a lymphocytic one after 48 hours (4). However, some authors believe that a lymphocytic infiltrate in association with endothelial swelling and extravasation of red blood cells with or without nuclear dust or fibrin deposition can be sufficient for the diagnosis of UV, as reported by Lee et al. in lesions less than 24 hours old (4). In addition to neutrophils, lymphocytes can also induce vessel damage, probably by cell-mediated cytotoxicity.

Although direct immunofluorescence (DIF) was not performed in our patient, it is a useful tool in the approach to leukocytoclastic vasculitis. DIF may reveal deposits of immunoglobulins, complements, or fibrin around blood vessels in the majority of patients with active lesions. Positivity for IgG and/or C3 is much more frequent in HUV than in NUV (1).

Management of UV is complex and, although this is most often an idiopathic condition (2, 3), other associated diseases must be excluded. Connective tissue disorders (systemic lupus erythematosus and Sjögren's syndrome in particular), infectious, hematologic and immune complex diseases, drugs, and malignancies have been reported in association with UV (1–3), but were ruled out in our patient. Laboratory results were within normal limits with the exception of antithyroid antibodies, and the patient was then submitted to a thyroid ultrasound despite normal thyroid function tests and an absence of specific symptoms. This exam revealed features of thyroiditis with subsequent referral to an endocrinologist.

If an underlying disease is identified, it should be the target of the initial treatment (1, 3). In our case, although thyroiditis was suggested by ultrasound, no special measures besides regular follow-up were implemented due to normal thyroid function. Some symptomatic relief may be provided, but oral antihistamines are rarely used as isolated agents due to poor responsiveness (1, 2). In this setting the use of oral corticosteroids is often needed, but long-term use of these drugs has a significant risk of side-effects (2). In fact, our patient was unresponsive to antihistamines and clinical remission was achieved through treatment with prednisolone (1 mg/kg per day, slowly tapered). No recurrence was observed in 1 year of follow-up. The lymphocyte-predominant type of UV demonstrated in our case may explain the good response to treatment. In this respect, it is interesting to observe that Lee et al. described in their series of patients that the lymphocyte-predominant group was normocomplementemic and experienced a good response to treatment. In contrast, the neutrophil-predominant group was often associated with hypocomplementemia and more recalcitrant disease behavior (4).

In conclusion, this case highlights the role of dermatological investigation in finding an otherwise unsuspected disease possibly associated with a bizarre presentation of urticarial vasculitis. Autoimmune thyroiditis is an uncommon association and it could be only a coincidental finding in our patient.

## References

1. Peroni A, Colato C, Zanoni G, Girolomoni G. Urticarial lesions: if not urticaria, what else? The differential diagnosis of urticaria: part II. Systemic diseases. *J Am Acad Dermatol.* 2010;62:557-70.
2. Tosoni C, Lodi-Rizzini F, Cinquini M, Pasolini G, Venturini M, Sinico RA, Calzavara-Pinton P. A reassessment of diagnostic criteria and treatment of idiopathic urticarial vasculitis: a retrospective study of 47 patients. *Clin Exp Dermatol.* 2009;34:166-70.
3. Chang S, Carr W. Urticarial vasculitis. *Allergy Asthma Proc.* 2007;28:97-100.
4. Lee JS, Loh TH, Seow SC, Tan SH. Prolonged urticaria with purpura: the spectrum of clinical and histopathologic features in a prospective series of 22 patients exhibiting the clinical features of urticarial vasculitis. *J Am Acad Dermatol.* 2007;56:994-1005.
5. Dincy CV, George R, Jacob M, Mathai E, Pulimood S, Eapen EP. Clinicopathologic profile of normocomplementemic and hypocomplementemic urticarial vasculitis: a study from South India. *J Eur Acad Dermatol Venereol.* 2008;22:789-94.
6. Wolf K, Goldsmith LA, Katz SI, Gilchrist BA, Paller AS, Leffel A. *Dermatology in general medicine.* 7th ed. New York: McGraw-Hill; c2008. Chapter 164, Cutaneous necrotizing venulitis; p. 599-606.
7. Dermitsu T, Sasaki K, Iida E, Azuma R, Umemoto N, Kakurai M, Yoneda K. Urticarial vasculitis presenting as erythema gyratum repens-like eruption. *J Eur Acad Dermatol Venereol.* 2009;23:215-7.