

A case of scar sarcoidosis developing in an old scar area on the forehead

Cengiz Kocak¹✉, Ergin Yücel², Nazlı Dizen Namdar³, Hasan Tak³

Abstract

Sarcoidosis is a multisystem disease characterized by noncaseating granuloma development. Scar sarcoidosis is a rare cutaneous form of sarcoidosis developing on previous cutaneous scar areas. The lesions may be solitary or occur along with systemic disease. We present the case of a female patient that developed cutaneous sarcoidosis in an old scar area on the forehead that was acquired 30 years ago due to injuries from a fall. Histopathological examinations of the excisional scar biopsy revealed non-necrotizing, noncaseating granulomatous inflammatory structures comprised of epithelioid cells and Langhans giant cells with lymphocytic infiltration within the reticular dermis consistent with sarcoidosis. High-resolution CT revealed bilateral mediastinal lymphadenopathy. Patients with inflammatory skin lesions at the sites of preexisting scars should be investigated for sarcoidosis. Histopathological examination of skin biopsy specimens usually provides the correct and final diagnosis.

Keywords: sarcoidosis, scar, case report

Received: 8 July 2015 | Returned for modification: 6 August 2015 | Accepted: 10 August 2015

Introduction

Sarcoidosis is a multisystem disorder characterized by the accumulation of lymphocytes and mononuclear phagocytes that lead to the development of noncaseating epithelioid granulomas (1). Sarcoidosis mostly affects the lungs, lymph nodes, liver, spleen, phalangeal bones, parotid glands, eyes, and skin. Cutaneous symptoms are common and may be the initial findings of a systemic inflammatory process. Cutaneous involvement in sarcoidosis is seen in 10 to 38% of patients with systemic disease (1, 2). Although non-specific cutaneous lesions are usually observed in the acute stage, specific cutaneous lesions are generally observed in chronic disease. Cutaneous lesions seen in sarcoidosis include papules, nodules, plaques, angiolupoid, ulcerative, and verrucous lesions, hypopigmented macules, lupus pernio, erythroderma, and granulomas in scars or areas subject to chronic trauma (3). Cutaneous sarcoidosis may occur in scar tissue. Scar sarcoidosis is a rare but specific form of cutaneous sarcoidosis. Old scar tissues are infiltrated with noncaseating epithelioid cell granulomas in scar sarcoidosis (4). We present a case of a female patient that developed cutaneous sarcoidosis in an old scar area on the forehead that was acquired 30 years prior due to injuries from a fall.

Case report

A 39-year-old female presented with localized nodular lesion of 2 months' duration in an old scar on the left side of forehead that she had acquired 30 years prior due to injuries from a fall. The patient's history was not significant. No dyspnea, night sweats, weight loss, or any other constitutional symptoms were present. Physical examination revealed a purplish-red nodular lesion with irregular borders 1 cm in diameter located at the old scar site on the left side of her forehead (Figure 1). The patient did not have any other anomalies on physical examination. Routine laboratory tests, including complete blood cell count, hepatic and re-

nal function tests, serum electrolytes, erythrocyte sedimentation rate, C-reactive protein, and serum and 24-hour urine calcium were within normal ranges. Chest radiography and high-resolution thorax CT (HRCT) demonstrated bilateral mediastinal multiple lymphadenopathies. Upper and lower abdominal CT were normal. The lesion was totally excised from the skin. For histopathological examinations, excisional specimens were fixed in 10% formalin, embedded in paraffin, and sectioned (thickness of 4 µm), and slides were stained with hematoxylin and eosin (H&E), periodic acid-Schiff (PAS), and Cluster of Differentiation 68 (CD68), and then examined under a light microscope (Olympus BX51, Tokyo, Japan). Disorganized, grayish-yellow multiple tissue samples were observed in the macroscopic examination of the excisional biopsy specimen. H&E staining of the specimen revealed non-necrotizing, noncaseating granulomatous inflammatory structures comprised of epithelioid cells and Langhans giant cells with lymphocytic infiltration within reticular dermis, consistent with sarcoidosis (Figure 2).

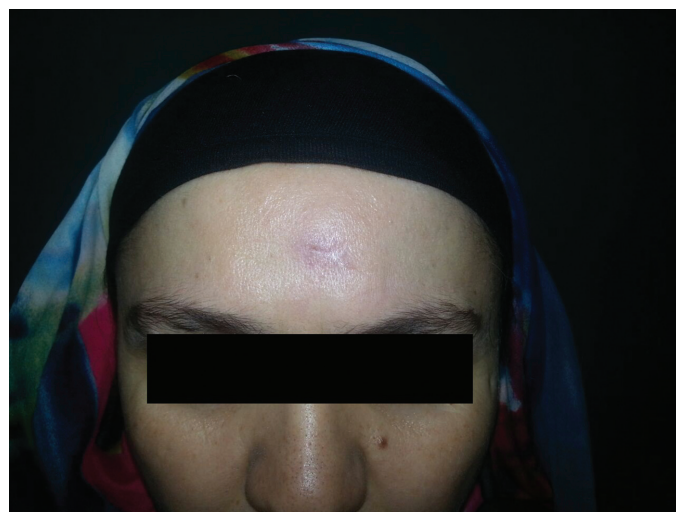

Figure 1 | Photograph of the patient showing a purplish-red nodular lesion with irregular borders located at an old scar on the left side of the forehead.

¹Department of Pathology, Faculty of Medicine, Dumlupınar University, Kütahya, Turkey. ²Department of Plastic Surgery, Evliya Celebi Education and Research Hospital, Dumlupınar University, Kütahya, Turkey. ³Department of Dermatology, Faculty of Medicine, Dumlupınar University, Kütahya, Turkey.
✉ Corresponding author: drcengizkocak@hotmail.com

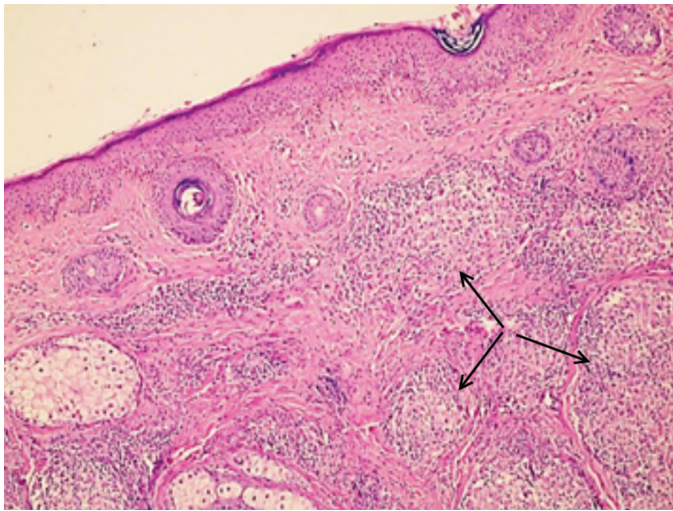


Figure 2 | Photomicrograph of the biopsy showing non-necrotizing, noncaseating granulomatous inflammatory structures comprised of epithelioid cells and Langhans giant cells with lymphocytic infiltration within the reticular dermis (arrow; H&E stain, $\times 100$).

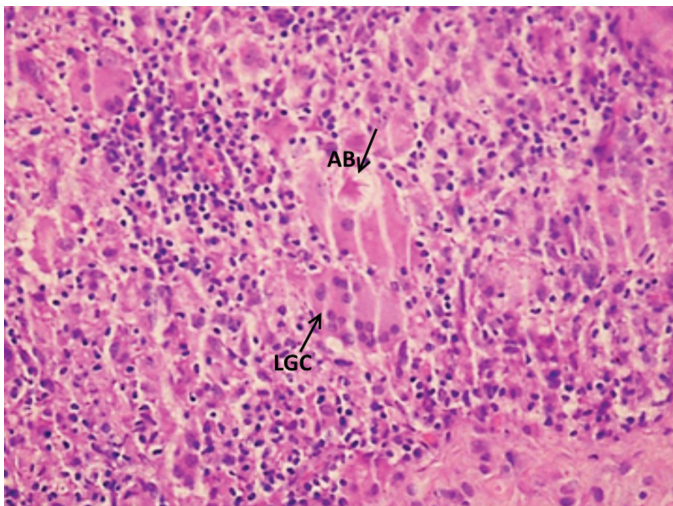


Figure 3 | Photomicrograph of the biopsy showing Langhans giant cells (LGC) containing asteroid bodies (AB; arrow; hematoxylin and eosin stain, $\times 400$).

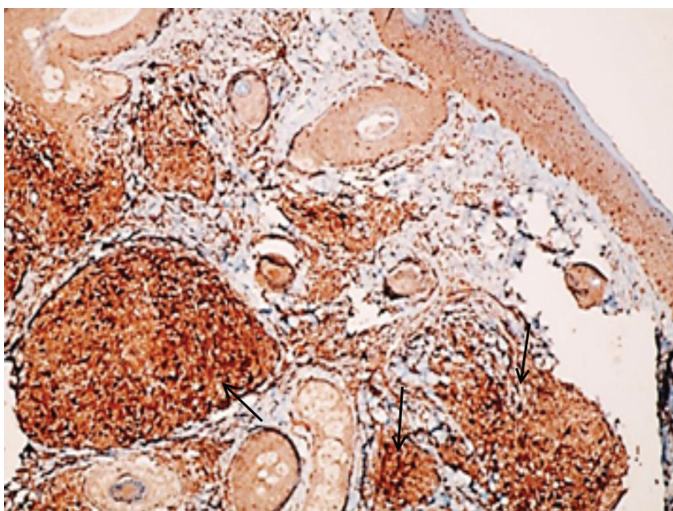


Figure 4 | Photomicrograph of the biopsy showing granulomas consisting of epithelioid histiocytes and Langhans giant cells (arrow; CD68 staining, $\times 100$).

The giant cells contained asteroid bodies characteristic of sarcoidosis (Figure 3). No organism was found with the special PAS staining. CD68 staining showed granulomas consisting of epithelioid histiocytes and Langhans giant cells (Figure 4). The patient was diagnosed with scar sarcoidosis with mediastinal lymph node involvement according to the results of histopathological

and radiological examinations. Local recurrence following excision occurred after 2 months. Re-excision was performed and local recurrence was not observed after the re-excision.

Discussion

Scar sarcoidosis is a rare form of cutaneous sarcoidosis developing on previous cutaneous scars. Scar sarcoidosis may occur in 5.4 to 13.8% of patients with cutaneous sarcoidosis (5). Scar lesions were seen in 2.9% of patients diagnosed with sarcoidosis in a previous study by Yanardag et al. (6). Although the pathogenesis of scar sarcoidosis is not known, it has been thought that the disorder may be due to previous contamination of the old scars with foreign bodies at the time of trauma. In addition, infiltration of an old scar by sarcoid tissue may result from a hypersensitivity reaction of the skin or erythema nodosum occurring at the time of sarcoid activity elsewhere in the body (4, 5). Descriptions indicate that the macrophages on phagocytosed foreign bodies may cause releases of angiotensin-converting enzymes and lymphokines, which lead to the development of granulomas (7). Although scar sarcoidosis may occur in scars from previous wounds, it has also been reported at the sites of tattoos, ritual scarification, desensitization injections, healed herpes zoster lesions, and venipuncture (5, 8–12). The cutaneous lesions may be solitary or occur along with the presence of systemic disease. A previous study reported that systemic involvement occurred in 30% of patients that had isolated cutaneous lesions after a period of 1 month to 1 year (5). Cutaneous sarcoidosis is frequently associated with involvement of hilar and mediastinal lymph nodes. Scar infiltration usually occurs early before involvement of the lung parenchyma (13). Our patient had skin involvement of scar sarcoidosis together with mediastinal lymphadenopathy, but there was no other systemic involvement of sarcoidosis. Scar sarcoidosis is characterized by recurrence of activity at the site of previous scar areas. The lesions initially occur as purplish red erythema and subsequently turn brown with an absence of itching. The diagnosis is based on consistent clinical and radiological findings associated with the histopathological presence of noncaseating epithelioid granuloma, as seen in our patient. (14). Specific lesions are characterized by the presence of granulomas of epithelioid cells without necrosis on biopsy specimens. Granulomas usually are seen in the superficial dermis but may involve the full thickness of the dermis and extend to the subcutaneous tissue. Langerhans giant cells may often be seen in clusters of epithelioid cells and Langerhans giant cells may contain asteroid bodies, which are star-shaped eosinophilic structures (15, 16). Differential diagnosis of scar sarcoidosis includes infectious skin diseases such as mycobacterium infections, Crohn's disease, rosacea, foreign body granuloma, and hypertrophic scar or keloid, which are the clinical mimickers (17). The treatment and prognosis of cutaneous sarcoidosis primarily depends on the degree of systemic involvement. Topical steroid therapy may sometimes be effective for solely cutaneous sarcoidosis (18).

Consequently, we report this as a rare case of scar sarcoidosis along with mediastinal lymph node involvement that developed on an old scar area. Patients with inflammatory skin lesions at the sites of preexisting scars should be investigated for sarcoidosis. If clinicians are unaware of the changes in old scars, scar sarcoidosis may be underdiagnosed. Histopathological examination of skin biopsy specimens usually provides the correct and final diagnosis.

References

1. Kerdel FA, Moschella SL. Sarcoidosis: an updated review. *J Am Acad Dermatol.* 1984;11:1-19.
2. Tchernev G. Cutaneous sarcoidosis: the “great imitator”: etiopathogenesis, morphology, differential diagnosis, and clinical management. *Am J Clin Dermatol.* 2006;7:375-82.
3. Chudomirova K, Velichkova L, Anavi B, Arnaudova M. Recurrent sarcoidosis in skin scars accompanying systemic sarcoidosis. *J Eur Acad Dermatol Venereol.* 2003;17:360-1.
4. Singal A, Thami GP, Goraya JS. Scar sarcoidosis in childhood: case report and review of the literature. *Clin Exp Dermatol.* 2005;30:244-6.
5. Mana J, Marcoval J, Graells J, Salazar A, Peyri J, Pujol R. Cutaneous involvement in sarcoidosis. Relationship to systemic disease. *Arch Dermatol.* 1997;133:882-8.
6. Yanardag H, Pamuk ON, Karayel T. Cutaneous involvement in sarcoidosis: analysis of the features in 170 patients. *Respir Med.* 2003;97:978-82.
7. Payne CM, Thomas RH, Black MM. From silica granuloma to scar sarcoidosis. *Clin Exp Dermatol.* 1983;8:171-5.
8. Landers MC, Skokan M, Law S, Storrs FJ. Cutaneous and pulmonary sarcoidosis in association with tattoos. *Cutis.* 2005;75:44-8.
9. Nayar M. Sarcoidosis on ritual scarification. *Int J Dermatol.* 1993;32:116-8.
10. Millet MS, Ziv R, Trau H, Zwas ST, Ronnen M, Rubinstein I. Sarcoidosis versus foreign body granulomas. *Int J Dermatol.* 1987;26:582-5.
11. Singal A, Vij A, Pandhi D. Post herpes-zoster scar sarcoidosis with pulmonary involvement. *Indian Dermatol Online J.* 2014;5:77-9.
12. Hancock BW. Cutaneous sarcoidosis in blood donation venipuncture sites. *Br Med J.* 1972;4:706-8.
13. Tanyildizi T, Kotan OS, Ozkaya S, Ersoz S, Gumus A. Skin sarcoidosis: a trick for primary case physicians. *Respir Med Case Rep.* 2012;5:49-50.
14. Caro I. Scar sarcoidosis. *Cutis.* 1983;32:531-3.
15. Gal AA, Koss MN. The pathology of sarcoidosis. *Curr Opin Pulm Med.* 2002;8:445-51.
16. Hsu RM, Connors AF Jr, Tomashefski JF Jr. Histologic, microbiologic, and clinical correlates of the diagnosis of sarcoidosis by transbronchial biopsy. *Arch Pathol Lab Med.* 1996;120:364-8.
17. Su O, Onsun N, Topukcu B, Ozcelik HK, Cakiter AU, Buyukpinarbasili N. Disseminated scar sarcoidosis may predict pulmonary involvement in sarcoidosis. *Acta Dermatovenerol Alp Pannonica Adriat.* 2013;22:71-4.
18. English JC 3rd, Patel PJ, Greer KE. Sarcoidosis. *J Am Acad Dermatol.* 2001;44:725-43.