

research article

Sialendoscopy and CT navigation assistance in the surgery of sialolithiasis

Aleksandar Anicin^{1,2}, Jure Urbancic^{1,2}¹ Department of Otorhinolaryngology and Cervicofacial Surgery, University Medical Center Ljubljana, Ljubljana, Slovenia² Faculty of Medicine, University of Ljubljana, Ljubljana, Slovenia

Radiol Oncol 2021; 55(3): 284-291.

Received 8 February 2021

Accepted 25 February 2021

Corresponding author: Assist. Prof. Aleksandar Aničin, Ph.D., M.D., Department of Otorhinolaryngology and Cervicofacial Surgery, University Medical Center Ljubljana, Zaloška 2, SI-1000 Ljubljana, Slovenia. E-mail: aleksandar.anicin@kclj.si

Disclosure: No potential conflicts of interest were disclosed.

Authors' contributions: Both authors contributed equally to the article.

This is an open access article under the CC BY-NC-ND license (<http://creativecommons.org/licenses/by-nc-nd/4.0/>).

Background. A sialendoscopy-assisted combined approach is well established in the surgery of sialolithiasis. In cases of proximal salivary stones, transcuteaneous sialendoscopy-assisted extractions with parotid and submandibular gland preservation is the primary intention of treatment. We recently added computer tomography (CT) navigation to improve the results of this challenging surgery equally in both localizations.

Patients and methods. All the patients who submitted to sialendoscopy and sialendoscopy-assisted procedures at the tertiary institution between January 2012 and October 2020 were included in the present study. From November 2019, CT navigation was added in cases with sialolithiasis and a presumably poor sialendoscopic visibility. We evaluated the parameters of the disease, diagnostic procedures, sialendoscopic findings and outcomes, with or without optical surgical navigation.

Results. We performed 178 successful salivary stone removals in 372 patients, of which 118 were combined sialendoscopy-assisted approaches, including 16 transcuteaneous proximal, 10 submandibular and 6 parotid stone operations. Surgical navigation was used in six patients, four times for submandibular and twice for parotid sialolithiasis. These were all non-palpable, sialendoscopically invisible or partially visible stones, and we managed to preserve five of the six salivary glands.

Conclusions. The addition of CT navigation to sialendoscopy-assisted procedures for non-palpable, sialendoscopically invisible and fixed stones is a significant advantage in managing sialolithiasis. By consistently performing sialendoscopy and related preservation procedures, we significantly reduced the need for sialoadenectomies in patients with obstructive salivary gland disease.

Key words: sialendoscopy; sialolithiasis; surgical navigation; computer tomography

Introduction

Sialendoscopy enables us to remove most salivary stones and, consequently, preserve salivary glands.^{1,2} In cases with a tortuous course of the salivary ducts, far proximal stone position and corresponding narrow duct diameter, or with stones located behind the stricture, deeply embedded or positioned in an abscess formation, even the use of sialendoscopy can be insufficient in determining the exact position of the stone. Transcutaneous

sialendoscopy-assisted combined stone removals with intended gland preservation are particularly demanding, and their outcome may be unpredictable. The ongoing search for an additional guiding system is therefore justified.³ Attempts to use ultrasound as guidance to help locate difficult salivary stones during surgery have been reported in previous years. However, its use is highly dependent on various factors, including the lack of direct stone visualization.⁴ Surgical navigation using a computer tomography scan (CT) is regularly used in an-

terior skull base and paranasal sinus surgery with high precision.⁵ Under clinical conditions, an accuracy of about 2 mm is expected.⁶ It has been applied in various other therapeutic scenarios, including electrochemotherapy of deep-seated tumors in the head and neck region.⁷ Following experiences reported by Capaccio *et al.*,⁸ we therefore added CT-based navigation to the demanding combined approach to stone extractions to improve our results. To the best of our knowledge, we describe the first series in which navigation was used to locate the salivary stones and present it in the context of other endoscopic and combined salivary stone removals.

Patients and methods

Data were prospectively collected in an institutional sialendoscopic database. On the proposal of the European Sialendoscopic Training Centre (ESTC), the database is a common source of data on imaging results before sialendoscopy, the exact indications for these procedures and their type, the procedure's findings, and follow-up.^{9,10} All patients signed written consent for the respected procedure and data collection according to hospital policy.

Ultrasound diagnostics

Ultrasound examination was carried out in all patients to evaluate major salivary glands and their ductal systems and to detect any ultrasonographically visible salivary stones and to exclude possible tumor growth.

Mandibular occlusal radiography

We used mandibular occlusal radiography as a standard native X-ray method with a good sensitivity for radiopaque alterations of the floor of the mouth, including salivary calculi.¹¹

Computer tomography

The CT scan was primarily used to display more precisely the localization and number of salivary stones. Secondly, the use of CT enabled an estimation of the glands, their ducts and surrounding tissues. We performed contrast-enhanced CT in all cases of relapsing/persistent or complicated sialolithiasis, in order to show salivary stones, their embedded or even extraluminal position and possible abscess formation or other soft tissue formations related to sialolithiasis with a more chronic course.

Magnetic resonance sialography

Standard and magnetic resonance imaging (MRI)-based sialography were used in sialendoscopically identified impassable distal strictures. We occasionally added standard MRI to estimate the status of glandular parenchyma.

X-ray sialography

Conventional sialography is performed by retrograde injection of contrast agents into the salivary duct. The procedure involves instrumenting the duct for its cannulation and the possibility of injury or irritation. Although rarely used since other techniques have been readily available, in skilled hands, it produces characteristic imaging of the ductal anatomy, pathology (strictures and dilations) and adjacent parenchymal pathology.¹²

Surgical navigation

After the workup described above, we performed sialendoscopic and sialendoscopy-assisted procedures. Our database was reviewed for less than sufficient endoscopic exposition in purely endoscopic and combined procedures from January 1st 2012 to October 31st 2020. We compiled the criteria for the use of the CT navigation listed in Table 1. CT navigation was added from November 2019 in all planned combined sialendoscopy-assisted surgery cases if three or more inclusion criteria were met.

A CT scan of the facial and salivary structures was done one day before surgery with 4 or 5 radiopaque surface fiducial markers (Figure 1). They were placed directly on the skin. Their position was additionally marked with a waterproof skin marker. The exact position was chosen according to the planned approach and incision placement. It has to be emphasized that the arrangement should preferably be on hard anatomical parts of the

TABLE 1. Inclusion criteria for the use of CT navigation (if three or more criteria were met)

Non-palpable stone
Difficult or impossible sialendoscopic visualization of the stone
Far proximal stone
Presumably fixed stone
Extraluminal stone (in an abscess or deeply embedded)
Salvage procedure with previously failed sialendoscopy or sialendoscopy-assisted procedure

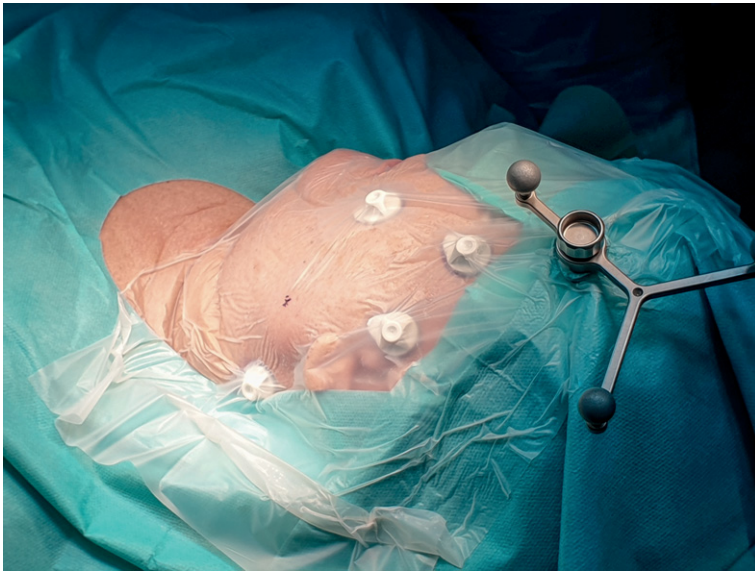

FIGURE 1. Patient, prepared for surgery. With fiducial markers attached to the skin and navigational star on the patient's forehead (BrainLab, Munchen, Germany).

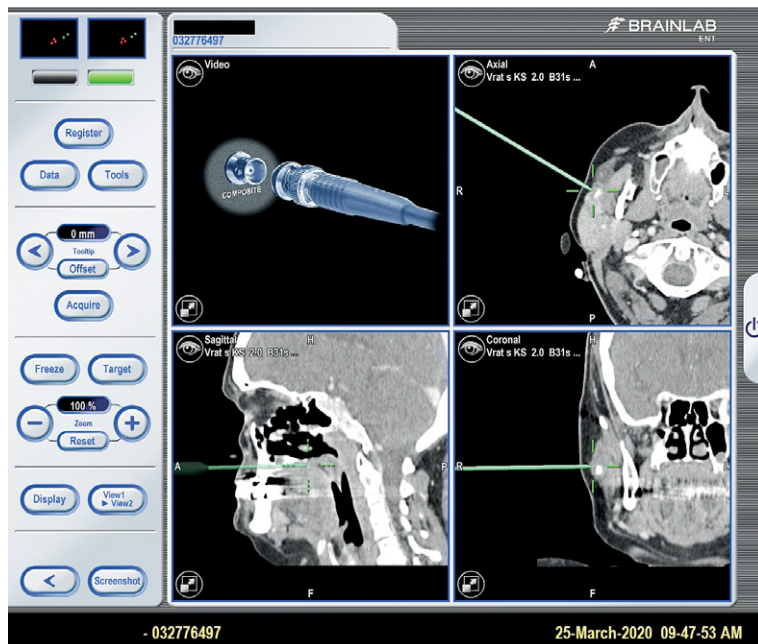


FIGURE 2. After identifying the skin's reference point with the stone being visible in the three-axis, the surgical trajectory is checked by the navigation.

face. Differences in jaw angle during CT imaging and when the patient is under general anesthesia were avoided by using a standard dental mouth gag in both situations. Acquired data in standard digital imaging and communication in medicine (DICOM) format were transferred to navigation Brainlab Kolibri (Brainlab, Munchen, Germany). Fiducial markers were automatically recognized

by the navigation software (Brainlab Cranial ENT V 2.1). No additional ad-hoc markers were chosen. The registration was done by touching the markers only. When the system perceived their order as ambiguous, the navigation itself chose the appropriate registration points sequence. When at least medium precision was achieved (self-assessment of the system), we checked the position of known anatomical landmarks and reconfirmed the accuracy to the surgeon's preference.

The first goal was to find the salivary stone's external approach path with the navigational tool lightly pressed on the skin. Since the CT presentation is divided into axial, coronal and sagittal planes, the surgeon must see the stone on all the planes. The trajectory may only then be approved. Both authors approved the trajectory before the continuation of the procedure. The contact point on the skin was marked as point zero, and the angle of the instrument was checked by both surgeons.

After incision and careful preparation, special care was taken not to change the position of the lower jaw. It can change the navigation accuracy when dealing with submandibular pathology; the same mouth gag in the same position was therefore used again.

The orientation axis is an imaginary line from point zero on the skin to the deep-seated stone (Figure 2). During the dissection, the surgeon is virtually travelling through tissue on the same three-dimensional pathway from a stone's skin reference point. When necessary, an additional sialendoscopic approach was made to control the position of the stone. It also represented backup guidance in the final approach to the stone (Figure 3). Stones were removed through transcutaneous (Figure 4) or transoral incisions. Routine facial nerve neuromonitoring (Medtronic, Jacksonville, USA) was used in all transcutaneous procedures. Data analysis and statistics were done using Microsoft Excel 2019 (Microsoft, Redmond, USA) and SPSS V20.0 (IBM, Armonk, USA).

The study was approved by the institutional Committee for Medical Ethics and the Slovene National Medical Ethics Committee approved data collection and review of outcomes (0120-80/2017/4). The study was performed according to the principles of the Helsinki Declaration.

Results

Three hundred and seventy-two patients underwent a sialendoscopic approach for treating obstructed

tive salivary gland disease, of which 179 (48.12%) were female and 193 (51.88%) male, with an average age of 48 years (median 47.5 years) and an age span from 4 to 84 years. We performed 415 sialendoscopic and sialendoscopy-assisted procedures, roughly in two thirds because of submandibular pathology (273 operations or 66%). The essential data on the patients and sialendoscopic operations at the Department of Otorhinolaryngology and Cervicofacial Surgery January 2012 – November 2020 are shown in Table 2.

Ultrasound diagnostics

In the present group, ultrasound examination proved accurate in evaluating the salivary glands' morphology and identifying stones, their size and localization, or possible dilatation of the ducts. In eight cases, ultrasound missed diagnosing rather long but narrow salivary stones (longer diameter of 8–10 mm and transverse diameter of 2–3 mm), which were all localized in the last distal 2 cm of Wharton's duct. We diagnosed these stones during sialendoscopy, four of them also by palpation in the office. Among 182 ultrasonographical examinations of submandibular glands, these eight cases resulted in a 4.4% false-negative rate.

Mandibular occlusal radiography

Native mandibular occlusal radiography proved useful, showing a Wharton's duct salivary stone in 12 out of 17 examinations, five of them being non-palpable. In one patient, the examination revealed an osteoma of the mandible.

Computer tomography

CT imaging was used in 143 patients (38.5%), mostly with sialolithiasis (122 patients or 85.31%). The proportion of all patients with sialolithiasis in whom a CT examination was performed was 62.24% (122/196). The percentage has been higher in the last four years (84.5%).

MR sialography

MRI sialography was used in eight patients with sialendoscopically identified tight proximal strictures: four of them at a 30–45 mm depth of Wharton's duct and in the same number of patients with Stensen's duct strictures and a 50–60 mm endoscopic reach. A typical examination showed a sausage-like series of strictures and dilatations or

TABLE 2. Patients and sialendoscopic operations at the Department of Otorhinolaryngology and Cervicofacial Surgery, University Clinical Center Ljubljana, Slovenia, January 2012 – November 2020

All operations		415 (100%)
Operated salivary ductal system	Submandibular	273 (66%)
	Parotid	142 (34%)
Anesthesia	Local	302 (72.8%)
	General	113 (27.2%)
Patients	All	372
	Male	193 (51.8%)
	Female	179 (48.1%)
Radiology diagnostics	Age (average, span – in years)	48 (4–84)
	Ultrasound	372 (100%)
	Mandibular occlusal radiography	17 (4.6%)
	CT	143 (38.4%)
	MR sialography	8 (2.2%)
The type of interventional procedure	X-ray sialography	2 (0.5%)
	All	247
	Salivary stone extraction	178
	Stricture dilatation	69
	Stent insertion (after stricture dilatation or stone extraction)	145

long segments of the main and secondary duct strictures.

X-ray sialography

Sialography was used in only two patients with tight distal strictures of Stensen's duct since

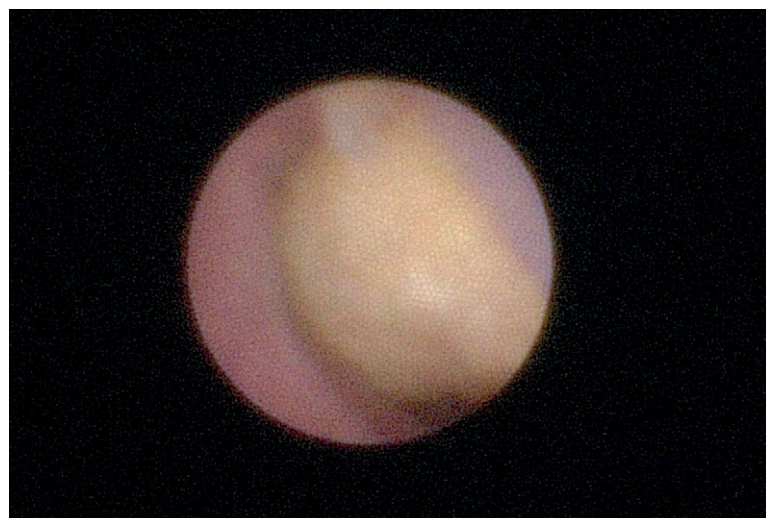


FIGURE 3. In case the stone is at least partially sialendoscopically visible, it can represent a backup guidance in a challenging final combined approach.

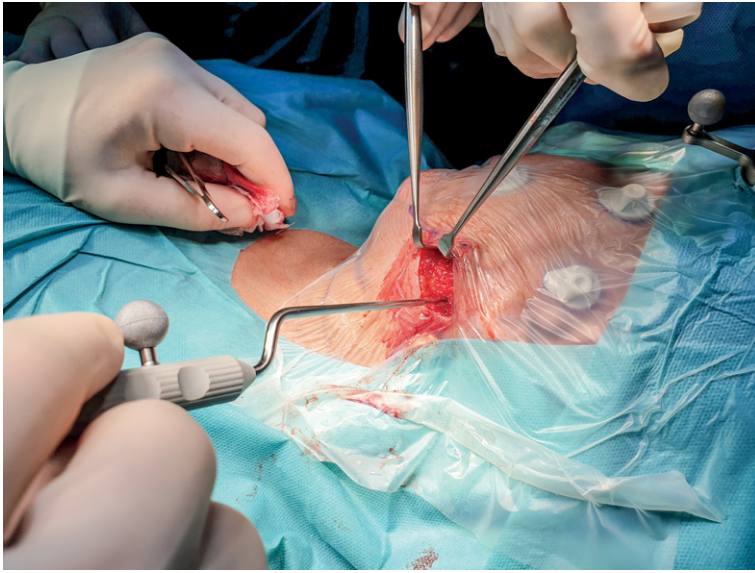


FIGURE 4. All stones were removed following the navigational trajectory with a transcutaneous or transoral approach.

TABLE 3. Sialendoscopy-assisted transcutaneous salivary stone extractions with or without the use of navigation at the Department of Otorhinolaryngology and Cervicofacial Surgery, University Medical Centre Ljubljana, Slovenia

Gland / Stone extraction outcome	Parotid gland	Submandibular gland	Total
Successful	4	6	10
Successful (with navigation)	2	3	5
Successful last attempt wire basket retrieval (transcutaneous approach failed)		1	1
Total	6	10	16

10.2.2012, when sialendoscopy was introduced in our department. The examination proved to be accurate, showing sausage-like series of strictures and dilatations. It also has apparent drawbacks, such as the need for cannulation and engagement of two teams (radiological and surgical). Damage to the duct can also be probable. We found one case with a ruptured stenotic segment 40 mm from the papilla.

Types of anesthesia, procedures and use of additional tools

The majority of our sialendoscopies and sialendoscopy-assisted operations were performed under local anesthesia (302/415; 72.77%) and were well-tolerated. There were eight recorded cases of transient paresis of the buccal branch of the facial

nerve after parotid sialendoscopy, lasting from 3 to 6 hours; no other adverse reactions to local anesthesia were recorded. We performed 247 interventional procedures (59.5%), with 178 successful salivary stone extractions and 69 stricture dilations. A total of 145 temporary stents were inserted in these cases. In 168 cases (40.5%), no intervention procedure was carried out.

Surgical approach and outcomes

The essential data on the patients and sialendoscopic operations at the Department of Otorhinolaryngology and Cervicofacial Surgery January 2012 – November 2020 are shown in Table 2.

Pure sialendoscopic stone removal was performed in 60 patients, and additional laser fragmentation was used in 8 (13.3%) of them. The combined sialendoscopy-assisted approach was the most common method of salivary stone extraction (118/178 procedures, 66.3%). The majority of the combined approach operations were performed through incisions of the oral mucosa (102 surgeries, 86.4%), mainly for the removal of submandibular stones (93 cases, 91.2%). A transcutaneous approach was employed in the remaining 16 procedures, in 10 of them using a transcervical approach (for submandibular stones) and six a transfacial approach (for parotid stones) (Table 3).

A salivary gland resection was performed in six out of 372 patients in whom sialendoscopy was part of their treatment.

A combination of sialendoscopy and navigation was used in six patients, four of them with submandibular and two with parotid stones (Table 4). Depending on their proximity along the duct, we used transcutaneous approaches in five patients (three transcervical and two transfacial approaches) and a transoral approach in one patient. We had two cases of complicated sialadenitis: a parotid abscess in one and an initial phlegmon of the mouth floor in the other case. Two cases with submandibular sialolithiasis were salvage procedures following previous unsuccessful non-guided sialendoscopy. In all six patients, the stones were non-palpable, and only two of them were partially visible on sialendoscopy. All but one stone were in a proximal position and fixed. With the use of CT guidance, we were able to preserve all but one salivary gland. The latter patient had an obstruction due to a severe far proximal stricture and a stone positioned behind it (i.e., more proximally than the stricture itself).

TABLE 4. Sialendoscopy and navigation-assisted combined approach procedures at the Department of Otorhinolaryngology and Cervicofacial Surgery November 2019 – November 2020

Patient	Age (years)	Sex	History	Site	Stone palpability	Stone location	Stone visibility	Fixation	Approach	Stone size (millimeters)	Final depth reached with sialendoscope (millimeters)	Follow-up
1	67	F	Acute abscess formation	Left parotid	No	Within the abscess cavity	Not visible	-	Transcutaneous sialendoscopy-assisted	5 (SPH)	72	Without complaints 14 months
2	46	M	Advanced sialolithiasis	Right submandibular	No	55 millimetres depth	Partially visible	Fixed	Transcutaneous sialendoscopy-assisted	10 (SPH)	60	Without complaints 12 months
3	60	F	Persisting swelling	Right parotid	No	45 millimetres depth	Partially visible	Fixed	Transcutaneous sialendoscopy-assisted	7 x 4 x 3	65	Without complaints 11 months
4	70	M	Advanced sialolithiasis	Left submandibular	No	64 millimetres depth	Non visible	Fixed	Transcutaneous sialendoscopy-assisted	10 (SPH)	75	Without complaints 11 months
5	21	M	Persistent swelling	Left submandibular	No	100 millimetres depth	Not visible	Fixed	Transcutaneous sialendoscopy-assisted	3 (intraglandular, found after gland resection)	90	After gland resection without complaints 7 months
6	34	M	Floor of the mouth phlegmona	Left submandibular	No	28** millimetres depth	Not visible	Fixed	Transoral sialendoscopy-assisted	6 x 4 x 3	62	Without complaints 14 months

SPH = spheric form; ** = depth at the time of extraction

Discussion

Ultrasonography proved to be an accurate tool in our preoperative workup of submandibular sialolithiasis, with a 4.4% false-negative rate. All of the missed stones were in the distal Wharton's duct and had a narrow and elongated shape, with a transverse diameter 3 mm or less. Similar findings (5.1% false-negative cases) were published by German authors and explained by the mandible acoustic shadow.¹³ In addition to the salivary stone position (proximity along the ductal tree), the ultrasonography's sensitivity for detecting the calculi mainly depends on their sheer size. Authors from Geneva report that stones with a diameter of less than 3 mm were missed in ultrasonical diagnosis in 10 out of 19 glands in their study and explain this by the absence of dorsal acoustic shadow of the calculi.¹⁴ Our findings confirm the relationship between the sensitivity of the ultrasound examination and the size of the salivary stones. In our series, 8 lengthy but narrow salivary stones were missed (longer diameter 8–10 mm and transverse 2–3 mm). Ultrasonography also proved to be a sensitive tool in estimating the state of the related soft tissue, *i.e.*, for exclusion of nonobstructive pathology.

The proportion of patients with a CT examination has been more extensive in the last 4 years as a result of growing experience of the importance of input diagnostic information on possible multi-

plicity of stones.¹⁵ High-resolution CT has a crucial role in post-treatment monitoring, especially in submandibular sialolithiasis, since it offers more information about possible residual stones than do clinical and ultrasound findings.¹⁶ Due to its non-invasiveness and accuracy, sialo-MRI is the most appropriate method for assessing high-grade salivary duct strictures.¹⁷ It is different from classic, CT-based or CBCT (cone beam computer tomography) sialography. There is no need for cannulation of the duct for endoluminal contrast injection. The procedure can therefore be used even during acute sialadenitis. Although we have used it relatively sparsely, in only eight patients, we believe that sialo-MRI has many advantages and should be used more often.

Most of the sialendoscopies and sialendoscopy-assisted operations were performed under local anesthesia (72.77%). With proper patient selection, procedures were well tolerated, and there were no adverse reactions to local anesthesia. Cases of transient, short-lasting paresis of the buccal branch of the 7th cranial nerve after parotid sialendoscopy were rare. Our experience is consistent with already reported good tolerance of sialendoscopies conducted under local anesthesia by Luers *et al*, provided that patients were in good general health and the operative procedure was not complicated or long-lasting.¹⁸

There were 178 successful salivary stone extractions in the present series, and the combined

sialendoscopy-assisted approach was the most common type of procedure. The reason was the lack of a laser or pneumatic lithotripter as a secondary minimally invasive stone fragmentation option. Slovenia was also a »sialendoscopic native« area, with a great proportion of previously untreated patients with large salivary stones.¹⁰ On the other hand, there has been a general trend of a »combined approach come back« in the last few years. According to the recommendations of ESTC and some other authors, it still has an important place in calculi bigger than 7 mm.^{6,14,15} Our own experience with deeply embedded, extraluminal and especially in abscess formation positioned stones corroborates their opinion.

The majority of salivary calculi were removed through oral mucosa incisions during combined approach surgery (102 surgeries). We had a significantly higher proportion of transcutaneous procedures than reported by authors from purely sialendoscopic quaternary centers.¹⁹ The number of submandibular transcutaneous operations, in particular, was exceptionally high. Salivary stones are found significantly more often in the submandibular than in the parotid ductal system.²⁰ On the other hand, parotidectomy is often avoided in patients with sialolithiasis because of the risk of facial nerve injury.

For the same reason, the transfacial combined approach with gland preservation is well established for proximal stones of Stensen's duct.²¹ On the other hand, submandibular gland resection was the most frequently performed type of end-stage treatment in patients with salivary stones.¹⁰ The gland preservation procedure for far proximal submandibular sialolithiasis was reported and recommended more modestly.²² The reason may be doubt in the long-term success of this type of procedure and a (repeated) possibility of marginal branch injury. Our attitude on the importance of salivary gland preservation, both parotid and submandibular, is based on findings of the indispensable role of saliva in maintaining the health of the oral and upper gastrointestinal system.²³ In addition, there is undoubtedly enough evidence of salivary gland function recovery after sialendoscopy.²⁴ For these reasons, we endeavored ten successful transcutaneous combined sialendoscopy-assisted procedures for far proximal submandibular stones; in three of them, CT navigation was also employed. With the consistent implementation of all kinds of sialendoscopic techniques, we significantly reduced the need for sialoadenectomies in patients with obstructive salivary gland disease. We were

forced to resect one of the salivary glands in only six of 372 patients (1.6%) in whom sialendoscopy was part of the treatment. Compared with the period before the introduction of sialendoscopy, the annual number of resections was reduced by 93.3% (15-fold), which represents an additional improvement of our previously published results.¹⁰

All six patients in our navigation subgroup had non-palpable salivary stones, even though their stones were relatively large (only one measured less than 5 mm). The reason for this seemingly paradoxical situation was the far proximal position of the stone in four cases, the phlegmon of the floor of the mouth in one and a parotid abscess formation in the remaining case. Good visibility on sialendoscopy is mandatory for all successfully performed solely endoscopic stone extractions and for a majority of combined approach procedures. Our inability to display calculi during sialendoscopy was also among the indications for the use of CT navigation in four cases: stone inside abscess formation¹, far proximal position of the calculi (literally in the middle of the gland²), and terrible visibility inside the main duct.¹ There is only one procedure described so far combining salivary stone removal with both sialendoscopy and CT navigation assistance: the authors reported an excellent matching of the two guidance methods.⁸ They therefore confirmed the probable validity of additional CT navigation guidance. Its introduction in sialolithiasis surgery represents a significant improvement and, in our opinion, has great added value, especially in challenging cases. We observed no facial nerve paresis or paralysis, sialocele or salivary fistula among the patients with the transcutaneous navigation-assisted approach. We therefore regard it as equally safe as a non-navigated combined approach.

It is essential to point out more or less obvious pitfalls of the CT navigation guidance method. Without the additional acquisition of (less than accessible) intraoperative CT, it does not allow any real-time correction, which makes CT navigation guidance an excellent method in patients with fixed salivary stones. The final step in locating the stone in virtually any type of approach is careful preparation of the last remnants of tissue over the stone. In difficult cases, the final position of the stone is easily missed; repeated axis check using the navigation may therefore be the only way to localize the stone or multiple stones. Since we had experience with a proximally shifted stone, the authors believe that the navigation in possibly non-fixed stones should be used with caution.

Even with navigation, the obstruction caused by a severe stricture containing the stone in an intraglandular position could not be resolved without gland resection. These challenging situations seem to be relatively infrequent.

Conclusions

The combined use of sialendoscopy and CT navigation assistance is a step forward in minimally invasive surgery of sialolithiasis, especially in far proximal, intraparenchymal, non-palpable and sialendoscopically non-visible fixed stones, irrespective of the type of combined approach or salivary gland. CT navigation proved to be of help in demanding transcutaneous submandibular stone extractions, with gland preservation. It is invaluable in cases of extraluminal, *i.e.*, positioned in an abscess or deeply embedded stones. With the consistent implementation of sialendoscopy and related minimally invasive procedures, we can significantly reduce the need for sialoadenectomies in patients with obstructive salivary gland disease.

References

- Marchal F, Dulguerov P, Becker M, Barki G, Disant F, Lehmann W. Specificity of parotid sialendoscopy. *Laryngoscope* 2001; **111**: 264-71. doi: 10.1097/00005537-200102000-00015
- Marchal F, Dulguerov P, Becker M, Barki G, Disant F, Lehmann W. Submandibular diagnostic and interventional sialendoscopy: new procedure for ductal disorders. *Ann Otol Rhinol Laryngol* 2002; **111**: 27-35. doi: 10.1177/000348940211100105
- Ardekian L, Klein H, Al Abri R, Marchal F. Sialendoscopy for the diagnosis and treatment of juvenile recurrent parotitis. *Rev Stomatol Chir Maxillofac Chir Orale* 2014; **115**: 17-21. doi: 10.1016/j.revsto.2013.12.005
- Carroll WW, Walvekar RR, Gillespie MB. Transfacial ultrasound-guided gland-preserving resection of parotid sialoliths. *Otolaryngol - Head Neck Surg* 2013; **148**: 229-34. doi: 10.1177/0194599812471514
- Caversaccio M, Zheng G, Nolte LP. [Computer-aided surgery of the paranasal sinuses and the anterior skull base]. [German]. *HNO* 2008; **56**: 376-82. doi: 10.1007/s00106-008-1705-2
- Lorenz KJ, Frühwald S, Maier H. [The use of the BrainLAB Kolibri navigation system in endoscopic paranasal sinus surgery under local anaesthesia. an analysis of 35 cases]. [German]. *HNO* 2006; **54**: 851-60. doi: 10.1007/s00106-006-1386-7
- Groselj A, Kos B, Cemazar M, Urbancic J, Kragelj G, Bosnjak M, et al. Coupling treatment planning with navigation system: a new technological approach in treatment of head and neck tumors by electrochemotherapy. *Biomed Eng Online* 2015; **14(Suppl 3)**: S2. doi: 10.1186/1475-925X-14-S3-S2
- Capaccio P, Bresciani L, Di Pasquale D, Gaffuri M, Torretta S, Pignataro L. CT navigation and sialendoscopy-assisted transfacial removal of a parotid stone: a technical note. *Laryngoscope* 2019; **129**: 2295-8. doi: 10.1002/lary.27621
- Pezier TF, Prasad S, Marchal F. Towards an international database of benign salivary disease. *Br J Oral Maxillofac Surg* 2016; **45**: 968-9. doi: 10.1016/j.bjoms.2016.01.015
- Aničin A, Urbancič J. Sialendoscopy, a minimally invasive diagnostic and interventional procedure for the management of salivary gland diseases. *Zdr Vestn* 2016; **86**: 92-8. doi: https://doi.org/10.6016/ZdravVestn.1469
- Rzymaska-Grala I, Stopa Z, Grala B, Gołębowski M, Wanyura H, Zuchowska A, et al. Salivary gland calculi - contemporary methods of imaging. *Polish J Radiol* 2010; **75**: 25-37. http://www.ncbi.nlm.nih.gov/pubmed/22802788
- Yousem DM, Kraut MA, Chalian AA. Major salivary gland imaging. *Radiology* 2000; **216**: 19-29. doi: 10.1148/radiology.216.1.r00j4519
- Goncalves M, Mantsopoulos K, Schapher M, Iro H, Koch M. Ultrasound supplemented by sialendoscopy: diagnostic value in sialolithiasis. *Otolaryngol - Head Neck Surg* 2018; **159**: 449-55. doi: 10.1177/0194599818775946
- Terraz S, Poletti PA, Dulguerov P, Dfouni N, Becker CD, Marchal F, et al. How reliable is sonography in the assessment of sialolithiasis? *Am J Roentgenol* 2013; **201**: W104-9. doi: 10.2214/AJR.12.9383
- Madani G, Beale T. Inflammatory conditions of the salivary glands. *Semin Ultrasound CT MR* 2006; **27**: 440-51. doi: 10.1053/j.sult.2006.09.005
- Avrahami E, Englander M, Chen E, Shabtay D, Katz R, Harell M. CT of submandibular gland sialolithiasis. *Neuroradiology* 1996; **38**: 287-90. doi: 10.1007/BF00596550
- Becker M, Marchal F, Becker CD, Dulguerov P, Georgakopoulos G, Lehmann W, et al. Sialolithiasis and salivary ductal stenosis: diagnostic accuracy of MR sialography with a three-dimensional extended-phase conjugate-symmetry rapid spin-echo sequence. *Radiology* 2000; **217**: 347-58. doi: 10.1148/radiology.217.2.r00oc02347
- Luers JC, Stenner M, Schinke M, Helmstaedt V, Beutner D. Tolerability of sialendoscopy under local anesthesia. *Ann Otol Rhinol Laryngol* 2012; **121**: 269-74. doi: 10.1177/000348941212100413
- Koch M, Iro H, Zenk J. Combined endoscopic-transcutaneous surgery in parotid gland sialolithiasis and other ductal diseases: reporting medium- to long-term objective and patients' subjective outcomes. *Eur Arch Oto-Rhino-Laryngology* 2013; **270**: 1933-40. doi: 10.1007/s00405-012-2286-y
- Capaccio P, Torretta S, Ottavian F, Sambataro G, Pignataro L. Modern management of obstructive salivary diseases. *Acta Otorhinolaryngol Ital* 2007; **27**: 161-72. PMID: 17957846
- Koch M, Zenk J, Iro H. Algorithms for treatment of salivary gland obstructions. *Otolaryngol Clin North Am* 2009; **42**: 1173-92. doi: 10.1016/j.otc.2009.08.002
- Marchal F. A combined endoscopic and external approach for extraction of large stones with preservation of parotid and submandibular glands. *Laryngoscope* 2007; **117**: 373-7. doi: 10.1097/mlg.0b013e31802c06e9
- Llena-Puy C. The rôle of saliva in maintaining oral health and as an aid to diagnosis. *Med Oral Patol Oral Cir Bucal* 2006; **11**: E449-55. doi: 10.1097/mlg.0b013e31802c06e9
- Su YX, Xu JH, Liao GQ, Liang YJ, Chu M, Zheng GS, et al. Salivary gland functional recovery after sialendoscopy. *Laryngoscope* 2009; **119**: 646-52. doi: 10.1002/lary.20128