

## Ultrasound-guided aspiration biopsy of subclinical regional metastases of head and neck carcinoma

Alenka Višnar-Perovič<sup>1</sup>, Aleksandar Aničin<sup>2</sup>, Živa Zupančič<sup>1</sup>, Bojana Černelč<sup>1</sup>,  
Lojze Šmid<sup>2</sup>, Dubravka B. Vidmar<sup>1</sup>, Milan Gorenc<sup>1</sup>

<sup>1</sup> Clinical Institute of Radiology, University Medical Centre, Ljubljana, Slovenia, <sup>2</sup> University Department of Otorhinolaryngology and Cervicofacial Surgery, University Medical Centre, Ljubljana, Slovenia

---

**Background.** Studies concerned with the estimation of ultrasound (US) combined with ultrasound-guided aspiration biopsy (USGAB) in the detection of subclinical regional metastases from the planocellular carcinoma of head and neck are promising, but in few cases. Recently, the authors have pointed out the role of lymph node size parameters in order to decide about the use of USGAB. The aim of this study was to test the reliability of US-USGAB for the detection of subclinical regional metastases in patients with planocellular head and neck carcinomas, including the evaluation of lymph node size parameters.

**Patients and methods.** 121 neck sides with no palpable metastases were examined by US in 77 patients with planocellular carcinomas of head and neck. Depending on the results obtained, USGAB was performed on 64 neck sides. After surgery, the results of US-USGAB were compared with histological findings of the dissected lymph nodes.

**Results.** The study showed 77 % overall sensitivity of US and USGAB, and 100 % specificity, while the 95% accuracy rate was reached. Negative predictive value was 94 %, and positive 100 %. The index of transversal / longitudinal diameter was the best predictor of metastatic lymph node involvement.

**Conclusion.** The results of this study established that USGAB is an appropriate method for detection the subclinical regional metastases on neck, and should be included into the routine diagnostic work up in the evaluation of the extent of head and necks carcinomas.

*Key words:* head and neck neoplasms - pathology - ultrasonography; biopsy needle; lymphatic metastasis

---

### Introduction

Planocellular carcinomas of head and neck frequently disseminate into the regional lymph nodes. Presence or absence of lymph node metastases is one of the most relevant prognostic factors, as the cure rate is 50% lower in patients with regional metastases.<sup>1</sup>

Received 15 May 2000

Accepted 30 May 2000

Correspondence to: Alenka Višnar-Perovič, Clinical Radiology Institute, University Medical Centre Ljubljana, Zaloška 7, SI-1525 Ljubljana. Phone: +386 1 143 15 30; Fax: +386 1 133 31 044; E-mail: alenka.perovic@s5.net

Occult regional metastases represent a particular problem in the diagnosis and treatment of the patients with planocellular head and neck carcinomas, as they can be difficult to detect by imaging methods. Therefore, in most centers the elective treatment of neck is considered to be indicated when the risk of subclinical regional metastases, assessed on the basis of primary tumor site and size, exceeds 15 do 20%.<sup>2,3</sup> However, treatment could be more directed and effective if the preoperative diagnosis of lymph node condition in the clinical stage N0 were comparable with histological findings of the dissected neck lymph nodes.

The assessment of metastatic neck lymph node involvement by palpation is unreliable, as the obtained results were false negative (up to 30%) and false positive (up to 20%).<sup>4</sup> Several authors found CT more sensitive than palpation.<sup>5-7</sup> Magnetic resonance with a contrast medium (MR) can detect up to 60% of clinically occult metastases in the neck lymph nodes<sup>8</sup>, and 70% accuracy in stage N0 is the result of using only ultrasonography (US).<sup>9</sup> Nevertheless, the authors agree that the mentioned methods, by using only morphologic criteria, cannot reliably differentiate between reactive inflammatory changes and metastatic involvement of the lymph nodes.<sup>8,10</sup> Considering recent technologic development, the diagnosis of suspicious lymph nodes can be most accurate by using high resolution ultrasound in conjunction with guided fine - needle aspiration biopsy (USGAB). With this technique, the high sensitivity of US is complemented by the excellent specificity of aspiration biopsy.<sup>11</sup> In the available reports, the diagnosis of neck lymph node metastases in patients with planocellular head and neck carcinomas stage N0 with USGAB yielded 76% sensitivity, 100% specificity and 89% accuracy.<sup>9</sup> These results are better than those reported for MR or CT.<sup>5-8</sup> The importance of particular sonographic lymph node size parameters is still controversial. While some authors believe that the transversal lymph no-

de's diameter is the most important<sup>8</sup>, others claim that the relation between the transversal and the longitudinal diameter more reliably predicts metastatic lymph node involvement.<sup>12</sup> Relevant for consideration is the reliability of negative US-USGAB findings. Some authors tried to solve this question by using Bayes' formula, which correlates the probability of subclinical neck metastases before and after US-USGAB procedure.<sup>13</sup> Few studies have been carried out on the use of US and USGAB in the diagnosis of subclinical regional metastases in groups of patients with previously untreated planocellular carcinomas of oral cavity, pharynx and larynx where elective dissection of the neck lymph nodes was foreseen as well (stage N0). Therefore we decided to test US-USGAB method in our institution by using the above mentioned criteria for selection of patients, also evaluating the size of lymph nodes.

### Patients and methods

In the period from October 1995 to June 1997, there were 77 patients with previously untreated and histologically confirmed planocellular carcinoma of the upper respiratory and gastrointestinal tract. The mean age of the patients was 56 years (range 37-76 yrs); there were 7 females (9%) and 70 males (91%). All these patients were planned for surgery of the primary tumor with neck dissection. There was no evidence of palpable nodes on the neck in 61 patients (79%). In the remaining 16 patients (21%) the enlarged lymph nodes could be palpated only on one side of the neck. Because these patients required bilateral neck dissection, only the neck sides without palpable lymph nodes were included into this study.

Following the clinical examinations with neck palpation performed by otorhinolaryngologists, each patient underwent the ultrasonography examination of the neck using a

linear 7.5 MHz probe of Sonolayer HR system, Toshiba SSA-270 A. USGAB was performed of lymph nodes with a transverse diameter exceeding 5 mm, lymph nodes with transverse vs. longitudinal diameter ratio greater than 0.40, ultrasonographically non-homogeneous lymph nodes, and in those with Doppler-US evidence of pathological vascularization. USGAB was also undertaken in borderline cases with respect to the above criteria, if three or more such lymph nodes were found in the most exposed anatomical levels. Aspiration biopsies were performed using thin needles with the inner diameter 0.6 and 0.7 mm, produced by TIK Kobarid. Each USGAB procedure was attended by two experienced radiologists specialized in sonography. In the first study, i.e. from October 1995 to November 1996, USGAB was carried out »free hand«, whereas from June 1997 on, aspiration biopsies were carried out by means of a micro-convex probe with guidance. After fixation and staining by Giemsa, the smears were reviewed and assessed by cytopathologists.

Though in some patients USGAB was not indicated, as the lymph nodes' transversal diameter did not exceed 5 mm, and their distribution and shape were inconspicuous. In other patients USGAB was performed according to criteria mentioned above, and the cytological smear could contain lymph node cells, squamous carcinoma cells, or material insufficient for a cytological diagnosis (nondiagnostic material). In the case when the aspirate contained malignant cells, the

result of US-USGAB was considered positive. When aspiration biopsy failed to detect malignant cells or when USGAB was not indicated due to inconspicuous US findings, the overall US-USGAB result was considered negative.

After having completed the diagnostic procedure, all the patients underwent surgery of the primary tumor, together with either uni- or bilateral neck dissection. Primary tumors were arranged according to the TNM classification<sup>12</sup> taking into account their extent, as assessed during the surgery (Table 1).

In the case of negative US-USGAB findings, a selective dissection of the neck was performed, while a modified radical neck dissection (RND) was done only in the case of positive US-USGAB findings. All the dissected tissue samples were positioned and labelled. Using standard procedure, every 2 mm 4-5  $\mu$ m thick slices were cut and stained with hematoxylin and eosin. The preoperative US and USGAB results were compared to the results of pathohistological evaluation, this being possible on the basis of the registered position and size of the described lymph nodes.

The value of US-established lymph nodes' size parameters, i.e. of transversal and longitudinal diameter and the transversal diameter in proportion to the longitudinal diameter, was statistically evaluated by means of Student's T-test and standardized normal distribution. The reliability of negative US and USGAB findings was evaluated using the curve deriving from Bayes' formula.

**Table 1.** Distribution of patients by primary tumor site and stage

Site:	Oral cavity	Oro- Pharynx	Hypo- pharynx	Larynx	Total
Stage:					
T1	3			2	5
T2	14	8		7	29
T3		4	11	13	28
T4			5	10	15
Total	17	12	16	32	77

## Results

There were altogether 121 neck sides examined by US, 61 of them were ipsilateral with the primary tumor. In each examined side, US imaged 1-9 lymph nodes (3 on average), their transversal diameters ranging between 2 - 12 mm and the longitudinal diameters between 5 - 20 mm. In 55 cases, the lymph nodes were small, measuring up to 8 mm in longitudinal diameter and up to 5 mm in transversal diameter, and were oval-shaped and nonsuspicious for malignant involvement. In these 55 cases (neck sides) USGAB was not indicated, and thus the test findings (that is of US and USGAB) were assessed as negative. In the remaining 66 cases USGAB was performed and max. 3 lymph nodes per test side were punctured. Individual lymph nodes were aspirated one to four times, twice on average. Cytological samples from 41 neck sides showed only lymph node tissue, while from 5 neck sides they contained nondiagnostic material. In these cases, the test findings were also assessed as negative. In 20 cases, the cytological examination confirmed the presence of malignant cells. The longitudinal diameter of USGAB positive lymph nodes ranged between 7 and 17 mm (average 12 mm), their transversal diameter between 5 and 12 mm, while the index of transversal vs. longitudinal diameter in an individual USGAB positive lymph node ranged between 0.45 and 0.95. In 16 cases, US-USGAB positive lymph node belonged to the upper jugular group (level II), in 3 cases to the middle jugular (level III), and in only one case to the submandibular (level I). On only one neck side, the two aspirates from two different lymph nodes were cytologically positive, while in all others the cytologically positive sample was obtained from a single lymph node.

Totally in 77 patients, there were 82 lateral neck dissections performed, 31 supraomohyoid and 8 modified RND. Separate neck side

surgical specimens contained from 9 to 50 histologically examined lymph nodes. Metastases could be found in altogether 32 lymph nodes, taken from 26 neck sides. In each of these cases, the evidence of metastases was confirmed in 1 - 3 lymph nodes with a longitudinal diameter 6 - 20 mm (average 13 mm), and a transversal diameter 5 - 12 mm.

In all 20 cases with positive cytological USGAB findings, the diagnosis was confirmed by the histological examination of the surgically removed lymph nodes. Out of the total of 46 negative USGAB, there were two false-negative; in both the aspirates contained lymphatic elements. None of the neck sides which yielded nondiagnostic material (aspirates from oval shaped lymph nodes, diameter 5-7 mm), showed histological evidence of metastatic involvement. Out of 55 US-based negative results, four were false negative. In all 6 false negative cases, the largest lymph nodes, assessed by pathologist, have transverse diameter 4 - 7 mm and were invariably situated on level II. In one of the mentioned cases, the pathologist found a single micro-metastasis in the peripheral sinus of lymph node. Also in the remaining 5 cases focal metastatic growth in the lymph node was evident.

The estimation value of US and USGAB for detection of unpalpable regional metastases

**Table 2.** Results obtained in total 121 neck sides with respect to the use of USGAB

USGAB:	Yes	No (US only)	Total
test +	20	0	20
test -	44	51	95
false -	2	4	6
Total	66	55	121

**Table 3.** Cumulative results of US and USGAB obtained in 121 neck sides of 77 patients

Results	Histology +	Histology -	Total
US, USGAB+	20	0	20
US, USGAB-	6	95	101
Total	26	95	121

resulting from planocellular carcinoma showed 77 % sensitivity and 100 % specificity, the negative predictive value was 94 %, while the positive predictive value was 100 %. On the whole, 115 correct predictions were obtained by US - USGAB in 121 neck sides, the investigation's accuracy was 95 %. The results are presented in Tables 2 and 3.

Based on the results presented in Table 3, the basic indicators of cumulative success of US and USGAB were calculated as follows:

- Sensitivity:  $20 / 26 = 77 \%$
- Specificity:  $95 / 95 = 100 \%$
- Negative predictive value:  $95 / 101 = 94 \%$
- Positive predictive value:  $20 / 20 = 100 \%$
- Accuracy:  $115 / 121 = 95 \%$

In the free-hand performed USGAB of 18 neck sides, there were two false negative results whereas in the USGAB with the use of a micro-convex probe with guidance in 48 neck sides, there was no false negative results (the difference was statistically insignificant).

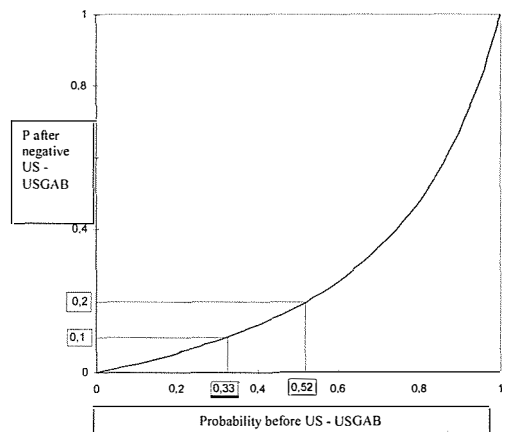
#### *The value of lymph node size parameters*

We evaluated the statistical significance of differences and averages between the groups of cases with and without histologically confirmed metastases, taking into account the largest lymph node parameters as determined by US in individual neck sides (transversal diameter, longitudinal diameter and the ratio between these two). In the neck sides without metastases, the average largest transversal diameter was 5.98 mm, while in the neck sides with metastases, it was 8,12 mm. The differences as calculated by T-test were statistically highly significant ( $p < 0.005$ ). When calculating the ratio between the transversal and the longitudinal lymph node diameters, the T-test also showed statistically significant differences ( $p < 0.001$ ), the index in neck sides with metastases being 0.64, and in those without metastases, 0.47. The comparison of longitudinal diameters yielded a statistically insignificant value. In this study we also eval-

uated the statistical significance of differences in the average largest US-determined size parameters in neck sides with or without cytologically confirmed metastatic involvement, with respect to transversal diameter, longitudinal diameter, and the ratio between the two. The ratio between the transversal and longitudinal diameter turned out to be statistically most relevant ( $p < 0.0001$ ); in transversal diameter this was less ( $p < 0.01$ ). There too, the longitudinal diameter turned out statistically insignificant.

#### *The use of Bayes theorem in the evaluation of US and USGAB diagnosis*

Using the formula based on Bayes theorem, the 100 % specificity and 77 % sensitivity obtained in this study, yielded the curve presented in Figure 1. This shows that with negative US and USGAB, the probability of subclinical lymph node metastases is decreased from the previous 20 % to 5.4 % in the neck sites without palpable metastases. On the other hand, the 20 % and 10 % probability of subclinical neck metastases after negative US and USGAB correspond to 52 % in 33 % probability without US and USGAB.



**Figure 1.** Probability of subclinical lymph node metastases before and after negative US-USGAB.

## Discussion

Reports with comparable inclusion criteria are few. The results of our study are comparable with those reported by Brekel and co-workers.<sup>9</sup> In a large number of other reports, the inclusion criteria were broader, since authors also included patients with clinically evident neck metastases, patients with previous radiotherapy or patients with primary tumors which histologically did not correspond to planocellular carcinoma.

Rather than in the sensitivity of the test, the clinician is interested in the reliability of its negative findings, or what is the negative predictive value (NPV). Providing this parameter is sufficiently reliable, patients with negative findings could be spared elective neck treatment. In our study, there were altogether 6 false negative results, the NPV was thus 94% (95/101). In the cases with USGAB performed, NPV was 96% (44/46). In the Dutch study with inclusion criteria similar to ours,<sup>9</sup> the use of USGAB resulted in 82% NPV. This difference in NPV can be partly attributable to the difference in the rate of histologically confirmed cases with subclinical neck metastases (21.5% in our study vs. 40% reported by Dutch authors).

In neck sides with false negative results of US-USGAB, histological examination confirmed metastases exclusively in the lymph node level 2, originating from an extensive carcinoma of the supraglottis as primary tumor; and were at least partly due to the superposition. In all false negative cases, small metastatic islets were found in the lymph nodes, and in one of them situated only in a marginal sinus. As neither USGAB nor any other diagnostic method is able to detect micrometastases from planocellular carcinoma, we think that even a repeated USGAB on a greater number of lymph nodes would only slightly improve the sensitivity of this method.

Cases, for which USGAB fails to provide material for cytological diagnosis, represent a

separate problem. In the study by Brekel et al.<sup>9</sup>, there were 70 USGABs performed, out of these 6 yielded nondiagnostic material. When evaluating the results, those cases were defined as negative. The authors claim that the results would appear to be better if such cases were excluded from the study, as it was done in a majority of similar studies, in order to reduce the number of false negative results. In Takashima's et al.<sup>12</sup> report, such cases (7.7%) were excluded from the study, but none of the neck sides had metastatic involvement histologically confirmed. In our study, USGAB was performed on 66 neck sides, and nondiagnostic material was obtained in 5 cases. None of those five sides had histological evidence of metastases, and therefore the results of the present study remain practically unchanged, regardless of whether the cases with nondiagnostic material are excluded or included as negative by US-USGAB. In none of the reported studies USGAB was repeated in case of nondiagnostic material. There are controversial opinions whether these cases should be included or excluded from studies. We believe that in studies based on similar principles, that the cases in which USGAB provided nondiagnostic material should be included and defined as negative in order to obtain a more objective assessment of the usefulness of the method.

In the available reports, the authors describe only »free hand« performance of USGAB for the detection of subclinical neck lymph node metastases. Based on our own experience, in the first part of our study, »free hand« performed USGAB gave 2 false negative results, while no such cases were observed when the method was upgraded by means of an additional micro-convex probe with guidance. Despite the statistically insignificant difference in the frequency of false negative results, we believe that the use of probe with guidance facilitates USGAB and reduces the occurrence of errors.

Among the US parameters determining the probability of lymph node metastases,

particularly the relevance of size criteria has been pointed out in the last decade. While Dutch authors<sup>8</sup> report that the transversal lymph node diameter (minimal axial) is the most reliable size criterion for the detection of subclinical metastases, the Japanese investigators<sup>12</sup> proved that the ratio (index) between the transversal and longitudinal diameter is an even better predictive parameter. According to the results of their investigation, there are significantly more metastatically involved lymph nodes among those with the index above 0.55. The relevance of the diameter ratio has also been confirmed by calculating the area under the ROC curve, this being significantly greater than in either transversal or longitudinal lymph node diameter (0.83 / 0.65 / 0.44). After grouping the neck sides by the presence / absence of histological and cytological evidence of metastatic involvement, we obtained highly significant differences of average diameter ratio; the differences were significant in the transversal diameter, while the longitudinal diameter proved to be irrelevant for the diagnosis of subclinical regional metastases from head and neck carcinoma.

By improving the detection of subclinical neck metastases, it is possible to change to a certain extent the concept of elective lymph node treatment in patients with planocellular carcinoma of the upper respiratory and alimentary tract. Thus Brekel et al.<sup>9</sup>, suggest that elective dissection should be omitted always when a reliable diagnostic method reduces the risk of subclinical neck metastases below 10-15%, particularly in patients where the primary tumor can be removed by transoral approach, but under the condition that the patient is legible to regular follow up. The findings of our study also support the opinion that in certain cases the elective treatment of neck lymph nodes could be omitted on the account of better diagnosis. As evident from Bayes' curve (Figure 1) derived from our study results, the previous 33% risk of subclinical metastases predicted on the basis of

primary tumor site and size, was reduced to 10% after negative US-USGAB. Better diagnosis, improved by means of US-USGAB, would be most valuable for patients who are generally not planned to undergo elective treatment of neck lymph nodes (initial carcinomas of the glottis, sinuso-nasal tract, skin of the head and neck), and where a therapeutic dissection could be carried out in the case of positive findings. Likewise, a decision on therapeutic neck dissection could be made in the case of positive findings in the candidates for an elective procedure. In patients planned for primary radiotherapy, the use of US-USGAB will improve the detection of nonpalpable regional metastases, and the irradiation field could be adjusted with respect to the obtained findings.

## Conclusions

By combining the sensitivity of US examination with the specificity of US guided aspiration biopsy (US-USGAB) it is possible to detect a majority of subclinical regional metastases originating from planocellular carcinoma of head and neck

The ratio between the transversal and longitudinal lymph node parameters is to be the most relevant of US size parameters to be respected in deciding to perform USGAB. US-USGAB can be recommended as the routine investigations for evaluating regional metastatic spread of head and neck carcinomas.

## References

1. Spiro RH, Alfonso AE, Farr NW, Strong EW. Cervical node metastases from epidermoid carcinoma of the oral cavity and oropharynx. A critical assessment of current staging. *Am J Surg* 1974; **128**: 562-7.
2. Ogura JH, Biller HF, Wette R. Elective neck dissection for pharyngeal and laryngeal cancers: an evaluation. *Ann Otol Rhinol Laryngol* 1971; **80**: 646-51.

3. Lee JG, Krause CJ. Radical neck dissection. Elective, therapeutic and secondary. *Arch Otolaryngol* 1975; **101**: 656-9.
4. Ali S, Tiwari RM, Snow GB. False positive and false negative neck nodes. *Head Neck Surg* 1985; **8**: 78-82.
5. Friedman M, Shelton VK, Mafee M, Bellity P, Grybauskas V, Skolnik E. Metastatic neck disease: evaluation by computed tomography. *Arch Otolaryngol* 1984; **110**: 443-7.
6. Mancuso AA, Harnsberger HR, Muraki AS, Stevens MH. Computed tomography of cervical and retropharyngeal lymph nodes: normal anatomy, variants of normal, and applications in staging head and neck cancer, II. Pathology. *Radiology* 1983; **198**: 715-23.
7. Stevens MH, Harnsberger HR, Mancuso AA, Davis RK, Johnson LP, Parkin JL. Computed tomography of cervical lymph nodes: staging and management of head and neck cancer. *Arch Otolaryngol* 1985; **111**: 735-9.
8. Brekel MWM van den, Stel HV, Castelijns JA, Nauta JJ, Waal I van der, Valk J, Meyer CJ, Snow GB. Cervical lymph node metastases: assessment of radiologic criteria. *Radiology* 1990; **177**: 379-84.
9. Brekel MVM van den, Castelijns JA, Stel HV, Luth WJ, Valk J, Waal I van der, Snow GB. Occult metastatic neck disease: detection with ultrasound and ultrasound-guided fine needle aspiration cytology. *Radiology* 1991; **180**: 457-61.
10. Som PM. Lymph nodes of the neck. *Radiology* 1987; **165**: 593-600.
11. Baatenburg de Jong RJ, Rongen RJ, Verwoerd CDA, Overhangen H, Lameris JS, Knegt P. Ultrasound-guided fine-needle aspiration biopsy of neck nodes. *Arch Otolaryngol Head Neck Surg* 1991; **117**: 402-5.
12. Takashima S, Sone S, Nomura N, Tomiyama N, Kobayashi T, Nakamura H. Nonpalpable lymph nodes of the neck: assessment with US and US-guided fine-needle aspiration biopsy. *J Clin Ultrasound* 1997; **25**: 283-92.
13. Baatenburg de Jong RJ, Knegt P, Verwoerd CDA. Reduction of the number of neck treatments in patients with head and neck cancer. *Cancer* 1993; **71**: 2312-8.
14. Takes RP, Knegt P, Manni JJ et al. Regional metastasis in head and neck squamous cell carcinoma: revised value of US with US-guided FNAB. *Radiology* 1996; **198**: 819-23.