

Akutni pankreatitis z normalnimi vrednostmi lipaze: prikaz primera

Acute pancreatitis in a patient with normal lipase: a case report

Avtor / Author

Ustanova / Institute

Tjaša Kitanovski^{1,2}, Andrej Grahek¹, Žan Garvas³

¹Splošna bolnišnica Novo mesto, Urgentni center, Novo mesto, Slovenija; ²Univerzitetni klinični center Ljubljana, Klinični inštitut za radiologijo, Ljubljana, Slovenija; ³Univerza v Ljubljani, Medicinska fakulteta, Ljubljana, Slovenija;

¹General Hospital Novo mesto, Emergency center, Novo mesto, Slovenia; ²University medical centre Ljubljana, Institute of Radiology, Ljubljana, Slovenia; ³University of Ljubljana, Medical faculty, Ljubljana, Slovenia;

Ključne besede:

pankreatitis, negativne vrednosti lipaze, alkoholizem, nekrozantni pankreatitis, konzervativno zdravljenje

Key words:

pancreatitis, negative lipase, alcoholism, necrotizing pancreatitis, supportive care

Članek prispel / Received

17. 1. 2024

Članek sprejet / Accepted

21. 5. 2024

Naslov za dopisovanje /

Correspondence

Tjaša Kitanovski

General Hospital Novo mesto,
Emergency center, Novo mesto,
Slovenia

tjasa.kitanovski@gmail.com

Izvleček

Članek obravnava redke primer pacienta z akutnim pankreatitisom ter normalnimi vrednostmi lipaze. Pacient je v urgentni center prišel zaradi bolečin v trebuhu ter povišane telesne temperature. Laboratorijske preiskave so pokazale akutni vnetni proces, vrednosti lipaze pa so bile normalne. Diagnoza akutnega pankreatitisa je bila postavljena s pomočjo CT preiskave abdomena, najverjetneje alkoholne etiologije zaradi povišanih vrednosti transferina z zmanjšanim deležem ogljikovih hidratov (CDT) pri pacientu. Zdravljenje je bilo konzervativno, z agresivnim nadomeščanjem tekočin, prehransko podporo ter empirično antibiotično terapijo, kar je vodilo v klinično izboljšanje. Primer poudarja pomembnost celovitega diagnostičnega pristopa pri obravnavi pacientov s pankreatitisom, ki presega le standardne biokemične označevalce.

Abstract

This case report highlights the rare occurrence of acute pancreatitis in a patient exhibiting normal lipase levels. The patient presented to the emergency department with abdominal pain and fever. Laboratory tests indicated an acute inflammatory process but a negative lipase value. The diagnosis was established by a CT scan showing necrotizing pancreatic changes with elevated carbohydrate-deficient transferrin (CDT) levels, suggesting alcohol as the etiology. Management involved supportive care, aggressive fluid resuscitation, nutritional support, and empirical antibiotic therapy, which led to clinical improvement. This case emphasizes the importance of a comprehensive clinical assessment beyond standard biochemical markers in diagnosing and managing pancreatitis.

INTRODUCTION

Pancreatitis, an inflammatory condition affecting the pancreas, ranges from mild and self-contained to severe and life-threatening cases. Acute pancreatitis, caused predominantly by gallstones and excessive alcohol consumption, remains a significant health concern worldwide despite advancements in medical technology and interventions (1). A diagnosis typically

follows the Revised Atlanta Classification, which consists of abdominal pain, elevated serum amylase and/or lipase levels, or imaging demonstrating acute pancreatitis (2, 3). Due to the high negative predictive value of serum lipase (94% to 100%), normal lipase levels during acute pancreatitis are rare (4, 5). A subset of patients may present with normal lipase levels

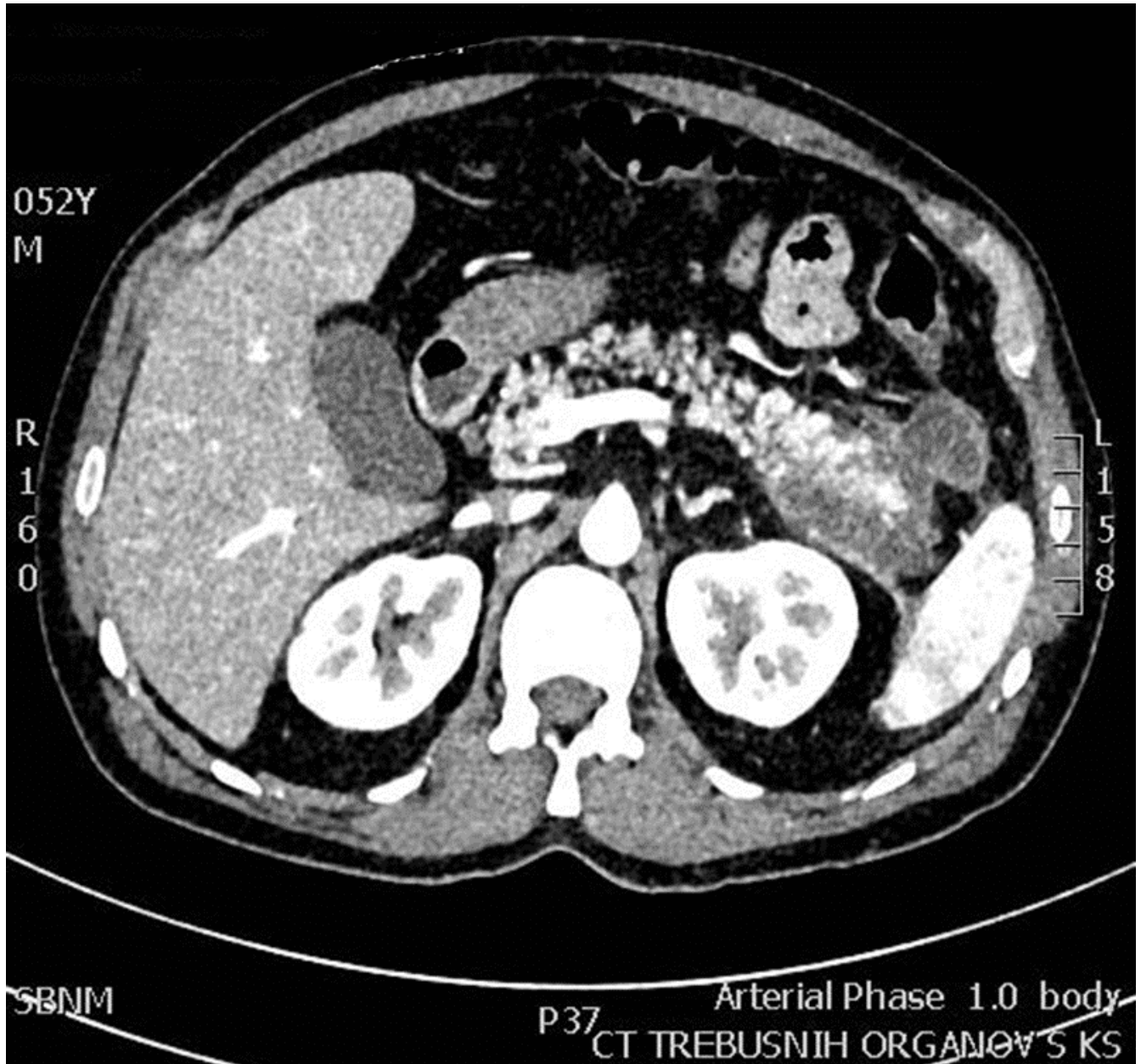


Figure 1. Axial CT scan of the abdomen with IV contrast in the arterial phase shows necrotic pancreatic changes, confirming the diagnosis of acute pancreatitis in a patient with normal lipase levels.

Source: Department of Radiology, Novo mesto General Hospital, Novo mesto, Slovenia. 2023

despite classic signs of pancreatitis, as presented in our case (3, 4).

CASE PRESENTATION

A 52-year-old male with a past medical history of arterial hypertension and a childhood history of acute lymphoblastic leukemia presented with a 2-day history of fever and stabbing pain in the left lower quadrant of his abdomen.

The patient described the pain as sharp, rated 8/10 in intensity while walking, and alleviated during rest. He denied nausea, vomiting, changes in stool color, or urinary symptoms. The absence of typical symptoms initially prompted consideration of differential diagnoses distinct from pancreatitis.

The clinical examination showed mild distress due to abdominal pain. However, the patient was otherwise alert and oriented with stable vital signs. His abdomen was tender to palpation, with muscle guarding present. Peristalsis was present.

Laboratory investigations revealed marked leukocytosis, elevated C-reactive protein (CRP) levels, and other laboratory abnormalities consistent with an acute inflammatory process. Notably, the patient's serum lipase levels were within the normal range (1,11 ukat/L) and did not rise during hospitalization (0,53 ukat/L on day 3) (Table 1).

A CT scan of the abdomen with IV contrast showed acute necrotizing pancreatitis, establishing the diagnosis (Figure 1). The patient received aggressive fluid resuscitation, bowel rest, and parenteral nutrition, followed by a targeted diet protocol. The etiology of the pancreatitis was attributed to alcohol due to the elevated CDT levels and concurrent withdrawal symptoms necessitating anxiolytics. Other common etiologies were deemed less probable due to the absence of trauma, medication, and prior interventions. Bilirubin values, liver function tests, triglyceride, and calcium values were normal, and there were no biliary stones on the CT scan.

Empirical antibiotic therapy with piperacillin/tazobactam was initiated due to elevated inflammatory markers and fever. This led to clinical improvement.

Table 1: The patient's laboratory values at admission showed normal lipase and amylase levels.

| | Patient's laboratory values at admission | Normal laboratory values |
|----------------------|--|---------------------------------|
| Leukocytes | 25,64 10 ⁹ /L | 4,0 - 10,0 10 ⁹ /L |
| Erythrocytes | 5,35 10 ¹² /L | 4,50 - 5,50 10 ¹² /L |
| Hemoglobin | 160 g/L | 130 - 170 g/L |
| Thrombocytes | 313 10 ⁹ /L | 150 - 410 10 ⁹ /L |
| Glucose | 5,6 mmol/L | 3,6 - 6,1 mmol/L |
| AST (GOT) | 0,46 ukat/L | < 0,58 ukat/L |
| ALT (GPT) | 0,24 ukat/L | < 0,74 ukat/L |
| Gamma GT | 0,32 ukat/L | < 0,92 ukat/L |
| Alkaline phosphatase | 1,57 ukat/L | < 2,15 ukat/L |
| Lipase | 1,11 ukat/L | 0 - 1 ukat/L |
| Amylase | 0,48 ukat/L | 0 - 1,67 ukat/L |
| CRP | 387,6 mg/L | < 5 mg/L |
| Bilirubin (total) | 11 umol/L | 3 - 22 umol/L |
| Bilirubin (direct) | 7 umol/L | 0 - 7 umol/L |
| Triglycerides | 0,94 mmol/L | 0,6 - 1,7 mmol/L |
| Calcium | 1,78 mmol/L | 2,1 - 2,6 mmol/L |
| Ethanol 0,5 % CDT | 2,71 % | 0 - 2,5 % |

Legend: CRP = C-reactive protein, CDT = carbohydrase-deficient transferrin.

Source: Emergency Center, Novo mesto General Hospital, Novo mesto, Slovenia. 2023.

The patient was discharged on the tenth day of hospitalization with scheduled follow-up appointments.

DISCUSSION

The sensitivity of lipase in detecting acute pancreatitis ranges up to 100%. Normal lipase levels are more likely at the early or later stages of the condition. Levels rise within 3 to 6 hours of the onset of acute pancreatitis, peak within 24 hours, and may stay elevated for up to 2 weeks (5, 6).

Normal lipase levels in acute pancreatitis can be explained by various factors, including the timing of

lipase measurement, the degree of pancreatic injury, and individual variations (7-12).

Alcoholic pancreatitis, as suspected in our patient, typically presents with elevated lipase levels due to pancreatic inflammation and cellular injury caused by chronic alcohol consumption. This process involves disruption of cellular membranes, impairment of mitochondrial function, and promotion of calcium signaling abnormalities, all contributing to pancreatic cell damage and dysfunction (1, 7).

In cases of acute alcoholic pancreatitis, pre-existing chronic damage to the pancreas, such as fibrosis and acinar cell loss, can further complicate enzyme release, resulting in normal lipase levels despite ongoing inflammation (1, 7). This theory is less likely based on our patient's clinical and radiographic findings, which did not indicate chronic pancreatic changes.

Another explanation is that during the early stages of the disease, serum lipase levels may not accurately reflect ongoing pancreatic injury before significant acinar destruction occurs (8, 9). However, lipase levels measured later in the disease course or during periods of lower pancreatic enzyme activity may appear normal or minimally elevated (5, 10). The first theory was deemed unlikely because the patient did not experience a rise in lipase during hospitalization. Still, the latter could have been the case in our patient, where the peak lipase elevation was missed.

In some cases, particularly in patients with severe necrotizing pancreatitis, serum lipase levels might paradoxically remain within the normal range despite significant pancreatic damage (11, 12). Additionally, while hypertriglyceridemia can cause normal lipase levels in acute pancreatitis cases, this theory was unlikely in our patient, as he had normal triglyceride levels (9).

Despite our patient's normal lipase levels, his clinical symptoms, elevated inflammatory markers, and imaging evidence consistent with pancreatitis supported the diagnosis (1, 9, 13). His lipase levels remained low during hospitalization, consistent with literature reports and recommendations that serially trending enzymes have no clinical utility. If clinical suspicion is high and abdominal imaging shows signs of acute pancreatitis, it should be treated as such (10).

CONCLUSION

This case highlights the diagnostic challenge of lipase-negative pancreatitis. Despite normal lipase levels, the patient's clinical presentation and imaging supported the diagnosis of acute pancreatitis. A comprehensive assessment integrating clinical, laboratory, and imaging data is crucial for accurately diagnosing and managing patients with abdominal pain.

REFERENCES

1. Szatmary P, Grammatikopoulos T, Cai W, Huang W, Mukherjee R, Halloran C, et al. Acute Pancreatitis: Diagnosis and Treatment. *Drugs*. 2022;82(12):1251-76.
2. Banks PA, Bollen TL, Dervenis C, Gooszen HG, Johnson CD, Sarr MG, et al. Classification of acute pancreatitis--2012: revision of the Atlanta classification and definitions by international consensus. *Gut*. 2013;62(1):102-11.
3. Wang YY, Qian ZY, Jin WW, Chen K, Xu XD, Mou YP, et al. Acute pancreatitis with abdominal bloating and distension, normal lipase, and amylase: A case report. *Medicine (Baltimore)*. 2019;98(15):e15138.
4. Shah AM, Eddi R, Kothari ST, Maksoud C, DiGiacomo WS, Baddoura W. Acute pancreatitis with normal serum lipase: a case series. *JOP*. 2010;11(4):369-72.
5. Ismail OZ, Bhayana V. Lipase or amylase for the diagnosis of acute pancreatitis? *Clin Biochem*. 2017;50(18):1275-80.
6. Shahbazi M, Qudsiya Z, Fahel A, Amini A, Tanoli T. First Reported Case of Dulaglutide-Induced Acute Pancreatitis With Normal Serum Lipase Level. *Cureus*. 2023;15(6):e40576.
7. Apte MV, Pirola RC, Wilson JS. Mechanisms of alcoholic pancreatitis. *J Gastroenterol Hepatol*. 2010;25(12):1816-26.
8. Singh A, Shrestha M, Anand C. Acute pancreatitis with normal amylase and lipase--an ED dilemma. *Am J Emerg Med*. 2016;34(5):940 e5-7.
9. Nadhem O, Salh O. Acute Pancreatitis: An Atypical Presentation. *Case Rep Gastroenterol*. 2017;11(2):359-63.
10. Agrawal A, Parikh M, Thella K, Jasdanwala S. Acute pancreatitis with normal lipase and amylase: an ED dilemma. *Am J Emerg Med*. 2016;34(11):2254 e3- e6.
11. Sudarsanam H, Ethiraj D, Govarthanan NK, Kalyanasundaram S, Chitra SA, Mohan S. COVID-19 Associated Acute Necrotizing Pancreatitis with Normal Serum Amylase and Lipase Levels: Report of an Unusual Finding. *Oman Med J*. 2021;36(5):e304.
12. Lankisch PG, Burchard-Reckert S, Lehnick D. Underestimation of acute pancreatitis: patients with only a small increase in amylase/lipase levels can also have or develop severe acute pancreatitis. *Gut*. 1999;44(4):542-4.
13. Mathur AK, Whitaker A, Kolli H, Nguyen T. Acute pancreatitis with normal serum lipase and amylase: a rare presentation. *J Pancreas (Online)* 2016 Jan;17(1):98-101.
14. Lankisch PG, Apte M, Banks PA. Acute pancreatitis. *Lancet*. 2015;386(9988):85-96.