

MALIGNANT CATARRHAL FEVER IN AMERICAN BISON (*Bison bison*) IN SLOVENIA

Jože Starič¹, Jožica Ježek¹, Vasilij Cociancich², Mitja Gombač², Peter Hostnik³, Ivan Toplak³

¹Clinic for Ruminants, Veterinary Faculty, University of Ljubljana, Cesta v Mestni log 47, ²Institute of Pathology Forensic and Administrative Veterinary Medicine, ³Institute for Microbiology and Parasitology, Virology Unit, Veterinary Faculty, University of Ljubljana, Gerbičeva 60, Ljubljana, Slovenia

*Corresponding author, E-mail: joze.staric@vf.uni-lj.si

Summary: Malignant catarrhal fever (MCF) is a ubiquitous disease of cattle and other ruminants caused by ovine herpesvirus-2 (OvHV-2) in Europe and other continents and alcelaphine herpesvirus-1 (AIHV-1) in Africa. In March 2010 MCF was recognized in small private zoological garden in three American bison (*Bison bison*) imported from Vienna. They were housed in an enclosure next to llamas, goats and domestic sheep, with direct contact between all mentioned species. Typical clinical signs of the acute head and eye form of MCF were observed, with especially inflammation of conjunctives, oral and nasal mucosa and marked depression. Mortality was 100%. Necropsy findings in one bison were consistent with MCF. Acute ulcerative abomasitis and omasitis, acute hemorrhagic enterotyphilitis, acute purulent bronchitis and moderate emaciation were found. The histopathology revealed mixed lymphohistiocytic and neutrophilic vasculitis in the brain, meninges, liver, spleen, heart, lungs and mixed lymphohistiocytic and neutrophilic hepatitis and adrenalitis. OvHV-2 DNA was detected post-mortem in tissue samples by PCR. Direct sequencing of the PCR product confirmed 100% nucleotide identity to OvHV-2 strain BJ1035 and closely related to two OvHV-2 positive sheep samples collected in 2007. These are the first case of MCF confirmed by laboratory diagnostic methods in Slovenia. Furthermore, these are also the first cases of MCF in American bison in Slovenia.

Key words: *coryza gangraenosa bovum*; Europe; ovine herpesvirus-2; sheep

Introduction

Malignant catarrhal fever (MCF) is a ubiquitous and usually fatal lymphoproliferative disease of over 30 species of wild and domestic ruminants including cattle, deer, bison, water buffalo, moose and pigs. The most susceptible species are the American bison (*Bison bison*) and many deer species with rapidly progressing acute clinical signs followed by death in a few days (1, 2).

Based on the reservoir hosts in which the virus was originally detected, the MCF-causing viruses are named as alcelaphine herpesvirus type 1 (AIHV-1) from wildebeest (*Connochaetes taurinus*), ovine herpesvirus type 2 (OvHV-2) from domestic sheep and caprine herpesvirus type 2 (CpHV-2) detected in domestic goats and a pig in Germany (3, 4). MCF-causing viruses are members of genus *Macavirus*, subfamily *Gammaherpesvirinae*, family *Herpesviridae* (5). They all induce disease with similar clinical signs and pathology in susceptible species. Death can occur within a few days or up to several weeks after the onset of clinical signs (6).

A common form of the disease is sheep-associated MCF (SA-MCF), which was initially observed in Europe, but is found worldwide wherever sheep and other MCF-susceptible species are kept together. Domestic and wild sheep are natural reservoir species of OvHV-2 and do not exhibit any clinical signs of infection, whereas the disease is dramatic and usually fatal in MCF-susceptible species. Another form of the disease is wildebeest-associated MCF (WA-MCF), which is a particular problem in Eastern and Southern Africa and in zoological gardens (2).

The virus is spread by nasal secretions. Adult sheep shed OvHV-2 sporadically with a short-lived episode usually lasting less than 24 hours, while new-born lambs are not the source of infection. Contrary to this observation, new-born wildebeest calves are infected and shed AIHV-1 continuously until 3-4 months of age (2). Respiratory tract of sheep is the primary target for OvHV-2 during natural infection (2, 7). OvHV-2 predominantly replicates in cells of nasal turbinates when naturally infected sheep experience intensive shedding episodes (8). The virus establishes a latent infection in the lymphocytes. In cattle herds, outbreaks are sporadic with few animals being affected, but outbreaks in American bison herds can affect up to 100% of animals (2, 9). A risk factor for cattle and bison infection is usually close cohabitation with domestic sheep (2, 7).

Laboratory confirmation of a clinical diagnosis of MCF is important and necessary, because clinical signs of other enteric or diseases with oral lesions are similar (2, 13). Such differential diagnoses are blue tongue, vesicular stomatitis, BVD (mucosal disease), severe form of IBR, foot and mouth disease, rinderpest and encephalitis of other aetiology. Virus isolation test for MCF caused by OvHV-2 is not useful, because OvHV-2 has never been propagated in monolayer cell culture, while AIHV-1 replicates in bovine turbinate cells (14, 15). Specific anti-AIHV-1 or anti-OvHV-2 monoclonal antibodies or conjugates are not available commercially. A direct ELISA has been developed for detection of specific antibodies, but in the acute form of the disease, the animals usually do not manage to develop antibodies before death (2). Diagnosis in MCF-susceptible species has benefited from recent development in molecular virology (16). PCR assays have been developed for the detection of OvHV-2 and AIHV-1 viral DNA (13, 17).

In Slovenia MCF has been diagnosed by clinicians and pathologists, but it had never been confirmed by a specific diagnostic method. This paper describes three field cases of MCF in American bison (*Bison bison*).

Case description

History

The disease outbreak was suspected in a herd of three American bison (*Bison bison*) (age 3, 4 and 5 years) in a small private zoo located about 30 km east of Ljubljana. All three animals were bought from a foreign Zoo two years before the outbreak. They were housed in a pen of about 200 m², next to a pen with llamas (*Lama glama*), domestic crossbreed goats (*Capra aegagrus hircus*) (buck and doe) and Istrian Pramenka sheep (*Ovis aries aries*) (ram, ewe and their four month old lamb) and an enclosure of wild boars (*Sus scrofa*). A new pair of sheep was introduced to the zoo one year after the arrival of the bison, and had a lamb after their arrival. The bison had no contact with sheep before this introduction. All pens were constructed in a manner that allowed nose to nose contact between animals from neighbouring pens. The zoo also housed two roe deer (*Capreolus capreolus*), three ibex (*Capra ibex*) and rabbits (*Oryctolagus cuniculus*), but these animals were in another part of the zoo that had no direct contact with the bison, sheep and goats. Before the outbreak of MCF, the three bison were healthy and in good physical condition.

Clinical findings

In March 2010 all three American bison sickened one after another with 5 to 7 day intervals between death of one and occurrence of disease in another. The first animal to get sick was the youngest (3y) and the last was the 5 year old bison. The disease followed a very similar course in all three animals. In the first stage (2 days), the bison ate and drank less than usual and ruminated less. They were also presenting signs of mild colic, as they started to kick at the belly and were less agile. In the second stage (2 to 5 days) increased mucosal discharge appeared on the nares and excessive salivation was noted. The animals became progressively more depressed and showed

little interest in food. According to the owner's observations the affected animals also drank and consequently urinated more often than usually. Their corneas became progressively more opaque, blepharospasm and photophobia were noted and in 2 to 7 days corneas were completely cloudy and the animals became apparently blind, which was the case in the two animals that died naturally. At this stage the animals were completely anorexic; often dipped their mouths in water but did not drink. They were hyperaesthetic, but most of the day they were lying down, salivating excessively and had copious mucosal nasal and ocular discharge. Breathing was laboured and grunting notable. Obvious reluctance to walk was noted, as well as lethargy, ataxia and hypermetria. In the following two days the 3 and 4 year old bison that died naturally stood up and lay down often (almost every hour), kicked at their pectoral region with front feet and had seizures until finally they hardly stood up, swayed while standing and when they attempted to walk, fell down and did not attempt to stand up again. Before death, the 4 year old bison threw its head vigorously on the flooring and calmed down. The three year old animal was found dead in the morning. During the last week of its life the 4 year old bison did not eat at all, did not pass any manure or urinate. There was also much less salivation and nasal mucosal discharge during the last few days of the animals' life. Nasal erosions were also noted in the 4 year old bison at this time.

The youngest bison was treated with yeast and probiotics for indigestion with no success. The 4 year old bison was treated by a local vet, who sedated the animal and recorded 40.5°C body temperature and treated the animal for pneumonia with antibiotics and anti-inflammatory drugs. The antibiotic therapy was repeated 2 days after the first treatment. The therapy empirically improved the clinical status for a day (improved demeanour and appetite). Afterwards, the disease progressed rapidly; the bison appeared completely blind, it started to run into the fence and died within 24 hours. The last bison, which started to exhibit signs of disease just 5 days after the death of the 4 year old animal, was euthanized when it started to present corneal opacity and severe clinical disease 5 days after the onset. Time from the onset of the disease until death was 7 and 14 days in the 3 and 4 year bison, respectively.

Laboratory diagnosis

Five days after detection of clinical disease, a five-year old American bison was euthanized and immediately submitted for a post-mortem examination.

Necropsy

Specimens of the brain, spleen, liver, lungs, myocardium, adrenal gland and kidneys were fixed in 10% neutral buffered formalin for 24 hours, routinely embedded in paraffin, sectioned at 4 µm and stained with hematoxylin and eosin (HE).

At the necropsy of the five-year old bison that was euthanized, moderate emaciation, mild corneal opacity, acute ulcerative end erosive omasitis and abomasitis, moderate haemorrhagic enterotyphlitis and cystitis and acute purulent bronchitis were observed. The liver was moderately congested; meninges were severely congested and oedematous. Numerous petechial haemorrhages were scattered through the renal cortex and spleen capsule. No lesions in the upper alimentary and respiratory tracts were noticed and lymph nodes were apparently normal.

Histologically, a mild to moderate mixed lymphohistiocytic and neutrophilic infiltrate was observed in the adventitia and media of numerous veins and arteries in the brain and meninges, liver, spleen, myocardium and lungs. In the liver, a severe mixed lymphohistiocytic and neutrophilic periportal hepatitis and small multifocal necroses of liver parenchyma were observed. Small dense multifocal accumulations of lymphocytes and macrophages and a severe parenchymatous degeneration were seen in the kidneys. Meninges were moderately oedematous and mildly to moderately infiltrated with lymphocytes, macrophages, neutrophils and fibrin, compatible with meningitis. Small lymphocytic aggregates and numerous small haemorrhages were noticed in the brain. A severe diffuse mixed lymphohistiocytic, neutrophilic and eosinophilic infiltrate was found in the adrenal cortex. The spleen was moderately atrophic and a large amount of haemosiderin was seen in the red pulp. Acute interstitial pneumonia and mild purulent bronchiolitis with severe diffuse pulmonary emphysema were also diagnosed.

Molecular diagnostics

Tissue samples of lymph nodes, spleen and kidney were collected for molecular diagnosis and genetic characterisation of the suspected MCF virus.

Blood samples of three sheep that were in contact with bison and showed no clinical signs of disease, were collected two weeks after the death of the five-year old bison.

Blood, lymph node, spleen and kidneys were kept frozen at -60 °C prior to DNA extraction. Total DNA was extracted from positive controls and unknown tissue samples using QIAamp® DNA Mini Kit (Qiagen, Germany) according to the manufacturer's instructions.

PCR and primers for detection of SA-MCF (OvHV-2)

Oligonucleotide primers 556 and 775 (2) for the detection 422-bp fragment in ORF 75 gene of OvHV-2 were used. Positive control DNA extracts were prepared from archived blood samples of healthy sheep containing OvHV-2, negative control contained sterile distilled water. Two µl of the total DNA extract were used as the target in subsequent PCR amplifications. PCR was carried out in the final volume of 25 µl using 0.5 µl Platinum Taq DNA polymerase (Invitrogen, Germany), 2.5 µl 10 x PCR buffer, 1.0 µl 50mM MgCl₂, 20 pmol of each primer and 1 µl of dNTP mix (containing 10 mM of each dNTP). After denaturation in a T1 thermal cycler (Biometra, Germany) at 95°C for 5 min, the reaction mixtures were subjected to thermal cycling for 40 ramp cycles each of 94°C for 1 min, 60°C for 1 min and 72°C for 2 min. A time delay of 7 min at 72°C for was included prior to a 4°C soak. The amplified PCR products were detected by agarose gel electrophoresis. Total reaction volume of 15 µl was loaded onto a 2% (w/v) agarose gel containing ethidium bromide (0.5 µl/ml), and the PCR products were visualized under UV transilluminator.

Direct sequencing of PCR products

Four PCR products were used as templates in cycle sequencing reactions primed with the 556 and 775 primers, using the MacroGen sequencing service (MacroGen, South Korea). Individual

nucleotide (nt) sequences were assembled and proofread using the SeqMan and EditSeq programs in the DNASTAR program package (DNASTAR Inc., Madison, WI, USA). For each sample, 360 nucleotide long sequences were aligned with the published data using BLAST (available at <http://www.ncbi.nlm.nih.gov/>) at the National Centre for Biotechnology Information (NCBI). Multiple sequence alignment was carried out using the sequence analysis software (DNASTAR Inc., Madison, WI, USA).

Results

DNA extracted from the bison tissue samples (lymph node, spleen and kidneys) and from the three sheep blood samples was used in PCR amplification. The PCR product of predicted size (422 bp) was detected in lymph node, spleen and kidneys of the euthanized bison, while all three samples collected from sheep in contact with the bison were negative. The PCR products of appropriate size, including two OvHV-2 positive sheep samples collected in 2007, which were used as positive controls, were directly sequenced. The nucleotide sequence for three samples (one bison and two sheep) was determined, confirming the specificity of the amplification for OvHV-2. The three sequences of 360 nucleotides of partial ORF 75 were compared to each other and to the published sequences of OvHV-2 (Figure 1). The observed homology in nucleotide sequences between Bison/2010 and the strain BJ1035 in GenBank was 100% and closely related (99.7%) to strains 1905ZIEGEKY and Sheep 5/2007, which was detected in a sample of asymptomatic infected sheep collected in 2007 in Slovenia. Another sequence, Sheep 1/2007 was closely related (99.7%) to strains 27846ELCH and 25034REH in GenBank and revealed three and four nucleotide differences to strains Sheep 5/2007 and Bison/2010, respectively. On amino acid level the 120 aa sequences were 100% identical between Bison/2010, BJ1035, 1905ZIEGEKY and Sheep 5/2007, while the sequence Sheep 1/2007 was 100% identical with 27846ELCH, 25034REH, 25843HIRSCH, 15821BISON, 25058ZIEGEH and 21114HIRSCH (data not shown). This data confirmed that the bison was infected with OvHV-2 and died of MCF. A sequence detected in sheep in 2007 was closely related to the strain detected in the bison.

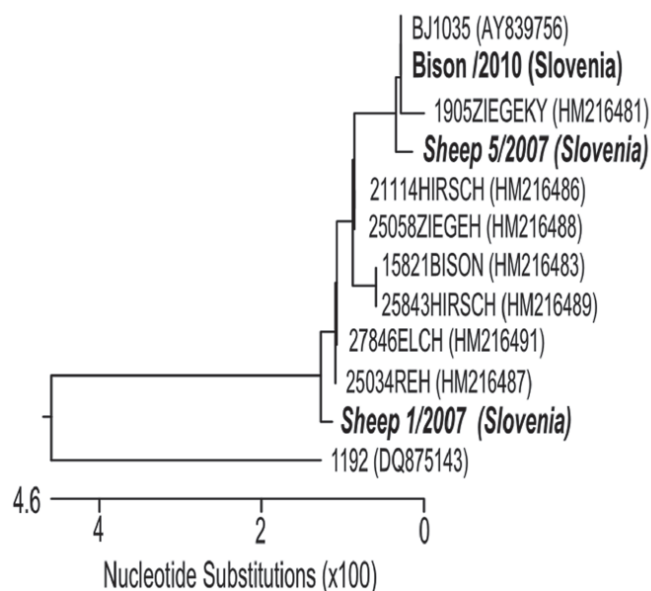


Figure 1: Phylogenetic analysis of partial tegument protein gene (360 nucleotides of ORF 75: genome positions of nucleotides 121137-121496, numbering according to OvHV-2 strain BJ1035, AY839756)

The tree was constructed from aligned nucleic acid sequences of three Slovenian OvHV-2 (one American bison sample and two sheep samples in bold-italic from this study) and nine OvHV-2 sequences of closely related strains found in GenBank. The original names and GenBank accession numbers are presented for each sample. The dendrogram represents a tree constructed using MegAlign program of sequence analysis software Lasergene®.

Discussion

The American bison in this study exhibited predominantly the clinical signs of the head and eye form of MCF. After the 5th day of the disease nasal discharge was more intensive, similarly as reported previously (11). Unlike some other investigators (6, 11, 12, 18), we did not note diarrhoea, dysentery or melena. The disease was acute, ending with death in a week and two weeks in the 3 and 4 year old bison, respectively. According to literature, clinical signs appear most often about a month and half to two months (but could also be much latter) after natural infection in the American bison (6, 7). Since the ewe and ram in the next pen were there for more than a year, we speculate that viral shedding appeared either in the periparturient period in the ewe or during the first 3 months of the lamb's life.

Gross lesions described in this case were consistent with other reports of acute MCF in bison, although no alteration of the upper alimentary tract

were observed, which was reported in most cases of MCF in bison (7, 11, 12, 18, 19). A reason for this could be that the disease had not yet progressed to that point at the time of euthanasia, which was the fifth day after the first clinical sign appeared. The most prominent histological change – vasculitis, present in the majority of the examined organs, was of a mixed lymphohistiocytic and neutrophilic form, reported before only in bison experimentally infected with blood from a calf with MCF (19). Vasculitides described in other cases of acute MCF in bison were lymphocytic (11, 12, 18). Meningitis and periportal hepatitis reported by two authors (12, 19) were lymphocytic, whereas in our case they were mixed lymphohistiocytic and neutrophilic with an additional fibrinous component, found only in the meninges. Multifocal lymphocytic nephritis was also reported (19), whereas multifocal lymphocytic encephalitis and adrenalitis diagnosed in our bison, was not reported by other authors (7, 11, 12, 18, 19).

For the first time in Slovenia, the application of a specific PCR assay has enabled the detection of OvHV-2 DNA in clinical samples of SA-MCF in American bison. The usefulness of PCR method for the confirmation of virus after the suspicion of MCF in American bison was proved. The direct sequencing confirmed the specificity of PCR products and nucleotide comparison with previously published strains in GenBank determined nucleotide identity (2). Detection of similar strain in bison and sheep collected in Slovenia in 2007 is confirming that this strain

has been circulating in Slovenia for several years. Another detected positive sample from sheep is very similar but not identical to the strain Bison/2010, confirming the circulation of different strains of OvHV-2 in the region.

Considering the ability of herpes viruses to cause latent infections, it is not surprising that OvHV-2 DNA was not detected in the blood of the tree sheep in contact with the bison, since the samples were collected two weeks after the last bison died and these animals were probably no longer viremic, or the quantity of the virus was below the limit of detection.

Conclusion

This was the first case of acute, 100 % fatal MCF in American bison in Slovenia confirmed by laboratory methods, and also one of the few reported in Europe. High susceptibility and mortality of American bison to MCF was confirmed. The source of infection was probably a group of sheep housed in a pen next to the bison in a small zoo. We firmly advise not to keep sheep in the same facility as American bison in zoos, breeding operations, fairs or sales.

Acknowledgement

This research was financially supported by the Slovenian Research Agency; program P4-0092 (Animal health, environment and food safety).

References

1. Berezowski JA, Appleyard GD, Crawford TB, et al. An outbreak of sheep-associated malignant catarrhal fever in bison (*Bison bison*) after exposure to sheep at a public auction sale. *J Vet Diagn Invest* 2005; 17: 55–8.
2. Russell GC, Stewart JP, Haig DM. Malignant catarrhal fever: a review. *Vet J* 2009; 179: 324–35.
3. Chmielewicz B, Goltz M, Ehlers B. Detection and multigenic characterization of a novel gammaherpesvirus in goats. *Virus Res* 2001; 75: 87–94.
4. Li H, Keller J, Knowles DP, Crawford TB. Recognition of another member of the malignant catarrhal fever virus group: an endemic gamma-herpesvirus in domestic goats. *J Gen Virol* 2001; 82: 227–32.
5. Davison AJ, Eberle R, Ehlers B, et al. The order Herpesvirales. *Arch Virol* 2009; 154: 171–7.
6. Anderson IE, Buxton D, Campbell I, et al. Immunohistochemical study of experimental malignant catarrhal fever in rabbits. *J Comp Pathol* 2007; 136: 156–66.
7. Li H, Taus NS, Jones C, et al. A devastating outbreak of malignant catarrhal fever in a bison feedlot. *J Vet Diagn Invest* 2006; 18: 119–23.
8. Cunha CW, Traul DL, Taus NS, et al. Detection of ovine herpesvirus 2 major capsid gene transcripts as an indicator of virus replication in shedding sheep and clinically affected animals. *Virus Res* 2007; 132: 69–75.
9. Schultheiss PC, Collins JK, Spraker TR, DeMartini JC. Epizootic malignant catarrhal fever in three bison herds: differences from cattle and association with ovine herpesvirus-2. *J Vet Diagn Invest* 2000; 12: 497–502.
10. Brown CC, Baker DC, Barker IK. Alimentary system. In: Maxie MG, ed. *Jubb, Kennedy and Palmer's pathology of domestic animals: vol. 2*. 5th ed. New York : Elsevier Saunders, 2007: 152–8.
11. O'Toole D, Li H, Sourk C, et al. Malignant catarrhal fever in a bison (*Bison bison*) feedlot, 1993–2000. *J Vet Diagn Invest* 2002; 14: 183–93.
12. Schultheiss PC, Collins JK, Austgen LE, DeMartini JC. Malignant catarrhal fever in bison, acute and chronic cases. *J Vet Diagn Invest* 1998; 10: 255–62.
13. Cunha CW, Otto L, Taus NS, et al. Development of a multiplex real-time PCR for detection and differentiation of malignant catarrhal fever viruses in clinical samples. *J Clin Microbiol* 2009; 47: 2586–9.
14. Dewals B, Boudry C, Farnir F, et al. Malignant catarrhal fever induced by alcelaphine herpesvirus 1 is associated with proliferation of CD8 T cells supporting a latent infection. *PLoS ONE* 2008; 3(2): e1627 (8 p.) <http://journals.plos.org/plosone/article?id=10.1371/journal.pone.0001627> (June 2015)
15. Rosbottom J, Dalziel RG, Reid HW, Stewart JP. Ovine herpesvirus 2 lytic cycle replication and capsid production. *J Gen Virol* 2002; 83: 2999–3002.
16. Baxter SIF, Pow I, Bridgen A, Reid HW. PCR detection of the sheep-associated agent of malignant catarrhal fever. *Arch Virol* 1993; 132: 145–9.
17. Traul DL, Elias S, Taus NS, et al. A real-time PCR assay for measuring alcelaphine her-

pesvirus-1 DNA. J Virol Meth 2005; 129: 186–90.

18. Campolo M, Lucente M, Mari V, et al. Malignant catarrhal fever in a captive American bison (*Bison bison*) in Italy. J Vet Diagn Invest 2008; 20: 843–6.

19. Liggitt HD, DeMartini JC. The pathomorphology of malignant catarrhal fever. II. Multisystemic epithelial lesions. Vet Pathol 1980; 17: 73–83.

MALIGNA KATARALNA MRZLICA PRI AMERIŠKEM BIZONU (*Bison bison*) V SLOVENIJI

J. Starič, J. Ježek, V. Cociancich, M. Gombač, P. Hostnik, I. Toplak

Povzetek: Maligna kataralna mrzlica (MCF) je vseprisotna bolezen goveda in drugih prežvekovalcev, ki jo povzroča ovčji herpesvirus-2 (OvHV-2) v Evropi in na drugih celinah ter alcelafini herpesvirus-1 (ALHV-1) v Afriki. V marcu 2010 je bila MCF ugotovljena v majhnem zasebnem živalskem vrtu pri treh ameriških bizonih (*Bison bison*), uvoženih z Dunaja. Bili so nastanjeni v ogradi poleg lam, koz in domačih ovc, z neposrednim stikom z vsemi omenjenimi vrstami. Opazili so tipične klinične znake akutne oblike MCF glave in oči, še posebej vnetje vek, ustne in nosne sluznice ter prepoznavne depresije. Umrljivost je bila 100-odstotna. Ugotovitve obdukcije enega od bizonov so bile skladne z MCF. Ugotovljen je bil akutni ulcerozni abomasitis in omasitis, akutni hemoragični enterotifilitis, akutni gnojni bronhitis in zmerno hujšanje. Histopatološka preiskava je razkrila mešani limfohistiocitični in nevtrofilni vaskulitis v možganih, možganskih ovojnicah, jetrih, vranici, srcu, pljučih in mešani limfohistiocitični in nevtrofilni hepatitis ter adrenalitis. DNK OvHV-2 je bila odkrita *post mortem* z uporabo metode PCR v tkivnih vzorcih. Neposredno določanje zaporedja baznih parov produkta PCR je potrdilo 100-odstotno nukleotidno identiteto OvHV-2 seva BJ1035 in tesno povezanost z dvema OvHV-2 pozitivnima vzorcema ovc, zbranimi v letu 2007. Gre za prvi primer MCF, potrjen s pomočjo laboratorijskih diagnostičnih metod, v Sloveniji. Poleg tega gre tudi za prve primeri MCF pri ameriških bizonih v Sloveniji.

Ključne besede: maligna kataralna mrzlica; ovčji herpes virus 2; Evropa; ovca