

A "skin helix" flap to correct circular skin loss on the nasal ala

A. Ascari-Raccagni, A. Dondas, M. G. Righini, and G. Trevisan

S U M M A R Y

The surgical treatment of circular skin defects localized on the nasal ala is always extremely challenging. Such lesions can be repaired by using full-thickness skin graft or skin flaps, normally with poor aesthetic outcomes. Skin grafts do not achieve satisfactory aesthetic results because of the unnatural look of the transplanted skin. If a skin flap is chosen, the choice of which one to employ among the many available must be made very carefully in order to obtain the best possible aesthetic outcome. This article describes the clinical case of a localized tumor on the nasal right ala that was surgically removed and satisfactorily treated by employing a "skin helix flap."

Introduction

K E Y W O R D S

circular skin defect, skin helix flap, spiral flap

The frequency of skin tumors localized on the nasal ala is very high and their surgical removal normally causes a circular skin loss that is extremely difficult to repair. The nasal ala is a convex area, horizontally stretched, outlined at the top by an elliptical furrow, which continues and deepens laterally on the naso-labial furrow. In order to repair such a defect, a full-thickness skin graft or a skin flap can be used. If a skin graft is chosen, the aesthetic outcome will be very poor due to the color and texture of the transplanted skin, always very different from the quality of the removed skin. Much better outcomes can be obtained by widening the excision in order to contain the entire nasal ala skin; in fact, the final outcome of a skin graft of an entire aesthetic unit has a much more natural appearance (1).

Even the choice of a skin flap in order to repair a defect on this area remains challenging. An island flap does not always guarantee the best mobility (2), which could be increased with a few simple modifications (3) in order to increase the flap capability, adapt to the several skin layers (4), or better correct a circular defect (5). A rotary flap from the cheek, a modified Texier flap (6), or a pedicle flap performed at two different times (7) could represent a good option, although often with a poor aesthetic outcome; even the "jigsaw advancement" flap could, in selected cases, achieve satisfactory results (8).

The "skin helix" flap is an extremely versatile flap that can be employed on several different body sites (9), mainly on the trunk and the buttocks, but also on the face to correct circular skin losses, and this flap can be also used to treat nasal ala losses.

Materials and methods

The "skin helix" flap comprises in a single flap the rotation, advancement, and sub-cutaneous island flap components and it is suitable for correcting circular skin losses without having to change the shape. The flap can also be suitable for very large lesions on the abdomen, hips, buttocks, sacral area, and all areas characterized by thick and well-vascularized subcutaneous tissue.

Once the cutaneous lesion has been removed with a resulting circular skin loss, the flap is drawn with a spiral shape, beginning from the lesion border and gradually widening up to a width as long as the defect radius; the spiral length can be about as long as the skin-loss diameter. The flap, once it has been incised, is totally undermined in its distal half, whereas it is left intact in the half close to the deep vascular pedicle. At this point, the flap is advanced and rotated as a helix, easily covering the skin loss.

Case report

We present here the case of an 80-year-old patient, in general good health, who had been treated for almost a year for the appearance of a well-defined nodular translucent lesion localized on the right nasal area (Fig. 1). At the patient's first visit a nodular basal cell carcinoma was diagnosed and surgery for its removal was scheduled with local anesthesia.

Taking into consideration the cheek medial portion mobility, vascularization, cutaneous thickness,

skin-loss localization in relation to the naso-labial furrow, and the relationship between the nasal ala convexity and the nearby cutaneous furrows, a "skin helix" flap was chosen (Fig. 2). After having infiltrated the surgical intervention area with local anesthesia (lidocaine 2% diluted, buffered with sodium bicarbonate and added adrenaline) we surgically removed the lesion with a 5 mm margin of healthy skin, obtaining a circular skin loss about 15 mm in diameter.

We prepared a flap with an elliptical shape from the front of the skin loss, gradually increasing its width to be equal to the lesion radius, with its length similar to its diameter. The distal part of the flap was totally mobilized from the sub-skin with complete undermining, whereas the proximal portion was mobilized with an island flap, retaining the subcutaneous vascular plexus (Fig. 3). The flap apex was advanced, rotated, and fastened backward up to its final position, suturing all free borders with a non-absorbable single-filament suture (Surgipro 5.00). Only on the ellipse upper portion, on the right corner of the nose, was a small discharge triangle with an upper apex removed and sutured in order to maintain the nasal ala in its normal position (Fig. 4).

Discussion

In our clinical case the "skin helix" flap represented a good option inasmuch as it allowed us to not turn a circular lesion into a size 4 lesion, giving us better outcomes than those we could have obtained with a skin graft. It also allowed us to respect the direction of

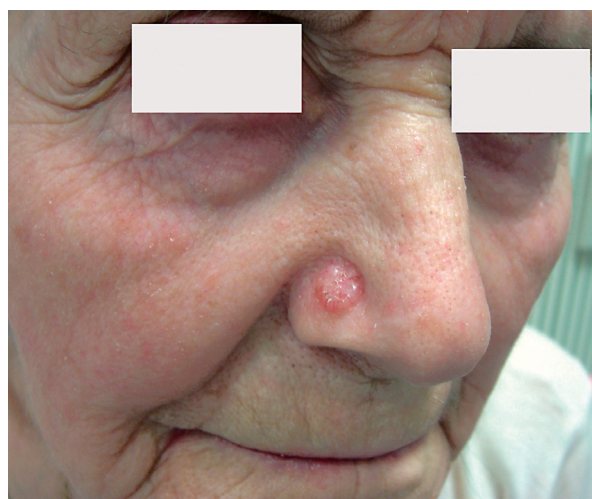

Figure 1. Nodular basal cell carcinoma localized on the nasal ala.

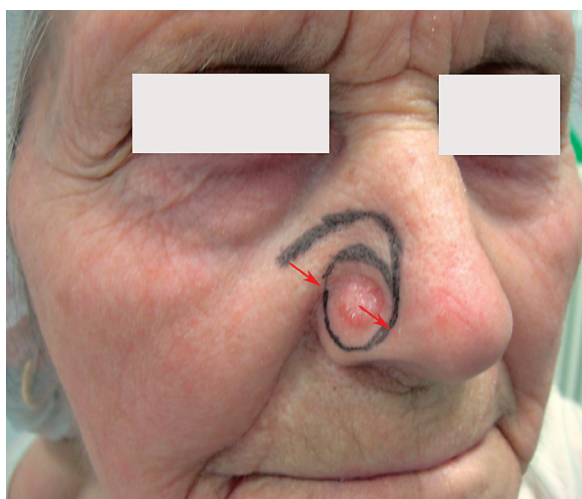

Figure 2. Lesion to be removed in a circle, with larger borders of healthy skin.

The "skin helix" flap with an elliptical flap widens from the lesion border to attain the width of the lesion radius (see red arrows).

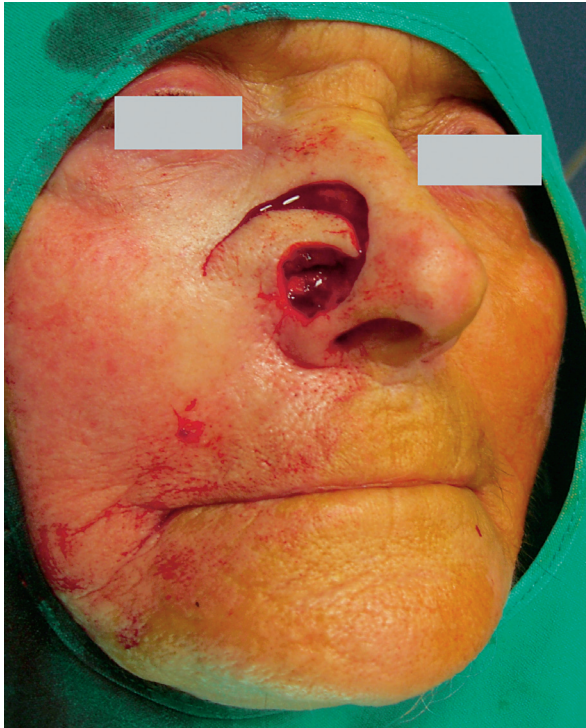

Figure 3. The "skin helix" flap already mobilized and ready for advancement, rotation, and tailspin to repair the circular defect.

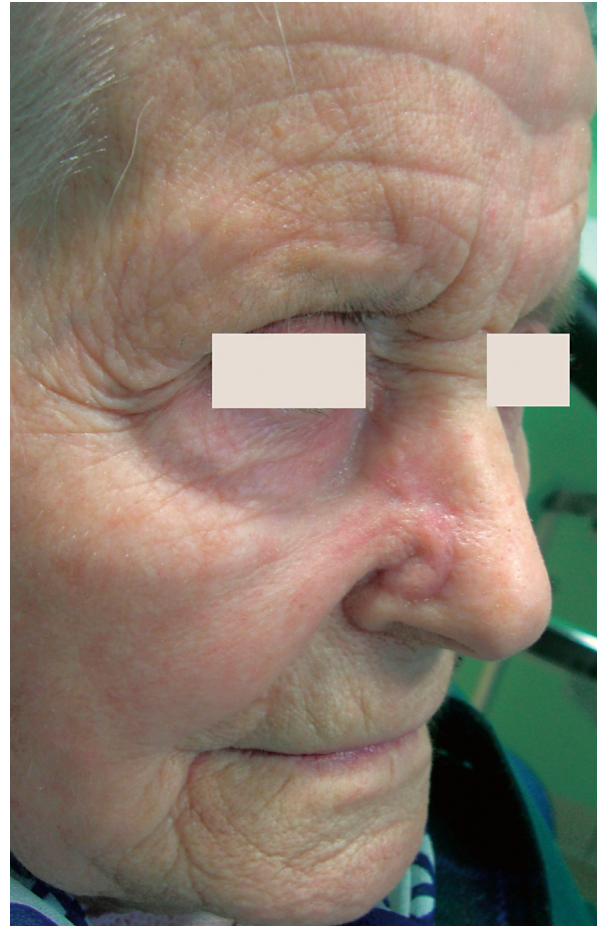


Figure 5. Final outcome of the "skin helix" flap only 20 days after surgery.

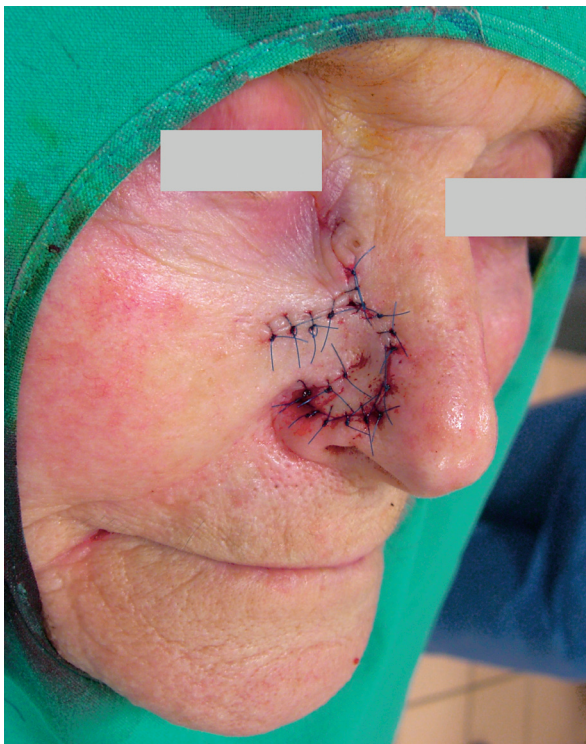

Figure 4. The "skin helix" flap in its final position already sutured; note the small discharge triangle already sutured on the right corner of the nose.

all the different cutaneous layers with its distal portion that perfectly reconstructed the stretched convexity of the nasal ala and with part of the sutures naturally covered by the naso-labial furrow.

The weakness of the "skin helix" flap is represented by its length and its extremely thin apex, but in the case described here we believe that the cheek medial portion, which is thick and has a rich blood supply, supplies vascularization sufficient for good flap vitality even on its distal part.

REFERENCES

1. Burget GC, Menick FJ. The subunit principle in nasal reconstruction. *Plast Reconstr Surg.* 1985;76(2):239–47.
2. Asgari M, Odland P. Nasalis island pedicle flap in nasal ala reconstruction. *Dermatol Surg.* 2005;31(4):448–52.
3. Hairston BR, Nguyen TH. Innovations in the island pedicle flap for cutaneous facial reconstruction. *Dermatol Surg.* 2003 Apr;29(4):378–85.
4. Cvancara JL, Wentsell JM. Shark island pedicle flap for repair of combined nasal ala-perialar defects. *Dermatol Surg.* 2006 May;32(5):726–9.
5. Aoki R, Pennington DG, Hyakusoku H. Flap-in-flap method for enhancing the advancement of a V-Y flap. *J Plast Reconstr Aesthet Surg.* 2006;59(6):653–7.
6. Delbaere-Delbecque M, Delaporte T, Toussoun G, Carton S, Buiet G, Delay E. [Modified Texier mediodorsal transposition island skin flap of the nose. Report of four cases of ala nasi reconstruction] [Article in French]. *Ann Chir Plast Esthet.* 2007 Apr;52(2):130–9.
7. Kaporis HG, Carucci JA. Repair of a defect on the ala. *Dermatol Surg.* 2008 Jul;34(7):931–4.
8. Goldberg LH, Kimyai-Asadi A, Silapunt S. "Jigsaw puzzle" advancement flap for repair of a surgical defect involving the lateral nasal ala. *Dermatol Surg.* 2005 May;31(5):569–71.
9. Türkaslan T, Özsoy Z, Dayıcıođlu D. The helix flap for circular skin defects: case reports. *Eur J Plast Surg.* 2009;32:195–8.

A U T H O R S ' A D D R E S S E S *Antonio Ascari-Raccagni, MD, Department of Dermatology, Dermatological Surgery Unit, G.B. Morgagni – L. Pierantoni General Hospital, via Forlanini 34, 47121 Forli, Italy, E-mail: ascrac@libero.it*

Adina Dondas, MD, Department of Dermatology and Venereology, University of Trieste, Ospedale Maggiore, Via Stuparich 1, 34100 Trieste, Italy, E-mail: adinadondas@hotmail.com

Maria Giovanna Righini, MD, Department of Dermatology, Dermatological Surgery Unit, G.B. Morgagni – L. Pierantoni General Hospital, via Forlanini 34, 47121 Forli, Italy

Giusto Trevisan, MD, Department of Dermatology and Venereology, University of Trieste, Ospedale Maggiore, Via Stuparich 1, 34100 Trieste, Italy, E-mail: trevisan@units.it