

INHERITED DISORDERS OF CATTLE: A SELECTED REVIEW

Arcangelo Gentile ^{1*}, Stefania Testoni ²

Addresses of authors: ¹ Veterinary Clinical Department, University of Bologna, Via Tolara di Sopra 50, 40064, Ozzano dell'Emilia, Bologna; ² Department of Veterinary Clinical Science, University of Padova, Via dell'Università 16, 35020, Legnaro Padova, Italy

* Corresponding author, E-mail: arcangelo.gentile@unibo.it

Abstract: In this paper, the authors summarize the characteristics of the most important inherited disorders they have encountered first hand.

For some of the diseases discussed, the genetic origin has been definitively stated. For others, it is still only a hypothesis which has yet to be confirmed. For all of them, the authors emphasize the importance of identifying and reporting them to diagnostic centres. At the moment in Italy, the authors are trying to develop a program to identify carriers of an undesirable pathological character and to increase relative clinical and pathological knowledge.

Key words: hereditary diseases; central nervous system diseases – genetics; skin diseases – genetics; bone diseases – genetics; cattle

Introduction

Strong inbreeding in the bovine population has increased the risk of the occurrence of genetic diseases. In fact, the wide use of only a few elite sires has enhanced the probability of the coupling of two mutated recessive genes in the genotype of an animal.

One of the most important problems in controlling the genetic diseases is that, once the disorder has finally been discovered, the allelic frequency of the recessives might have already reached high values in the population of the affected breed. In fact, it usually turns out that a genetic disease reveals itself many years after the mutation has occurred, corresponding to the time that the male and female descendants of the original carrier are mated. In the meantime, the allele might have been widely spread throughout the bovine population.

For this reason it is very important that, as early as possible, the phenotype associated with a physiological abnormality, biochemical defect or enzyme deficiency be attributed to a mutated homozygous genotype.

Conditions alerting the investigator to the fact that an abnormality is likely genetic in nature are:

- 1) it is more common in a group of related animals;
- 2) it is observed during all seasons of the year and in different geographic locations;
- 3) it appears more frequently as the level of inbreeding increases.

Whatever the causes, the first step in reducing the incidence of any defect is an accurate clinical and pathological description. The reporting and, possibly, the referring of any suspected case to diagnostic centres is therefore an indispensable step towards improving the possibility of recognition. At the moment in Italy, we are trying to develop a program to identify the carriers of an undesirable pathological character and to increase relative clinical and pathological knowledge so that future cases can be better diagnosed and possibly prevented.

This paper reviews the characteristics of the most important inherited disorders we have encountered first hand. The diseases discussed are classified according to the principal body system affected.

Bibliographic references are limited to part of the papers related to genetic diseases written by the authors together with the most significant and recent articles in the literature.

Inherited central nervous system diseases

Spinal Muscular Atrophy (1, 2, 3, 4, 5, 6, 7)

Spinal Muscular Atrophy (SMA) is a progressive lethal disease reported mainly in advanced backcrosses between American Brown-Swiss and European Brown cattle breeds but also described in Holstein-Friesian calves. It represents the most worrisome concern for Brown breeders' associations.

The condition is characterized by severe muscular atrophy, progressive quadriparesis, and sternal recumbency. The initial signs - symmetric weakness of the rear legs, locomotive difficulties and slight dyspnoea - appear at 3-4 weeks of age. The course of the disease is progressive, and the calves become increasingly weaker and progress to paraparesis and finally tetraparesis (Fig. 1). Animals usually look alert and have a good appetite and a normal suckling reflex. Urination and defecation are in the physiological range. The symptoms are quite similar to white muscle disease (nutritional muscular dystrophy). Death occurs after 2-4 weeks, usually as a consequence of respiratory failure due to atrophy of the respiratory muscles. Occasionally, calves are unable to stand up from the moment of birth. Histo-pathologically, the condition is mainly characterized by muscle fibre atrophy and axonal degeneration of the spinal cord as well as neuronophagia and degeneration and loss of motor neurons in the grey matter of the ventral horns (especially in the brachial and lumbo-sacral regions); furthermore, severe vacuolar degeneration in the midbrain and central motor cortex can be observed. Neuron degeneration seems to originate in unrestrained apoptotic processes initiated during foetal development.

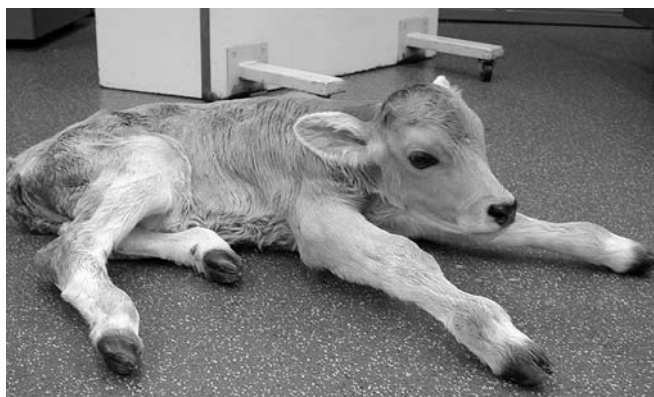

Figure 1: Two-week-old Brown calf affected by Spinal Muscular Atrophy; the calf is weak and not able to maintain the quadrupedal stance. Forelegs are typically maintained extended forward. Note the muscular atrophy of the hindquarters

Bovine-SMA is inherited as an autosomal recessive disorder and its gene has been mapped to the distal part of Chromosome 24. Most of the cases reported can be traced back to an American Brown Swiss bull named "Meadow View Destiny".

At present, marker-assisted tests are available in order to detect carriers of this undesirable gene.

Spinal Dysmyelination (8, 9, 10, 11,12, 13)

Spinal Dysmyelination (SDM) is another congenital and genetic neurological disorder mainly affecting Brown or cross-bred calves upgraded with American Brown Swiss.

Affected animals have congenital recumbency (contrarily to SMA) and, for the most part, lie in a lateral position with a slight to moderate opisthotonos (Fig. 2). Rear limbs are held in extension and, on pressuring the interdigital skin, they react by stretching or kicking. The hind limbs also remain typically extended if calves are able to maintain the sternal position. Although the animals do not try to rise, they are attentive to their surroundings. Main reflexes, appetite, faeces and urine delivery are normal. Affected calves usually die or are euthanized during the first week of life.



Figure 2: Two-day-old Brown calf affected by Spinal Dysmyelination; the calf is lying in a lateral position with opisthotonos

Histopathologically, the disorder is mainly characterized by bilateral symmetrical dysmyelination in the white matter of the spinal cord (gracile funiculus, dorsolateral spinocerebellar tract, sulcomarginal tract), especially at the level of cervical intumescence. Typically, the submeningeal areas have a more pronounced dysmyelination than the deeper parts. Moreover, the number of axons within the affected tracts is reduced. Myelination of the dorsal and ventral nerve roots appears normal.

Similarly to bovine-SMA, SDM is an autosomal recessively-inherited defect. There is evidence that SDM might be traced back to an American Brown Swiss bull named “White Cloud Jasons Elegant” born in 1966.

A marker-assisted test based on five markers has recently been developed in order to detect carriers of this undesirable gene. It is however limited to some genetic lines.

Bovine Progressive Degenerative Myeloencephalopathy (“Weaver” Syndrome) (14, 15, 16)

Bovine Progressive Degenerative Myeloencephalopathy (BPDM) is an inherited disorder of purebred Brown cattle characterized by progressive bilateral hind leg weakness and ataxia, resulting in a weaving aspect of the gait.

Clinical symptoms become apparent at about 6-8 months of age and slowly increase in severity until the animals become unable to rise. Paresis and ataxia are due to proprioceptive deficits involving all four limbs, although the hindlimbs usually appear worse than the forelimbs. If turned quickly or stimulated to run, the hindquarters tend to lose balance and the animals fall laterally (Fig. 3). The same happens if lateral pressure is applied anywhere above the stifle or at the level of the hip. The deficit increases slowly in affected animals and invariably becomes recumbent.



Figure 3: Eighteen-month-old Brown heifer affected by “Weaver syndrome”; stimulated to run, the animal tends to lose balance and falls laterally

Histopathologically, the lesions are characterized by axonal degeneration and vacuolation of the white matter of the spinal cord and degenerative changes or numeric reduction of the Purkinje cells in the cerebellum.

The U.S. sire “Nakota Destiny Dapper” and its sons “Target” and “Matthew” were responsible for

the diffusion of BPDM. The defect has been mapped through linkage analysis to bovine Chromosome 4. A strong selective advantage for milk production has been demonstrated in BPDM-carriers. This was the reason which caused the increase in the frequency of the defective gene. An official DNA marker test allows control of the gene frequency effectively enough, without removing identified BPDM-carriers from service.

Spastic Paresis (17, 18, 19, 20, 21, 22)

With the term Spastic Paresis, we recognize a sporadic neuromuscular disease of cattle clinically characterized by a hyperextension of the rear limbs (“straight hock”) due to a contraction of the muscles which form the Achilles tendon (Fig. 4). Signs of Spastic Paresis usually appear at the age of 3 to 8 months, although these signs may appear when the calves are only a few weeks old as well. More unusual are the cases of later onset, as late as 3 years (Fig. 5).



Figure 4: Seven-month-old male Romagnola animal affected by Spastic Paresis; note the hyperextension of the hock and the “pendulum” movement of the right hind limb



Figure 5: Six-year-old Holstein cow affected by Spastic Paresis; the left hind leg remains completely raised from the ground and extended backwards

In the initial stage, the most remarkable finding is the hyperextension of the hock with an increase of the tibiotarsal angle ("straight hocks"). The condition has a progressive but not predictable course over a period of a few weeks or months; the straightness of the limb become more severe and the calcaneus tends to be drawn to the tibia so that it is possible to observe a wrinkling of the skin corresponding to the distal part of the Achilles tendon. The stifle can however be easily flexed and, in this way, tremulous contractions and further rigid extension of the limb can be provoked. The affected animal has a stiff gait and moves without normal hock flexion.

Later on, the leg is held so that the foot just touches the ground with the toe or it remains completely raised from the ground and extended backwards. In these cases, the animal uses only three legs to walk; the severely affected leg is held permanently in extension and contractural fits cause a typical "pendulum" movement, with most motion occurring at the coxofemoral joint. This sign is most evident immediately after standing up when it is also possible to observe an arching of the back and elevation of the tailhead.

In the majority of cases, only one leg is affected: if both limbs are involved, the animal bears weight alternatively on each leg.

It is worth noting that, in recumbency, the animal is completely normal. Moreover, the tone of the affected muscles is normal as has been confirmed by electromyographic studies.

Spastic Paresis is caused by a spastic contraction of the antigravitational, foot extensor muscle group, especially the gastrocnemius and the superficial digital flexor. Other muscles such as biceps femoris, semitendinosus, semimembranosus, quadriceps femoris and adductor muscles can also be involved. The contraction of the quadriceps femoris characterizes the recently described atypical form of Spastic Paresis of the femoral quadriceps, first observed in Belgian White Blue calves but then also observed in Romagnola animals. In these cases, the affected hind leg shows a swaying movement in anterior direction.

The muscular spasticity should be attributed to hyperactivity of the myotatic reflex ("stretch reflex"). The dysfunction lies primarily in the gamma-pathway which means in an anomalous action of the gamma-motor neurons. On the basis of this pathogenetical hypothesis, it is nevertheless still unknown whether the overstimulation of the gamma-pathway is due to intrinsic hyperactivity of the gamma-motor neuron or to a lack of inhibitory mechanisms; in the latter case, a defect

of the regulatory descendant pathway arising from the red nucleus (rubrospinal pathway) or from the lateral vestibular nucleus (vestibulospinal pathway) could play an important role.

Although the hereditary contribution appears unquestionable, up to now, it has not been possible to definitively determine the mode of inheritance (dominant or recessive) or the entity of penetrance of the single or multiple genes responsible. It is supposed by most authors that the mode of inheritance could be recessive with low or incomplete penetrance. It should therefore be assumed that environmental (plant toxicity?), nutritional (trace element deficiency = Mn, Ca, P, Cu, Zn, Co, I, Se?; vitamin deficiency = vit. A?), metabolic (Cu/Zn imbalance?) or individual factors can play an important role in the appearance and expression of the disease.

Many types of therapy have been suggested, including tenotomy of the gastrocnemius tendon and neurectomy of the branches of the tibial nerve supplying the gastrocnemius muscle. Our experience is limited to the total neurectomy of the tibial nerve which has shown interesting results but not a complete recovery.

Spastic Syndrome (23, 24, 25)

Spastic Syndrome ("crampiness", "Krämpfigkeit") is a chronic condition occurring in adult cattle. It is a particular problem in the mature bulls maintained in artificial insemination centres but can also affect cows in a recurrent or in a progressive form. Animals of several breeds can be affected. The disease is characterized by intermittent bilateral spasms of the skeletal muscles of the pelvic girdle, including the muscles of the rump. Each spasm is accompanied by kyphosis which is often terminated by a tremor of the hindquarters (Fig. 6). During the attack, one hind



Figure 6: Three and a half-year-old Holstein cow affected by Spastic Syndrome; note the kyphosis

leg (usually always the same) may lift laterally in partial flexion. The intensity and duration of the spasms progressively increase over time.

There is a paucity of literature on Spastic Syndrome and the few reports which included morphological examinations failed to reach significant results and concluded that the syndrome is a type of idiopathic or true muscle cramps.

Regarding the aetiology, there is evidence which suggests a recessive mode of inheritance but with incomplete penetrance.

There is no specific treatment for the condition; we personally recommend the use of analgesic drugs.

Inherited congenital skeletal malformations

Craniofacial defects

Some of the literature lists closure defects of the lip (cleft lip) and/or the palate (cleft palate – Fig. 7) as genetic defects, likely polygenic, but more data are needed to confirm this hypothesis. In any case, it should be mentioned that these facial defects (especially cleft palate) constitute a relatively frequent congenital anomaly which may be part of a complex congenital malformations in varying degrees.

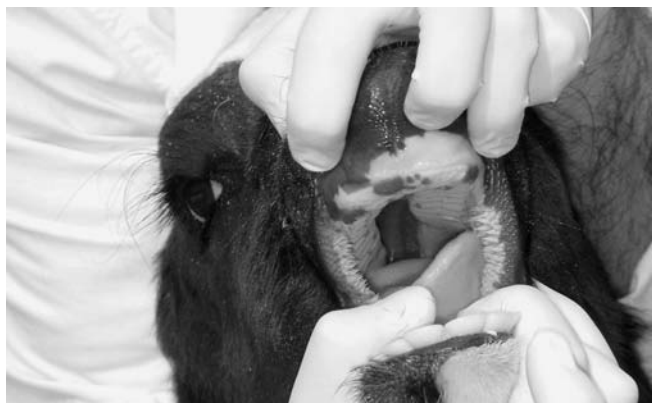

Figure 7: 40-day-old calf affected by cleft palate

Another relatively common, more or less pronounced, congenital anomaly is short lower jaw (brachygnathia). Also for this defect, an inherited origin is suggested, especially for Simmentals and, more recently, Brown breeds.

Chondrodysplasia and “ Congenital Paunch Calf Syndrome” (26, 27, 28, 29, 30)

Chondrodysplasia is a disturbance of endochondral ossification leading to disordered bone development. Although several types of chon-

drodysplasia are known, the most common form in Italy is the so-called “Bulldog calf” of the Romagnola breed (Fig. 8). It is characterized by a flat head with a short nose and sloping forehead and by short and stumpy limbs. Severe affected calves live only a few months.



Figure 8: Six-month-old Romagnola animal affected by achondroplasia; note the facial deformity

The bone growth disturbances involve a defect of cartilage growth which hinders the normal lengthening of the long bones. The chondrocytes do not undergo physiological differentiation so they cannot fulfil normal endochondral ossification in osteogenesis.

More recently, we have reported another form of achondroplasia in Romagnola calves which we have called “Congenital Paunch Calf Syndrome” because, besides facial defects, another main clinical feature is abdominal distension and also because this is the name used by farmers when they report the affected animals.

Facial deformities are characterized by a shortened and flattened face and, in some cases, by an enlarged head. Contrarily to other achondroplastic defects, in this case, limbs only rarely show a disproportionate shortness. Cleft palate is a frequent accompanying finding.

The most characteristic symptom of these calves, however, is an enlarged and floating abdomen, denoting considerable abdominal effusion (Fig. 9). Moreover at necropsy, the animals usually show marked subcutaneous oedema, especially in the ventral part of the abdominal wall. Different quantities of ascitic fluid (in some cases up to 10 litres) are present in the abdominal cavity. The liquid ranges from yellow to red, with different grades of turbidity.

Another characterizing aspect is moderate to severe diffuse hepatic fibrosis, associated with the presence of hepatic cysts, containing serous or reddish fluid. Microscopic examination of the liver reveals an extensive distortion of lobular

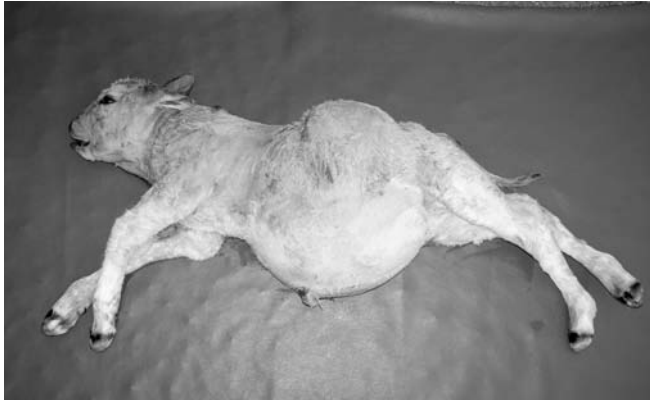

Figure 9: Stillborn Romagnola calf affected by the so-called “Congenital Paunch Calf Syndrome”; note the enlarged and floating abdomen (denoting a considerable abdominal effusion) and the facial deformities (shortened and flattened face)

architecture by widespread fibrosis in periportal areas and around the centrilobular veins. In some lobules, the fibrosis extends to the perisinusoidal spaces.

Cardiac malformations, such as atrial and interventricular septal defects, and patent ductus arteriosus can be observed.

At the moment, we have not found any familial line which can be considered responsible for the inheritance of the defect; nevertheless, a genetic cause is strongly suspected.

Complex Vertebral Malformation (31, 32, 33, 34, 35, 36, 37, 38, 39, 40, 41)

At present “Complex Vertebral Malformation” (CVM) represents the most worrisome hereditary concern for Holstein breeders. This defect is clinically characterized by the following phenomenological triad: (a) reduced body size; (b) symmetrical arthrogryposis; (c) malformations in the cervical and/or thoracic vertebral column (especially shortened neck and scoliosis). Homozygous animals usually die during pregnancy, are premature or stillborn, or die shortly after birth. Besides the aforementioned clinical triad, live calves might be alert and show a suckling reflex and appetite. They are unable to stand up (Fig. 10), lying down in a flat position with extended limbs (frog-like decubitus).

Clinical diagnosis is confirmed by radiographic examination of the vertebral column which shows multiple vertebral anomalies including hemivertebrae, fused and misshapen vertebrae and ribs, and scoliosis affecting mainly the caudal cervical and the thoracic regions (Fig. 11).

A complex malformation of the heart, charac-



Figure 10: Two-day-old Holstein calf affected by Complex Vertebral Malformation; despite repeated attempts to stand up, the calf is unable to do so. If supported by assistants, its feet rest on the dorsolateral face of the pastern on the ground; the head hangs down between the forelimbs

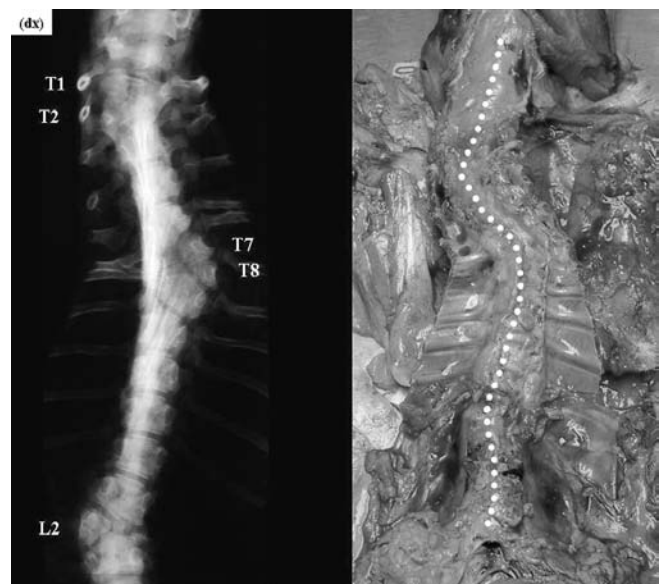


Figure 11: X-ray and anatomical dissection of the same calf as in Fig. 10 = on the left: note the presence of hemivertebrae in the thoracic (T1, T2, T7, T8) and lumbar (L2) regions; on the right: note the evident S-shaped deviation of the vertebral column at the level of the thoracic and lumbar tracts (scoliosis)

terized by atrial and/or interventricular septal defects, and patent ductus arteriosus might accompany the skeletal malformations.

CVM stems from a simple autosomal recessive allele which can be detected by a DNA-PCR based test.

Interesting recent analysis has demonstrated that a different expression of the foetal CVM phenotype might directly influence several fertility traits, such as non-return rates for cows, calving

frequency after a first insemination and the interval between insemination and the next calving; according to recent research, 16% of CVM-affected embryos die within the first 56 days of pregnancy, and up to 45% and 77% of CVM-affected foetuses die before the 150th and the 260th gestation-day, respectively. The frequency of calving resulting in a live-born calf 260-300 days after first insemination has been calculated to be reduced by 93% if the foetuses had the CVM phenotype, therefore deducing that only 7% of CVM-affected calves survive the gestation period.

Unless the malformation is severe, the vertebral defect might be overlooked during routine examination of the aborted foetuses or stillborn calves, and the same may be said of neonates apparently affected by only arthrogryposis and incapable of assuming the quadrupedal stance.

The embryonic/foetal mortality rate might also be biased by the observed rate of heat, the culling of pregnant cows and embryonic/foetal mortality without any connection to CVM. All these situations negatively influence the perception of the presence of the defect in the herd and, therefore, do not allow the exact estimation of the economic loss related to foetal and near-term deaths associated with the defect.

Retrospective evaluation of the familial occurrence has demonstrated that the former elite U.S. Holstein Carlin-M-Ivanhoe Bell should be considered one of the biggest spreaders of the disease. It very probably received the defective allele from its father, Penstate Ivanhoe Star. It should be mentioned that the same family of sires has been recognized as the carrier of another recessive gene defect, Bovine Leukocyte Adhesion Deficiency (BLAD). However, the two gene defects are not linked and are inherited independently.

Arachnomelia (42, 43, 44, 45, 46, 47, 48, 49)

Arachnomelia ("spider-legs") is a congenital abnormality of the skeletal system giving the animal a spidery look, and reported both in Simmenthal and Brown calves.

The most important pathologic findings are: facial deformities (i.e. brachygnathia inferior and concave rounding of the dorsal profile of the maxilla), bone dolichostenomelia, angular deformities in the distal part of the hind legs (Fig. 12), muscular atrophy and cardiac malformations. The bones of the legs appear to be more fragile than normal and spontaneous fracture during calving may injure the dam.

Although we failed to find precise information in the literature, the pathogenesis of the disease

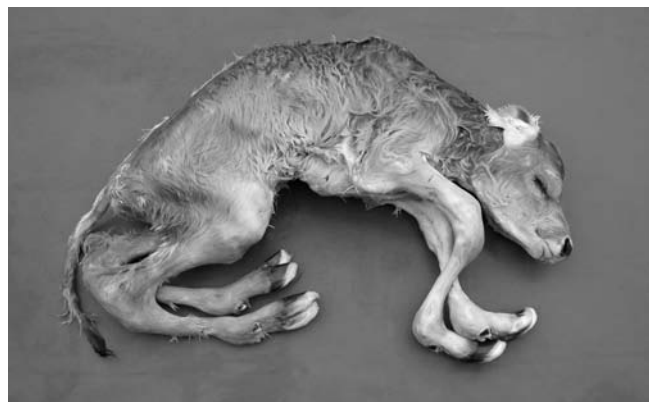

Figure 12: Stillborn Brown calf affected by Arachnomelia; note the abnormal length and thinning of all legs (dolichostenomelia). Forelegs show severe angular deformities in their distal part

seems to overlap that of Marfan Syndrome in human medicine (Arachnodactylia); in this context, a defect in the metabolism of the connective tissue is involved. However, the clinical findings recorded in calves affected by Arachnomelia usually differ from the typical picture of human "Marfan patients" (dolichostenomelia with high fragility of the long bones, defects of the heart and main arteries and ectopia lins) and, for this reason, we think that the clinical identification between bovine Arachnomelia and human Marfan Syndrome is inappropriate. Moreover, contrary to the almost undisturbed vitality of human patients, bovine Arachnomelia has a rapidly lethal course.

It should be kept in mind that true Bovine Marfan Syndrome, more closely resembling human Marfan Syndrome, has also been described in cattle.

As far as the aetiology is concerned, although it has not been possible to find candidate genes until now, the condition is attributable to a simple autosomal recessive inheritability. The U.S. sire "Novic Lilasons Beautician" was responsible for the diffusion of the defect. At the moment, there is neither a chromosomal nor a biochemical test to detect the carriers of this defect.

Short Spine Lethal (50, 51, 52, 53, 54, 55)

Short Spine Lethal is a rare skeletal malformation externally characterized by a marked and disproportionate shortening of the vertebral column associated with a normally developed head and legs (Fig. 13). Shortening of the neck might be very pronounced giving the impression that the head is fixed to the chest. Misalignment of the teeth and mandibular hypoplasia, resulting in

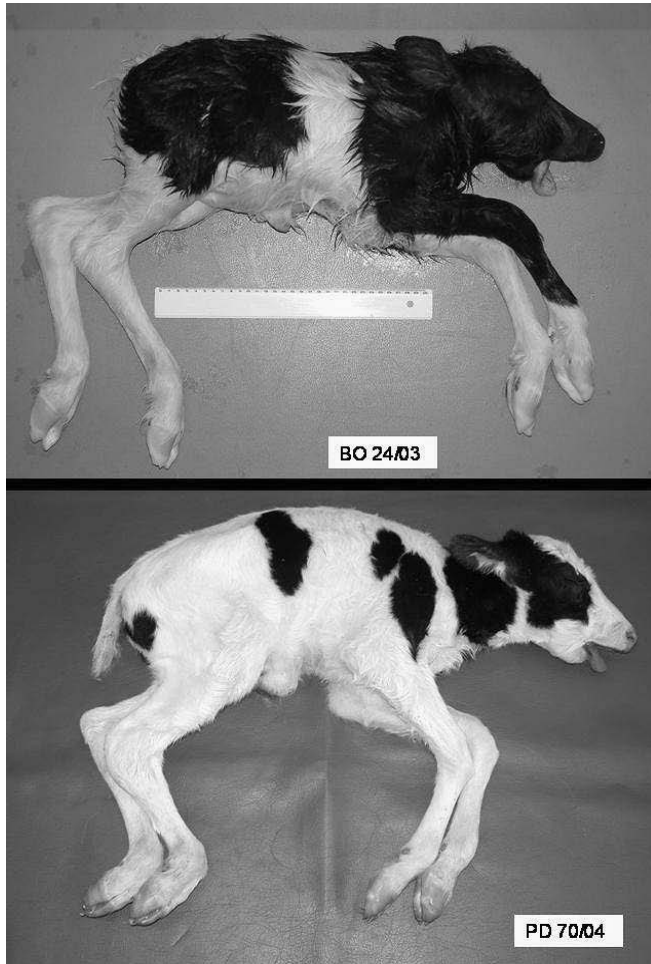


Figure 13: Stillborn Holstein calves affected by Short Spine Lethal. In both animals the trunk was disproportionately short for the body size and legs. Note the mandibular hypoplasia and the protrusion of the tongue. Both calves were traced back to the same sire, one of the breeding lines most recently used in Holsteins in Italy

protrusion of the tongue from the oral cavity, might be observed. Despite being full term, calves might present a strong reduction in body weight.

External conformation is due to several spinal malformations, including fusion and/or variations in the number of vertebrae, abnormal vertebral body size and shape, and misalignment of vertebral segments, mainly involving the cervical and thoraco-lumbar tract.

Visceral malformations involving the urogenital, gastrointestinal, and cardiovascular systems may also be found.

In all cases published, the occurrence of common ancestors has suggested a genetic aetiology. Unfortunately, due to the limited number of cases, evaluation of the mode of inheritance is difficult.

Perosomus acaudatus/elumbis (56, 57, 58, 59)

Partial agenesis of the vertebral column constitutes a relatively common occurrence and can be limited to the coccygeal tract (*Perosomus acaudatus*, *Brachyury*) or also involve the sacral and/or lumbar tract (*Perosomus elumbis*). Although evidence of inheritance has been reported in the past, more information is needed to confirm the genetic hypothesis.

The simple lack of the coccygeal vertebrae (*Perosomus acaudatus*) is compatible with life and animals can also carry out pregnancy without any problem. In more extended failures of vertebral development (*Perosomus elumbis*), the back of the lumbosacral region lacks a rigid skeletal support, and the hindquarters, strongly underdeveloped and possibly paralyzed, are linked to the rest of the body only by soft tissue. In these cases, calves are shorter than normal and cannot maintain a quadrupedal stance or use their hind legs at all (Figs. 14 and 15).

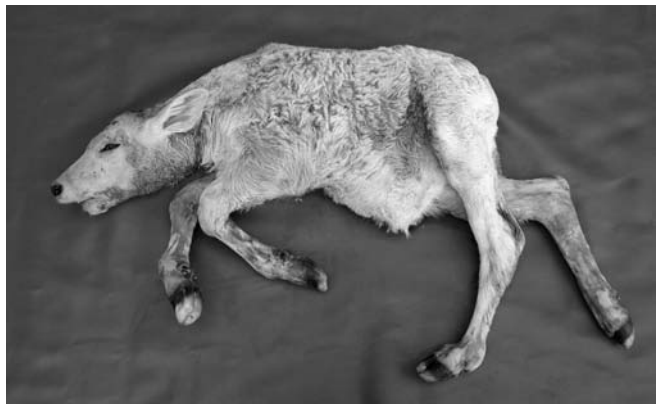

Figure 14: Brown calf affected by *Perosomus elumbis*; note the brachygnathia of the lower jaw and the shortened torso




Figure 15: Anatomical dissection of the same calf as in Fig. 14; the lumbar, sacral and coccygeal vertebrae were entirely lacking

The skeletal anomaly is often accompanied by other endocavitary malformations (e.g. colon/rectum/anal atresia with a blind-ending-sac filled with mucoid faeces and protruding at the level of the sacral region, renal agenesis, cardiac anomalies) which make the situation incompatible with life. The spinal cord ends in a blind vertebral canal.

Malformation or improper migration of the neural tube during the tail-bud stage, accompanied by partial agenesis of the caudal spinal cord, seems to be the cause of this abnormality.

Syndactyly (Mule Foot) (60, 61, 62, 63)

Fusion or non-division of the digits constitutes a well known hereditary defect in Holstein cattle but has been described in a number of other cattle breeds. The lesion is primarily osteological in nature and consist mainly in synostotic phalanges; more proximal limb structures can be affected as well, such as metacarpal and metatarsal III and IV bones. The syndactylous hoof has the aspect of a truncated cone with the base at the coronary seam. In Holstein cattle, Mule Foot has been confirmed as a simple autosomal recessive inherited defect; the gene responsible is located on the telomeric end of chromosome 15. An incomplete penetrance is demonstrated by the variable expressivity of the disease, mainly due to an interesting right-left and front-rear gradient, meaning that the right front foot is affected more often, followed by the left front (Fig. 16), right rear and left rear foot.




Figure 16: Holstein calf affected by Syndactyly; only the front legs show syndactylous hoof

Inherited skin defect

Ichthyosis (64, 65, 66, 67, 68)

Ichthyosis is a rare skin disease reported in different breeds and characterized by diffuse cutaneous hyperkeratosis giving the skin an appearance similar to that of fish. Currently, two congenital forms of ichthyosis are described in cattle: ichthyosis fetalis and ichthyosis congenita.

Ichthyosis fetalis (bovine harlequin foetus) is the most severe form of bovine Ichthyosis and is incompatible with life; the affected calves are still-born or die within a few days after birth. The skin is covered with large horny plates separated by deep fissures, resembling a 'leather cuirass'; hair is usually completely absent. The thick, inelastic skin causes eversion at mucocutaneous junctions, eclabium and ectropion. This form appears to be similar to human harlequin ichthyosis (HI) where there are severe plate-like cutaneous formations which are diffused over the body resulting in early neonatal death.

Ichthyosis congenita is the milder form of the disease; affected calves tend to live longer. General physical health is good. The lesions are characterized by hyperkeratosis, present at birth or developing over several weeks; hairlessness is not an initial feature, but alopecia may develop. Thick and large cutaneous scales are typical and more severe over the limbs, abdomen and muzzle



Figure 17: Three-month-old female Chianina calf affected by Ichthyosis congenita. Note the alopecic areas on the muzzle, eyelids and ears. The areas were covered by thick, dark-grey, dry, scale-like hyperkeratotic material. The diameter of the scales was 2-3 mm

(Fig. 17). Cataract, microtia and thyroid abnormalities have been reported in calves affected with this disorder. Bovine ichthyosis congenita resembles lamellar ichthyosis in humans (LI).

In both forms of ichthyosis, the constant histological feature, despite the variable anatomic sites and severity, is the marked orthokeratotic lamellar hyperkeratosis of the epidermis and follicular epidermis.

Presumably, as in the human forms of ichthyosis, the scales are the product of a defective desquamation associated with increased cohesion of keratinocytes and therefore represent a large number of cohesive corneocytes retained and shed simultaneously.

Both forms of ichthyosis in cattle are thought to be inherited through a simple autosomal recessive gene. By comparative analysis with the human forms of ichthyosis, a research project is underway at the University of Milan (Italy) where they are working on the candidate gene TGM1 (keratinocyte transglutaminase 1), responsible in man for the activity of TGase1, an enzyme in the cornified cell envelope assembly line.

Since neither chromosomal nor biochemical tests are yet available to detect carriers of this defect, reports of affected animals and the accurate identification of clinical cases are the only opportunity for carrier animals to be detected in retrospect.

References

- Dirksen G, Doll K, Hafner A, Hermanns W, Dahme E. Spinale Muskelatrophie (SMA) bei Kälbern aus Brown Swiss x Braunvieh-Kreuzungen. *Dtsch Tierärztl Wochenschr* 1992; 99: 168-75.
- Troyer D, Cash WC, Vestweber J, Hiraga T, Leipold HW. Review of spinal muscular atrophy (SMA) in Brown Swiss cattle. *J Vet Diagn Invest* 1993; 5: 303-6.
- Pumarola M, Anor S, Majo N, Borrás D, Ferrer I. Spinal muscular atrophy in Holstein-Friesian calves. *Acta Neuropathol (Berl.)* 1997; 93: 178-83.
- Berchtold J. SMA-Genetest kommt auf den Markt. *Rinderzucht Braunvieh* 2001; 7(2): 18.
- Testoni S, Gentile A, Castagnaro M, Lugli M. Su di un caso di atrofia muscolo spinale in un vitello di razza Bruna. *Obiettivi Doc Vet* 2002; 23(3): 25-9.
- Medugorac I, Kempter J, Russ I, et al. Mapping of the bovine spinal muscular atrophy locus to chromosome 24. *Mamm. Genome* 2003; 14: 383-91.
- Krebs S, Medugorac I, Russ I, et al. Fine-mapping and candidate gene analysis of bovine spinal muscular atrophy. *Mamm. Genome* 2006; 17: 67-76.
- Hafner A, Dahme E, Obermaier G, Schmidt P, Dirksen G. Spinal dysmyelination in new-born Brown Swiss x Braunvieh calves. *J Vet Med B* 1993; 40: 413-22.
- Agerholm JS, Hafner A, Olsen S, Dahme E. Spinal dysmyelination in cross-bred Brown Swiss calves. *J Vet Med A* 1994; 41: 180-8.
- Agerholm JS, Andersen O. Inheritance of spinal dysmyelination in calves. *J Vet Med A* 1995; 42: 9-12.
- Stocker H, Pusterla JB, Lutz H, Ossent P. Eine neue Erbkrankheit beim Braunvieh in der Schweiz: Spinale Dysmyelinisierung (SDM) bei festliegenden Kälbern. *Schweiz Arch Tierheilkd* 1996; 138: 295-300.
- Nissen PH, Shukri NM, Agerholm JS, Fredholm M, Bendixen C. Genetic mapping of spinal dysmyelination in cross-bred American Brown Swiss cattle to bovine chromosome 11. *Mamm Genome* 2001; 12: 180-2.
- Nissen PH, Thomsen B, Offenberger H, Thomsen PD, Bendixen C. Cloning and characterization of the bovine EGR4 gene and evaluation as candidate gene for bovine spinal dysmyelination. *Anim Genet* 2003; 34: 124-31.
- Hoeschele I, Meinert TR. Association of genetic defects with yield and type traits: the Weaver locus effect on Yield. *J Dairy Sci* 1990; 73: 2503-15.
- Doll K, Trela T, Matzke P, Dahme E, Hafner E, Dirksen G. Bovine progressive degenerative Myeloencephalopathie (Weaver-syndrom) bei Brown Swiss x Braunvieh-Rindern: Klinik, Verlauf, Blut- und Liquorbefunde. *Tierärztl Umsch* 1993; 48: 467-76.
- Abdallah MB, DeNise SK, Oberg EA. Radiation hybrid mapping of markers and genes near the bovine progressive degenerative myeloencephalopathy (PDME) locus on bovine chromosome 4. In: *Proceedings of the 10th plant, animal and microbe genomes conference*. San Diego, CA, 2002: poster 573.
- Barazzoni AM, Bompadre G, Grandis A, et al. Histochemical aspects of gastrocnemius muscle fibers in healthy and spastic paresis affected bovine. *It J Anat Embryol* 2003; 108(3): 167.
- Gentile A. Bovine spastic paresis: an old but still not well known disease. In: *Proceedings of the 2nd Middle-European Congress for Buiatrics*. Vysoké Tatry, Slovakia, 2000: 20-2.
- Gentile A. Bovine spastic paresis: an old but still not well known disease. *Folia Vet* 2000; 44(3): 162-4.
- Gentile A. Vorkommenshäufigkeit der Spastischen Parese bei Rindern der Romagnola-Rasse. *Klauentierpraxis* 2002; 10(3): 79-82.
- Gentile A. Bovine spastic paresis in the Italian Romagnola Race. In: *Proceedings of the XIII. Magyar Buiatrikus Kongresszus*. Hajdúszoboszló, Hungary, 2002: 89-96.
- Touati K, Muller Ph, Gangl M, Grulke S, Peters F, Serteyn D. La parésie spastique du quadriceps fémoral: une nouvelle entité clinique chez le veau de race Blanc Bleu Belge. *Ann Méd Vét* 2003; 147 : 261-5.
- Sponenberg DP, Vanvleck LD, McEntee K. The genetics of the spastic syndrome in dairy bulls. *Vet Med* 1985; 80(8): 92-4.

24. Bergamini PF, Chiocchetti R, Moretti M, Gentile A, Boari A. Alterazioni isto-morfologiche del midollo spinale in tori con "sindrome spastica". *Atti Soc It Buiatria* 1995; 27: 519-21.
25. Tenszen A. Spastic syndrome in a Canadian Hereford bull. *Can Vet J* 1998; 39: 716-7.
26. Harper P, Latter MR, Cook RW, Gill PA. Chondrodysplasia in Australian Dexter cattle. *Aust Vet J* 1998; 76: 199-202.
27. Takeda H, Takami M, Oguni T, et al. Positional cloning of the gene LIMBIN responsible for bovine chondrodysplastic dwarfism. *Proc Natl Acad Sci USA* 2002; 99: 10549-54.
28. Yoshikawa H, Fukuda T, Oyamada T, Yoshikawa T. Congenital hepatic fibrosis in a newborn calf. *Vet Pathol* 2002; 39: 143-5.
29. Gentile A, Militerno G, Marcato PS. Congenital paunch calf syndrome in Romagnola cattle. In: *Proceedings of the 23rd World Buiatrics Congress*. Quebec, Canada, 2004; 104.
30. Starke A, Drögenmüller C, Schmidbauer S, Wohlsein P. Kongenitaler disproportionaler Zwergwuchs bei Deutschen Holsteins. In: *Proceedings of the 1st Swiss Buiatrics Congress "Buiatrisissima"*. Bern, Switzerland, 2005: 38.
31. Agerholm JS, Bendixen C, Andersen O, Arnbjerg J. Complex vertebral malformation in Holstein calves. *J Vet Diagn Invest* 2001; 13: 283-9.
32. Duncan RB, Carrig CB, Agerholm JS, Bendixen C. Complex vertebral malformation in a Holstein calf: report of a case in the USA. *J Vet Diagn Invest* 2001; 13: 333-6.
33. Konersmann Y, Wemheuer W, Brenig B. Herkunft, Verbreitung und Bedeutung des CVM-Gendefekts in der Holstein-Friesian-Population. *Züchtungskunde* 2003; 75: 9-15.
34. Gentile A, Testoni S, Olzi E, Diana A. Su di un caso di malformazione vertebrale complessa (Complex vertebral malformation - CVM) nel vitello. *Atti Soc It Buiatria* 2004; 36: 307-15.
35. Gentile A, Testoni S, Diana A. Complex vertebral malformation (CVM) in a calf. In: *Proceedings of the 5th Middle-European Buiatrics Congress*. Hajduszoboszlo, Hungary, 2004: 460-5.
36. Gentile A, Diana A, Testoni S, Cipone M. Complex vertebral malformation (CVM) in a Holstein calf: clinical and radiological (X-Ray and CT-Scan) aspects. In: *Proceedings of the 23rd World Buiatrics Congress*. Quebec, Canada, 2004: 103.
37. Nielsen US, Aamand GP, Andersen O, Bendixen C, Nielsen VH, Agerholm JS. Effects of complex vertebral malformation on fertility traits in Holstein cattle. *Livestock Prod Sci* 2003; 79: 233-8.
38. Agerholm JS, Andersen O, Almskou MB, et al. Evaluation of inheritance of the complex vertebral malformation syndrome by breeding studies. *Acta Vet Scand* 2004; 45: 133-7.
39. Agerholm JS, Bendixen C, Arnbjerg J, Andersen O. Morphological variation of complex vertebral malformation in Holstein calves. *J Vet Diagn Invest* 2004; 16: 548-53.
40. Berglund B, Persson A, Stalhammar H. Effects of complex vertebral malformation on fertility in Swedish Holstein cattle. *Acta Vet Scand* 2004; 45: 161-5.
41. Kanae Y, Endoh D, Nagahata H, Hayashi M. A method for detecting complex vertebral malformation in Holstein calves using polymerase chain reaction-primer introduced restriction analysis. *J Vet Diagn Invest* 2005; 17: 258-62.
42. Rieck GW, Shade W. Die Arachnomelie (Spinnegliedrigkeit), ein neues erbliches letales Mißbildungssyndrom des Rindes. *Dtsch Tierärztl Wochenschr* 1975; 82: 342-7.
43. Brem G, Wanke R, Hondele J, Dahme E. Zum Auftreten des Arachnomelie-Syndroms in der Brown-Swiss x Braunvieh Population Bayerns. *Berl Münch Tierärztl Wochenschr* 1984; 97: 393-7.
44. König H, Gaillard C, Chavaz J, Hunziker F, Tontis A. Prüfung von Schweizer Braunvieh-bullen auf das vererbte Syndrom der Arachnomelie und Arthrogrypose (SAA) durch Untersuchung der Nachkommen im Fetalstadium. *Tierärztl Umsch* 1987; 42: 692-7.
45. Potter KA, Besser TE. Cardiovascular lesions in bovine Marfan syndrome. *Vet Pathol* 1994; 31: 501-9.
46. Testoni S, Cavicchioli L, Castagnaro M, Gentile A. Arachnomelia in italian Brown calves. In: *Proceedings of the 4th Central European Buiatrics Congress*. Opatija, Croatia, 2003: 388-90.
47. Testoni S, Cavicchioli L, Ferro S, Gentile A. Tre casi di arachnomelia in vitelli di razza Bruna. *Atti Soc It Buiatria* 2003; 35: 113-21.
48. Testoni S, Gentile A, Castagnaro M. Arachnomelia in italian Brown calves. In: *Proceedings of the 23rd World Buiatrics Congress*. Quebec, Canada, 2004: 107.
49. Testoni S, Gentile A. Arachnomelia in four italian Brown calves. *Vet Rec* 2004; 155: 372.
50. Mohr OL, Wriedt CHR. Short spine, a new recessive lethal in cattle; with a comparison of the skeletal deformities in short-spine and in amputated calves. *J Genet* 1930; 22: 279-97.
51. Leipold HW, Dennis SM. Short spine lethal in an Aberdeen-angus calf. *Cornell Vet* 1972; 63: 506-9.
52. Greene HJ, Leipold HW, Huston K. Bovine congenital skeletal defects. *Zbl Vet Med A* 1974; 21: 789-96.
53. Jones DM. A severe spinal deformity in a cape buffalo calf (*Syncerus caffer*) similar to "short spine lethal" of angus cattle (*Bos taurus*). *Br Vet J* 1974; 139: 24-5.
54. Testoni S, Diana A., Olzi E, Gentile A. Short spine lethal in due vitelli di razza Frisona. *Atti Soc It*

Buiatria 2005; 37:273-81.

55. Testoni S, Diana A, Olzi E, Gentile A. Short spine lethal in two Holstein calves. In: Malinowski E, Bednarek D, eds. Achievements and prospects of ruminants medicine. Pulawy, Poland : PIWet - National Veterinary Research Institute, 2005: 143-6.

56. Habermehl KH. Über verschiedene Formen des Perosomus elumbis (Gurlt). Monatsh Tierheilkd 1954; 6: 75-87.

57. Jones CJ. Perosomus elumbis (vertebral agenesis and arthrogryposis) in a stillborn Holstein calf. Vet Pathol 1999; 36: 64-70.

58. Castro MB, Szabo MPJ, Hokamura HK, Romano MA. Perosomus elumbis in a Holstein calf in Brazil. Vet Rec 2003; 152: 753.

59. Bähr C, Distl O. Brachyurie bei Deutschen Holstein-Rindern" Dtsch Tierärztl Wochenschr 2004; 111: 150-3.

60. Johnson JL, Leipold HW, Snider GW, Baker RD. Progeny testing for bovine syndactyly. J Am Vet Med Assoc 1980; 176: 549-50.

61. Charlie C, Farnir F, Berzi P, et al. Identity-by-descent mapping of recessive traits in livestock: application to map the bovine syndactyly locus to chromo-

some 15. Genome Res 1996; 6: 580-9.

62. Bähr C, Drögenmüller C, Distl O. Fallbericht: Syndactylie bei Deutschen Holstein-Kälbern. Dtsch Tierärztl Wochenschr 2004; 111: 473-6.

63. Drögenmüller C, Distl O. Genetic analysis of syndactyly in German Holstein cattle. Vet J 2006; 171: 120-5.

64. Lüps P. Die Fischschuppenkrankheit (Ichthyosis universalis congenital), eine in Bayern beobachtete Erbkrankheit des Rindes. Berl Münch Tierärztl Wochenschr 1963; 76: 204-6.

65. Baker JR, Ward WR. Ichthyosis in domestic animals: a review of the literature and a case report. Br Vet J 1985; 141: 1-8.

66. Molteni L, Dardano S, Parma P, De Giovanni A, De Lorenzi L, Longeri M. Candidate gene approach in molecular analysis of ichthyosis in Chianina cattle. In: Proceedings of the 48th Italian Society Agricultural Genetics. Lecce, Italy, 2004: abstract 4.08.

67. Raoofi A, Mardjanmehr SH, Nekoei Sh. Ichthyosis congenita in a calf in Iran. Vet Rec 2001; 149: 563.

68. Testoni S, Panozzo G, Zappulli V, Gentile A. Su di un caso di Ittiosi congenita in un vitello di razza Chianina. Atti Soc It Buiatria 2004; 36: 317-24.

DEDNE BOLEZNI PRI GOVEDU: IZBRAN PREGLED

A. Gentile, S. Testoni

Povzetek: V goveji populaciji je zaradi visoke stopnje medsebojnega parjenja nevarnost pojavljanja genetskih obolenj. Razširjena uporaba semen samo elitnih bikov poveča verjetnost pojavitve dveh mutiranih recesivnih genov v genotipu enega potomca.

Znaki, ki nakazujejo, da je bolezenska sprememba verjetno genetskega izvora, so:

1. bolezensko stanje je pogostejše v skupini sorodnih živali
2. bolezensko stanje opazimo v vseh letnih časih in na različnih geografskih področjih
3. stanje postaja pogostejše, ko se pogostnost medsebojnega parjenja povečuje

V zadnjem času smo imeli izkušnje predvsem z genetskimi obolenji.

Dedne bolezni centralnega živčnega sistema: *Mišična atrofija*, ki izvira iz hrbtenjače, je najbolj zaskrbljujoča dedna hiba sivorjavih telet, ki jo označuje huda mišična atrofija, progresivna pareza vseh okončin in ležanje na prsnici od tretjega ali četrtega tedna dalje. *Izguba mielina hrbtenjače* je prirojena nevrološka motnja, ki prizadene predvsem teleta sivorjave pasme. Ta po rojstvu ne morejo vstati in imajo tipično iztegnjene zadnje okončine. Prizadetost povzroča izguba mielina v belini hrbtenjače. *Goveja progresivna degenerativna mieloencefalopatija* (sindrom "tkalca") je dedna motnja čistokrvne sivorjave pasme. Zanj je značilna progresivna šibkost zadnjih okončin in nekoordinirano gibanje, ki spominja na gibanje rok pri uporabi tkalskega čolnika (weaver syndrome - sindrom tkalca). Klinični znaki postanejo očitni med 6. in 8. mesecem starosti. *Spastična pareza* je najbolj problematična dedna hiba pasme romagnola. Napaka se odraža v hiperekstenziji skočnega sklepa in nenormalnem gibanju zadnje okončine. V najhujših primerih je prizadeta okončina stalno iztegnjena in nenehni krči povzročajo tipično gibanje v obliki nihala. Znaki spastične pareze se pojavijo med 3. in 8. mesecem starosti, ko spastični krči prizadenejo iztegovalke skočnega sklepa. *Spastični sindrom* je resen problem pri bikih v osemenvalnih centrih, ki lahko prizadene tudi krave v progresivni ali ponavljajoči se obliki. Ponavljajoči se krči obojestransko prizadenejo notranje ledvene in križno-ledvene mišice. Pojavi se kifoza in drhtenje zadnjih okončin. Sčasoma se intenzivnost in trajanje krčev povečujeta.

Podedovane prirojene napake skeleta: *Hondrodisplazija* je znana tudi pod imenom "bulldog" telet in je bila včasih pogosta pri pasmi romagnola. Lobanja je sploščena, smrček kratek, čelo pa se le počasi vzdiguje. Prizadete živali imajo tudi krajše okončine. Pri t. i. "*prirojenem sindromu telečjega vampa*" pasme romagnola poleg skrajšane in sploščene lobanje

opazimo še volčje žrelo in napihnjenost trebuha zaradi znatno povečane količine tekočine v trebušni votlini. *Kompleksna nepravilnost vretenc* (CVM - complex vertebral malformations) predstavlja najresnejšo dedno napako telet črno-bele pasme. Teleta so manjša, imajo simetrično artrogripozno in popačeno obliko vratnih ali prsnih vretenc. Najpogostejše opazimo skrajšan vrat in skoliozo. Anomalije na vretencih so lahko hemivretenca, združevanje vretenc med sabo in vretenc z rebri, skriviljenost reber in nepravilne oblike na vretencih. Homozigoti pogosto poginejo že pred rojstvom. *Arahnornomelia* je prirojena napaka skeletnega sistema, ki daje novorojeni živali pajkast videz. Opisana je pri teletih sivorjave pasme in simentalcih. Deformirane so predvsem obrazne kosti in distalni deli zadnjih okončin, opisujemo tudi kostno dolihostenomelijo (nenormalno dolge in tanke okončine). Kosti okončin so tudi bolj krhke in spontani zlomi med telitvijo lahko poškodujejo kravo. *Smrtonosno skrajšanje hrbtenice* je redka napaka skeletnega sistema. Teleta so bistveno manjša in hrbtenica je nesorazmerna. Vretenca so lahko združena, njihovo število je različno, samo telo vretenc pa je nepravilne oblike in velikosti. V vratnem in prsno-ledvenem področju vretenca pogosto tudi niso poravnana. *Perosomus acaudatus* in *Perosomus elumbis* sta izraza, ki označujeta nepopolno razvitost hrbtenice. Teletu lahko manjka le rep (*Perosomus acaudatus*) ali pa tudi del križnega, celo ledvenega dela (*Perosomus elumbis*). Manjkajoči rep po navadi ne predstavlja nevarnosti za življenje, medtem ko teleta s *Perosomus elumbis* ne preživijo, saj manjka čvrsta opora za zadnje okončine, ki so pri tem stanju tudi zelo nerazvite. *Sindaktilija* ("noga mule") je znana napaka, pri kateri so prsti združeni. Izraženost napake zelo variira. Običajno so bolj prizadete sprednje okončine in desna stran bolj od leve.

Prirojene napake kože: *Ihtioza* je difuzna hiperkeratinizacija kože. Koža je podobna ribji, od tod ime. Poznamo dve obliki ihtioze. *Ichthyosis fetalis* ali "goveji harlekin fetus" je prirojena in zelo resna napaka, ki ni združljiva z življenjem. *Ichthyosis congenita* je milejša oblika in prizadete živali lahko živijo dlje. V obeh primerih je koža pokrita s velikimi bodičastimi ploskvami, med katerimi so globoke zareze, kot nekakšen usnjen oklep.

Ključne besede: dedne bolezni; centralni živčni sistem, bolezni – genetika; kožne bolezni – genetika; kost, bolezni – genetika; govedo