



Video-assisted thoracoscopic resection of a Hattori's cyst in the posterior mediastinum: a case report

Videotorakoskopska resekcija Hattorijsve ciste v posteriornem mediastinumu: prikaz primera

Matic Domjan,¹ Daja Šekoranja,² Matevž Srpčič¹

Abstract

First reported by Hattori in 2004, the mediastinal cyst with Mullerian differentiation is a rather new finding. We present a case of a 51-year-old woman with a cystic formation in the left paravertebral space at the level of 4th and 5th thoracic vertebrae, which was discovered on an MRI scan. We have performed a video-assisted thoracoscopic (VATS) resection of the cyst. Histological and immunohistochemical staining showed a ciliated cyst with Mullerian differentiation (i.e. Hattori's cyst). To our knowledge, only 31 cases have been described in the literature so far. Data suggests their prevalence may be higher since they are often found incidentally and are typically asymptomatic.

Izveček

Mediastinalna cista z Mullerjevo diferenciacijo, ki jo je odkril Hattori leta 2004, je sorazmerno nova najdba. Predstavljamo primer 51-letne bolnice s cistično formacijo v levem paravertebralnem prostoru na višini 4. in 5. prsnega vretenca, ki je bila odkrita z magnetno-rezonančnim slikanjem (MRI). Napravili smo videotorakoskopsko (VATS) resekcijo ciste. Histomorfološko in imunohistokemično so bile spremembe v skladu s cisto z Mullerjevo diferenciacijo (t.i. Hattorijsva cista). Po naših podatkih je bilo v literaturi doslej objavljenih le 31 primerov. Upoštevajoč te podatke je verjetno prevalenca takšnih mediastinalnih cist višja, saj gre za naključno najdbo, ki praviloma ne povzroča simptomov.

¹ Department of Thoracic Surgery, Division of Surgery, University Medical Centre Ljubljana, Ljubljana, Slovenia

² Institute of Pathology, Medical Faculty, University of Ljubljana, Ljubljana, Slovenia

Correspondence / Korespondenca: Matic Domjan, e: matic.domjan@gmail.com

Key words: Hattori; mediastinum; Mullerian cyst; VATS

Ključne besede: Hattori; mediastinum; cista z Mullerjevo diferenciacijo; VATS

Received / Prispelo: 15. 3. 2020 | **Accepted / Sprejeto:** 24. 4. 2020

Cite as / Citirajte kot: Domjan M, Šekoranja D, Srpčič M. Video-assisted thoracoscopic resection of a Hattori's cyst in the posterior mediastinum: a case report. 2021;90(7-8):399-402. **DOI:** <https://doi.org/10.6016/ZdravVestn.3049>



Copyright (c) 2021 Slovenian Medical Journal. This work is licensed under a Creative Commons Attribution-NonCommercial 4.0 International License.

1 Introduction

A case of a ciliated cyst with Mullerian differentiation in the posterior mediastinum was first described by Hattori in 2004. He suggested Mullerian origin due to female preponderance of ciliated cysts as well as their morphological resemblance to fallopian tubes (i.e. ciliated epithelium with underlying smooth muscle layer) (1). As similar reports of mediastinal cysts with Mullerian differentiation followed, it became increasingly clear that they are usually found in female patients aged 40 to 60 years, are often asymptomatic and their true incidence is still unknown (2-18). The general treatment recommendation for symptomatic and asymptomatic mediastinal cysts alike is surgical resection (19).

2 Case report

We present a case of a 51-year-old woman referred to our outpatient clinic due to a cystic formation in the left paravertebral space, behind the aorta, at the level of 4th and 5th thoracic vertebrae (Figure 1). This well defined lesion was discovered on an MRI scan while running diagnostics for middle back pain. We opted for a video-assisted thoracoscopic surgery (VATS) resection of the cyst.

Two 5 mm ports were made in the 4th intercostal

space and one 11 mm port in the 5th intercostal space. The lung was retracted anteriorly to obtain good visualization of the aorta and the paravertebral cyst. The parietal pleura was opened with a harmonic scalpel and the cyst dissected completely from the chest wall and the aorta.

A 20 Fr chest tube was inserted through the incision in the anterior axillary line. The total duration of the procedure (skin to skin) was 32 minutes, there was no blood loss. Postoperative recovery was uneventful. The chest tube was removed on postoperative day one.

Histologically, a unilocular cyst was present in the specimen. The cyst was lined by a single layer of non-stratified cuboid to columnar ciliated epithelium that included three different cell types, the ciliated, secretory and intercalated. The subepithelial lamina propria was rather scarce, with smooth muscle surrounding the whole of the cyst (Figure 2A). The first morphological impression of the lesion was rather reminiscent of a fallopian tube. Immunohistochemically, epithelial cells were diffusely positive for WT1, PAX8 and ER (Figure 2B-D), and uniformly negative for calretinin. Due to its histomorphological and immunohistochemical characteristics, the lesion was signed-out as mediastinal cyst with Mullerian differentiation, i.e. Hattori's cyst.

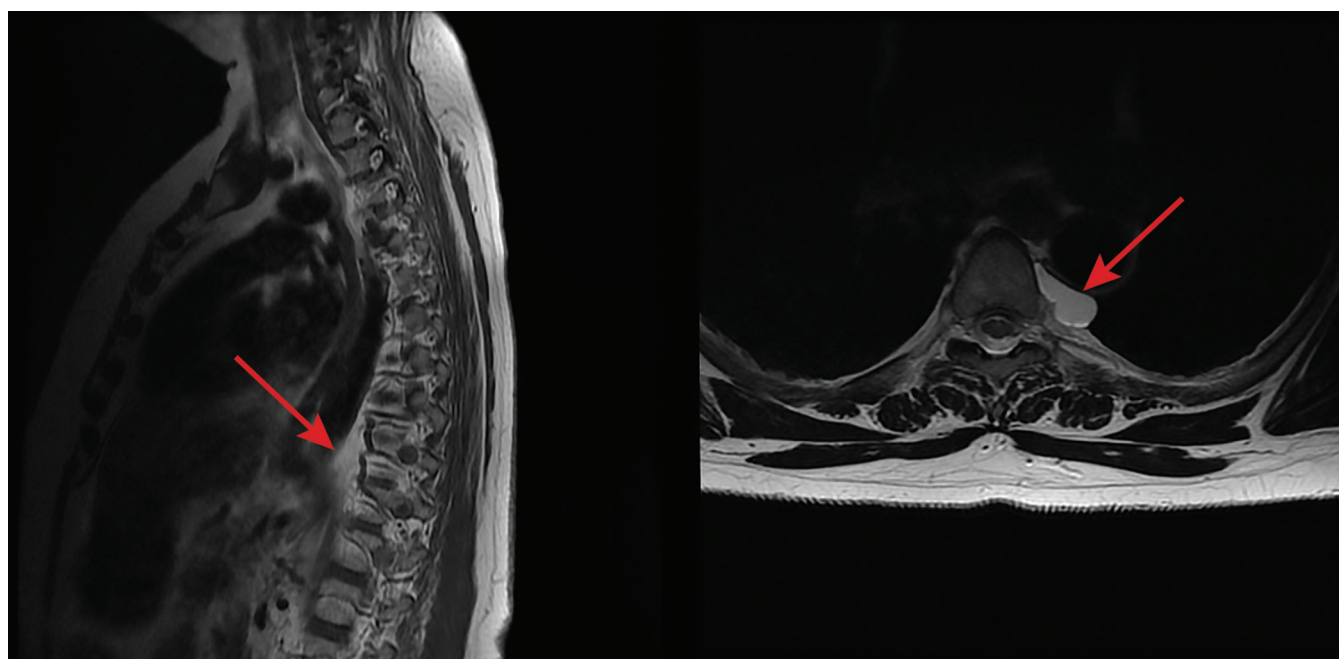


Figure 1: Chest MRI showed a cystic formation in the left paravertebral space at the level of 4th and 5th thoracic vertebrae.

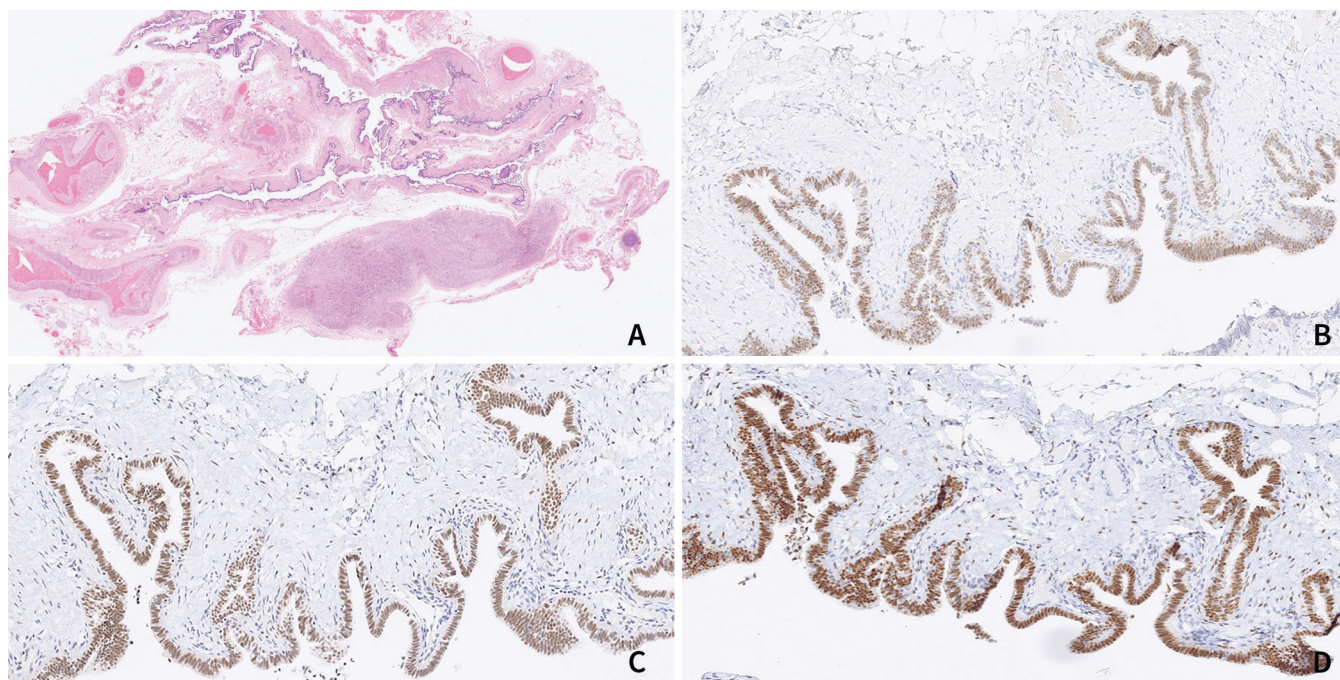


Figure 2: Hattori's cyst in the posterior mediastinum (A), immunohistochemically positive for (B) PAX8, (C) WT1 and (D) oestrogen receptors (A- 1,25x magnification, B-D 10x magnification).

On follow-up visit, the patient appeared to have no remarkable symptoms other than mild pain following the procedure, whereas the back pain persisted and did not change.

3 Discussion

The treatment of choice for mediastinal cysts is complete resection, preferably by VATS. It will provide a definitive diagnosis, exclude the possibility of malignancy and prevent the development of symptoms and possible complications. Morbidity, mortality and recurrence rates associated with resection are very low. In patients unfit for surgery, CT-guided percutaneous fine-needle evacuation is a possible less invasive treatment modality, although its recurrence rates are higher (19,20).

The presence of three types of cells in the cyst epithelium (i.e. ciliated, secretory and intercalated) is typical for a fallopian tube-type epithelium. Mullerian differentiation was demonstrated immunohistochemically with positive WT1, PAX8 and ER stains.

In the differential diagnosis of mediastinal cysts one must also consider simple mesothelial cysts, thymic cysts and bronchogenic cysts. Simple mesothelial cysts are lined by a single layer of cuboidal, non-ciliated epithelium, which is immunohistochemically WT1

and calretinin positive, and PAX8 and ER negative. In contrast to Hattori's cysts, thymic cysts typically present in the anterior mediastinum and include remnants of thymic tissue in the cyst wall. Bronchogenic cysts are lined by ciliated epithelium, just like Hattori's cyst, but in contrast to the latter, bronchogenic cyst epithelium contains goblet cells as well. Immunohistochemical characteristics differ, too, as bronchogenic cyst lack Mullerian differentiation and are therefore negative for WT1, PAX8 and ER.

Reviewing the literature, we have found 31 reports of Hattori's cysts described so far. Its true incidence is still unclear. Most papers on Hattori's cysts are case reports or small case series with only one larger series reported so far by Thomas-de-Montpréville et al. They published a systematic analysis of 163 mediastinal cysts, nine (5.5%) of which showed Mullerian differentiation. Most reported Hattori's cyst were asymptomatic and accidental findings, suggesting that a vast majority of these lesions probably go unrecognised and that their true incidence is underestimated (1-18).

4 Conclusion

Mediastinal cysts with Mullerian differentiation are a rather newly described entity. Data suggests their prevalence may be higher since they are often

found incidentally and are typically asymptomatic (1-9,11,13,17). With the widespread use of minimally invasive techniques, complete resection is the most sensible treatment of posterior mediastinal cysts since it provides a definitive histological diagnosis and prevents possible symptoms and complications.

Conflict of interest

None declared.

Informed consent of the patient

Written informed consent for publication was obtained from the patient.

References

- Hattori H. Ciliated cyst of probable müllerian origin arising in the posterior mediastinum. *Virchows Arch.* 2005;446(1):82-4. DOI: [10.1007/s00428-004-1087-0](https://doi.org/10.1007/s00428-004-1087-0) PMID: 15480767
- Hattori H. High prevalence of estrogen and progesterone receptor expression in mediastinal cysts situated in the posterior mediastinum. *Chest.* 2005;128(5):3388-90. DOI: [10.1378/chest.128.5.3388](https://doi.org/10.1378/chest.128.5.3388) PMID: 16304289
- Businger AP, Frick H, Sailer M, Furrer M. A ciliated cyst in the posterior mediastinum compatible with a paravertebral Müllerian cyst. *Eur J Cardiothorac Surg.* 2008;33(1):133-6. PMID: 17977003
- Sekimura A, Iwai S, Funasaki A, Motono N, Usuda K, Uramoto H. Müllerian cyst in posterior mediastinum: A report of a case. *Int J Surg Case Rep.* 2018;49:163-5. DOI: [10.1016/j.ijscr.2018.06.037](https://doi.org/10.1016/j.ijscr.2018.06.037) PMID: 30015213
- Tsai PC, Yeh YC, Hsu PK, Wu YC. "No drain" uniportal thoracoscopic resection for posterior mediastinal paravertebral Müllerian cyst. *Ann Transl Med.* 2018;6(23):462. DOI: [10.21037/atm.2018.10.63](https://doi.org/10.21037/atm.2018.10.63) PMID: 30603650
- Miura H, Miura J, Hirano H. Mediastinal cysts with Müllerian differentiation. *Respirol Case Rep.* 2018;6(5):e00324. DOI: [10.1002/rrc2.324](https://doi.org/10.1002/rrc2.324) PMID: 29750109
- Chao C, Vanguri V, Uy K. Robot-Assisted Thoracoscopic Resection of a Posterior Mediastinal Müllerian Cyst. *Case Rep Pulmonol.* 2018;2018:1424275. DOI: [10.1155/2018/1424275](https://doi.org/10.1155/2018/1424275) PMID: 29535882
- Lee JE, Cha YK, Kim JS, Choi JH, Han KM. Müllerian Cyst in Posterior Mediastinum in a Young Woman. *Balkan Med J.* 2018;35(2):216-8. DOI: [10.4274/balkanmedj.2017.0896](https://doi.org/10.4274/balkanmedj.2017.0896) PMID: 29180343
- Yasukawa M, Uchiyama T, Ohbayashi C, Kawaguchi T, Kawai N, Sawabata N, et al. A case of a Müllerian cyst arising in the posterior mediastinum. *Oxf Med Case Rep.* 2018;2018(11):omy080. DOI: [10.1093/omcr/omy080](https://doi.org/10.1093/omcr/omy080) PMID: 30319783
- Mowad R, Samra NS, Rao V. A Müllerian Cyst Resected From the Posterior Mediastinum. *J La State Med Soc.* 2017;169(2):43-7. PMID: 28414660
- Thomas-de-Montpréville V, Dulmet E. Cysts of the posterior mediastinum showing müllerian differentiation (Hattori's cysts). *Ann Diagn Pathol.* 2007;11(6):417-20. DOI: [10.1016/j.anndiagpath.2006.12.011](https://doi.org/10.1016/j.anndiagpath.2006.12.011) PMID: 18022126
- Batt RE, Mhawech-Fauceglia P, Odunsi K, Yeh J. Pathogenesis of mediastinal paravertebral müllerian cysts of Hattori: developmental endosalpingiosis-müllerianosis. *Int J Gynecol Pathol.* 2010;29(6):546-51. DOI: [10.1097/PGP.0b013e3181e3640a](https://doi.org/10.1097/PGP.0b013e3181e3640a) PMID: 20881858
- Kobayashi S, Inoue T, Karube Y, Hayama M, Oyaizu T, Honma K, et al. A case of Müllerian cyst arising in posterior mediastinum. *Ann Thorac Cardiovasc Surg.* 2012;18(1):39-41. DOI: [10.5761/atcs.cr.11.01678](https://doi.org/10.5761/atcs.cr.11.01678) PMID: 21881341
- Simmons M, Duckworth LV, Scherer K, Drew P, Rush D. Müllerian cysts of the posterior mediastinum: report of two cases and review of the literature. *J Thorac Dis.* 2013;5(1):E8-10. DOI: [10.3978/j.issn.2072-1439.2012.07.10](https://doi.org/10.3978/j.issn.2072-1439.2012.07.10) PMID: 23372963
- Chon SH, Im UJ, Song DS. Paravertebral mediastinal Müllerian cyst resected by video assisted thoracoscopic surgery. *J Thorac Dis.* 2015;7(3):E47-9. DOI: [10.3978/j.issn.2072-1439.2014.12.05](https://doi.org/10.3978/j.issn.2072-1439.2014.12.05) PMID: 25922749
- Weedle R, Conway K, Saftic I, Soo A. Posterior mediastinal Müllerian cyst: a rare cause of pain in a young woman. *Asian Cardiovasc Thorac Ann.* 2017;25(6):466-8. DOI: [10.1177/0218492317716588](https://doi.org/10.1177/0218492317716588) PMID: 28605953
- Lee SJ, Hwang CS, Park DY, Huh GY, Lee CH. A ciliated cyst with müllerian differentiation arising in the posterior mediastinum. *Korean J Pathol.* 2014;48(5):401-4. DOI: [10.4132/KoreanJPathol.2014.48.5.401](https://doi.org/10.4132/KoreanJPathol.2014.48.5.401) PMID: 25366081
- Skancke MD, Auzenne TD, Tabbara SO, Mortman KD. Thoracoscopic Resection of Multiple Müllerian Cysts. *Ann Thorac Surg.* 2015;100(5):1898-900. DOI: [10.1016/j.athoracsur.2015.01.076](https://doi.org/10.1016/j.athoracsur.2015.01.076) PMID: 26522538
- Le Pimpec-Barthes F, Cazes A, Bagan P, Badia A, Vlas C, Hernigou A, et al. Les kystes du médiastin: approche diagnostique et traitement. *Rev Pneumol Clin.* 2010;66(1):52-62. DOI: [10.1016/j.pneumo.2009.12.009](https://doi.org/10.1016/j.pneumo.2009.12.009) PMID: 20207297
- Li L, Zeng XQ, Li YH. CT-guided percutaneous large-needle aspiration and bleomycin sclerotherapy for bronchogenic cyst: report of four cases. *J Vasc Interv Radiol.* 2010;21(7):1045-9. DOI: [10.1016/j.jvir.2010.03.009](https://doi.org/10.1016/j.jvir.2010.03.009) PMID: 2053755