

Reliability of haemophilia early arthropathy detection with ultrasound (HEAD-US) in children: a comparative magnetic resonance imaging (MRI) study

Domen Plut^{1,2}, Barbara Faganel Kotnik³, Luka Pusnik², Peter Slak^{1,2}, Ziga Snoj^{1,2}, Vladka Salapura^{1,2}

¹ Clinical Radiology Institute, University Medical Centre Ljubljana, Ljubljana, Slovenia

² Faculty of Medicine, University of Ljubljana, Ljubljana, Slovenia

³ Department of Haematology and Oncology, Children's Hospital, University Medical Centre Ljubljana, Slovenia

Radiol Oncol 2022; 56(4): 471-478.

Received 23 August 2022

Accepted 4 September 2022

Correspondence to: Assist. Prof. Domen Plut, M.D., Ph.D., Clinical Radiology Institute, University Medical Centre Ljubljana, Zaloška cesta 7, SI-1000 Ljubljana, Slovenia. E-mail: plut.domen@gmail.com

Disclosure: No conflicts of interest were disclosed.

This is an open access article distributed under the terms of the CC-BY license (<https://creativecommons.org/licenses/by/4.0/>).

Background. Ultrasound (US) has been proven to be reliable in the assessment of early haemophilic arthropathy in the adult haemophilic population, however few studies so far focused on the reliability of US specifically in the paediatric haemophilic population. We were interested if the changing appearance of the growing bone hinders the ultrasonographic evaluation of the pathologic processes caused by haemophilic arthropathy. The aim of the study was to assess the reliability of US for evaluation of haemophilic arthropathy in children in comparison to magnetic resonance imaging (MRI).

Patients and methods. The study included all children aged 6 years or more with severe haemophilia in the country ($n = 10$). We assessed their elbows, knees, and ankles bilaterally by US and compared the results to the MRI as the reference standard. Pearson correlation coefficient (r) was used to analyse correlation.

Results. The correlation with MRI for the US for the total score was excellent for all joints ($r = 0.849$ for the elbows, $r = 1$ for knees, $r = 0.842$ for ankles). The correlation of scores for specific joint components showed fair, moderate, or excellent correlation for all joint components in all joints. The correlation was the lowest for the evaluation of cartilage and bone in the ankles ($r = 0.546$ and $r = 0.478$) and bone in the elbows ($r = 0.499$).

Conclusions. Our study proved that US using the HEAD-US method performed by paediatric radiologists is a reliable tool for detection and quantification of haemophilic arthropathy in children in comparison to MRI.

Key words: haemophilia; children; haemophilic arthropathy; HEAD-US; ultrasound; magnetic resonance imaging

Introduction

Haemophilic arthropathy (HA) is caused by recurrent bleeding into joints and is characterized by synovial hypertrophy with hemosiderin deposition, cartilage destruction, and structural changes of subchondral bone. Long-term repeated hemarthroses lead to joint destruction and severe func-

tional impairment.¹ As the development of HA ordinarily begins during childhood, albeit with minimal changes, early detection is indispensable. Early recognition of subclinical arthropathy based on the imaging modalities is fundamental as it enables appropriate prophylactic treatment modification and prevents further disease progression.^{2,3} Among the imaging tools, magnetic resonance

imaging (MRI) with its high spatial and contrast resolution is superior to the other modalities and enables the most precise assessment of early arthropathic changes.⁴ As MRI is a time-consuming modality with limited availability, a high cost, and requires sedation in young children, routine assessment of multiple joints with it is not feasible. Ultrasound (US) has been proven to be highly reliable in the assessment of early inflammatory and destructive joint changes in the adult haemophilic population⁵⁻⁷, however very few studies so far focused on the reliability of US in the paediatric haemophilic population. The US has even more advantages in the paediatric population: it is a safe technique without radiation, it enables a quick assessment of multiple joints, and sedation is not required even in young children. Thus, with possible detection of joint effusions, synovial hypertrophy, cartilage changes, and subchondral bone erosions it may be an invaluable tool for recognition of sub-clinical HA in children.^{8,9}

We were interested if the changing appearance of the growing bone hinders the ultrasonographic evaluation of the pathologic processes caused by HA. Hitherto, a paucity of data has been published regarding US measurements of hyaline cartilage thickness in healthy children in comparison to MRI measurements. Consequently, published values are not standardised and require further research to distinguish unaffected growing bone from the pathologic processes caused by HA.¹⁰⁻¹⁴ The aim of our study was to assess the reliability of the US for evaluation of haemophilic arthropathy in children in comparison to the MRI.

Patients and methods

Board approval

The study was approved by the National Medical Ethics Committee (reference number 0120-523/2015-8). The participants in this study were children, therefore informed consent for the participants was signed by their parents. The participants, however, gave their informed assent to the study. Research was conducted following the Helsinki Declaration.

Patients

The study included all children with severe haemophilia A in the country. The patients were recruited at the Slovenian National Haemophilia Comprehensive Care Centre at the University

Medical Centre Ljubljana. The inclusion criteria were: diagnosis of severe haemophilia A, prophylactic treatment with factor concentrates, and age between 6 and 18 years. The age of 6 years as the low cut-off was chosen to avoid the need for anaesthesia for the MRI. The exclusion criteria were non-cooperation and contraindications for the MRI. Patient history (history of joint bleeds, haemophilia joint health score (HJHS), prophylaxis information) was retrieved from their medical records.

Ultrasonography

A ProSound F75 US scanner with a 13–5 MHz electronic linear-array transducer (Hitachi Aloka Medical, Ltd. Tokyo, Japan) was used to perform the US examinations. US was performed by an experienced paediatric radiologist (7 years of subspecialty experience). The assessment of each joint was made using the HEAD-US protocol and scoring method. This standardised method includes bilateral systematic evaluation of the elbows, knees, and ankles in defined positions for the detection of hypertrophied synovium and osteochondral damage. The results for each joint are expressed on a 9-point scale (0–8; 0 corresponds to the best joint condition, while 8 corresponds to the worst joint condition).⁸ The total scanning time per patient for all joints combined was approximately 20 minutes. A series of images and clips from all examinations for each patient were additionally independently reviewed and scored by another paediatric radiologist (2 years of subspecialty experience) to determine the inter-rater reliability. Both US reviewers were blinded to the results of MRI examinations.

Magnetic resonance imaging

MRI was performed on a 3T Achieva unit (Philips Healthcare, Eindhoven, The Netherlands). Phased array coils were used for the imaging of each joint. The protocol included 3D T2*-weighted water selective gradient echo sequence (FOV, 160×160×108mm; voxel size, 0.58×0.58×0.50mm; flip angle: 15°; TE 9.2/6.1ms; TR 26ms), and 3D proton density (PD) weighted turbo spin echo sequence (FOV, 160×160×161mm; voxel size: 0.52×0.52×0.52mm; TE 33ms; TR 1000ms). The total scanning time for each joint was approximately 15 minutes. In each patient, all joints were scanned in a single session for a total examination time around 1.5 hours. The MRI examinations were scored according to the International Prophylaxis Study Group (IPSG)

TABLE 1. Characteristics of subjects included in the study

Age: mean; range (years)	11.5; 6–17			
Age at the start of prophylaxis: mean; range (years)	3; 0.8–6.6			
Primary prophylaxis – 5 patients:	2.2; 0.8–3.8			
Secondary prophylaxis – 5 patients:	3.8; 2.5–6.6			
Duration of prophylaxis: mean; range (years)	9.1; 3.2–14.7			
Haemophilia Joint Health Score (HJHS): mean; range	0.9; 0–7			
Number of previous joint bleeds per patient: mean; range	16.2; 0–83			
Number of previous joint bleeds per joint: mean; range	2.5; 0–71			
Number of previous joint bleeds:	Elbows	Knees	Ankles	Overall
0 (number of joints)	14	7	9	30
1–4 (number of joints)	5	12	8	25
> 5 (number of joints)	1	1	3	5

MRI scale. The IPSC score includes evaluation of joint effusion, hypertrophied synovium with hemosiderin deposition, and osteochondral damage. The IPSC score uses an 18-point scale (0–17; 0 corresponds to the best joint condition with no disease present, while 17 corresponds to the worst joint condition with progressive arthropathy).¹⁵ The presence of HA was defined as IPSC score > 0. The scoring was performed independently by two experienced musculoskeletal radiologists (19 and 4 years of subspecialty experience) who were blinded regarding the results of the US examinations.

Statistical analysis

Descriptive statistics were obtained to describe the characteristics of the study group. Pearson correlation coefficient (r) was used to analyse the correlation between US and MRI examinations. Correlation was considered poor if r was < 0.3, fair if r was < 0.6, substantial if r was < 0.8, and excellent if r was > 0.8.¹⁶ The correlation results were graphically illustrated. The inter-rater reliability of HEAD-US and IPSC MRI scoring system for the total scores was made with Lin's concordance correlation coefficient (CCC) and for all the sub-scores using Cohen's kappa statistics (with quadratic weights). The results of US were referenced to the results of MRI in order to obtain measures of diagnostic accuracy (specificity, sensitivity, positive predictive value, and negative predictive value). Statistical analysis was performed using IBM SPSS Statistics for Windows software, version 25 (IBM Corp.). A two-tailed P value < 0.05 was considered to indicate statistical significance.

Results

Patient and joint characteristics

The study group included a total of 10 patients (age range 6 to 17 years, mean age 11.5 years). In each patient, six joints (elbows, knees, and ankles bilaterally) were systematically examined first using the US, followed by MRI, according to the protocols. Altogether in the study we assessed 60 joints: 20 elbows, 20 knees, and 20 ankles.

All the patients included in the study have been receiving prophylactic treatment with clotting factor concentrates. The type of prophylaxis for the patients was primary or secondary. The patients were on three times per weekly regimen. A proportion of patients were on individual prophylactic regimens according to population-based pharmacokinetic tools. Two patients developed inhibitors to prophylactic treatment. In one patient the inhibitors were successfully eradicated by immune tolerance induction. Details on treatment and joint-bleeds history are shown in Table 1 along with other study group baseline characteristics.

Results of US and MRI

Descriptive statistics for US and MRI results are gathered in Table 2.

MRI results were used as a reference standard for joint status. The results of the correlation between US and MRI for detection and evaluation of HA in children are summarized in Table 3. The correlation with MRI for each joint type is graphically depicted in Figure 1. The correlation with MRI for US for the total score was excellent for all

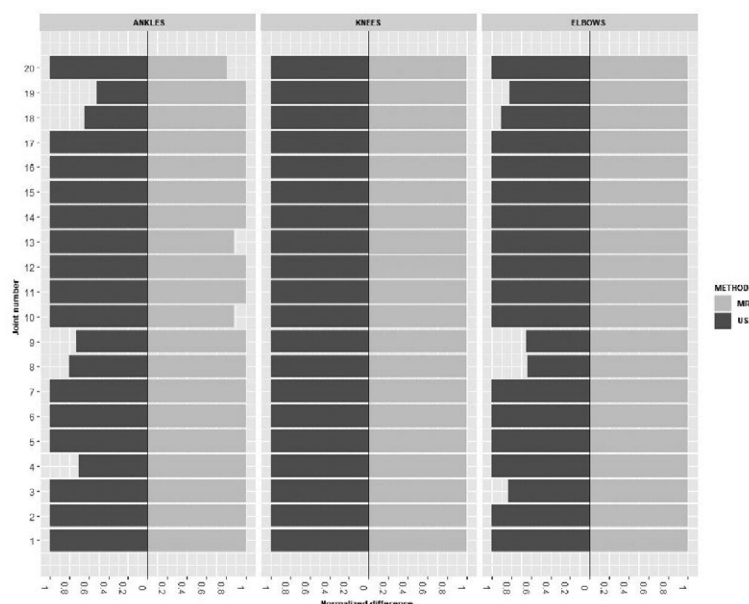


FIGURE 1. Concordance plot for depicting agreement between US and MRI scores for all three joints. Equal size of the fields denotes perfect agreement. The plots demonstrate overall an excellent agreement between the methods. It can also be observed, that in most cases of discordance, US slightly undervalued the progression of the joint disease.

joints ($r = 0.849$ for the elbows, $r = 1$ for knees, $r = 0.842$ for ankles). The correlation of scores for specific joint components showed fair, moderate, or excellent correlation for all joint components in all joints. The correlation was the lowest for the evaluation of cartilage and bone in the ankles ($r = 0.546$ and $r = 0.478$) and bone in the elbows ($r = 0.499$). Figures 2-5 show images from the study.

The inter-rater reliability of interpretation was excellent for the US examinations of all joints. The Lin's CCC values for the total scores ranged from 0.986 to 1.000. The inter-rater reliability for the MRI was also excellent for all joints with the CCC values for the total scores ranging from 0.957 to 0.993.

Measures of diagnostic accuracy

Our study included 49 joints (15 elbows, 20 knees, and 14 ankles) with no signs of HA on MRI (IPSG scores were 0) and 11 joints with HA (5 elbows and 6 ankles). The IPSG MRI score of joints with HA ranged from 1 to 8, mean was 4.8. Two joints that showed signs of HA on MRI (two elbows in the same patient with IPSG MRI scores 4 and 1) were scored 0 on the US. There was one false positive on the US, an ankle with a score of 1. The calculated measures of diagnostic accuracy for HEAD-US are presented in Table 4.

TABLE 2. Descriptive statistics for US and MRI assessment scores

Joints	Statistic	US	MRI
Elbows	% of zeros	85	75
	Median	0	0
	Mean	0.35	1.05
	SD	0.93	2.82
Knees	% of zeros	100	100
	Median	0	0
	Mean	0	0
	SD	0	0
Ankles	% of zeros	65	70
	Median	0	0
	Mean	0.8	1.6
	SD	1.2	2.2
Overall	% of zeros	83.3	81.7
	Median	0	0
	Mean	0.38	0.88
	SD	0.92	2.16

TABLE 3. The results of the correlation analysis

US vs MRI	Pearson's correlation coefficient (r)		
	Elbows	Knees	Ankles
Total score	0.849	1	0.842
Synovium	0.841	1	0.722
Cartilage	0.829	1	0.546
Bone	0.499	1	0.478

Note: all the reported correlations are statistically significant ($p < 0.05$).

Discussion

Our study aimed to evaluate the reliability of US (HEAD-US scanning protocol and scoring method) for the detection and evaluation of haemophilic arthropathy in children in comparison to MRI (IPSG MRI scoring scale). We evaluated the three most commonly affected joints (ankles, knees, and elbows) in all children with severe haemophilia A in our country ($n = 10$). Overall, we evaluated 60 joints. The results of the correlation analysis showed a very high correlation for the evaluation of haemophilic arthropathy between the US and

TABLE 4. Measures of diagnostic accuracy for detection of haemophilic arthropathy by US (HEAD-US) in comparison to MRI (IPSG MRI score) as the reference standard

Specificity	81.8%
Sensitivity	98%
Positive predictive value	90%
Negative predictive value	96%

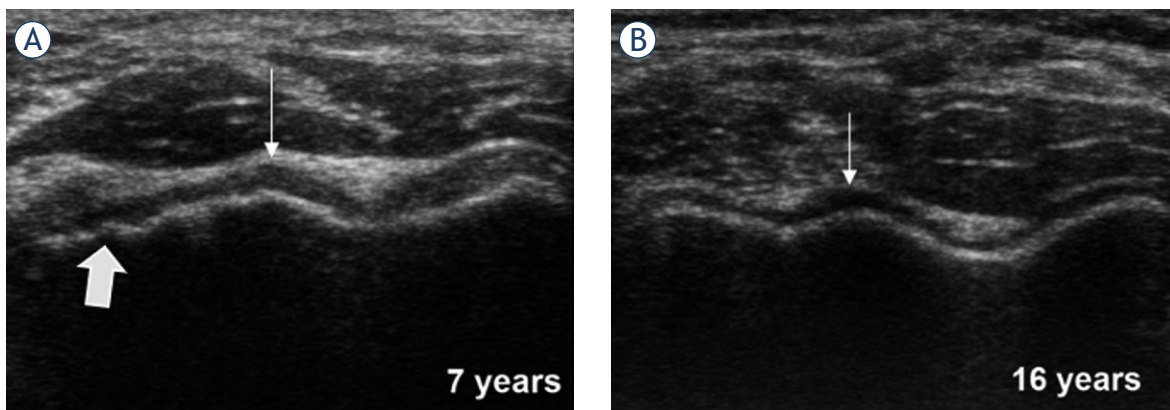


FIGURE 2. Anterior transverse US images over the distal humeral epiphysis in a 7-years and 16-years old healthy boys. A wavy osteochondral surface consisting of the convex capitellum and the concave trochlea is shown. Note the age-dependent anatomic differences: subchondral bony surface in the younger child (**A**) shows physiological irregularities (thick arrow); the articular cartilage, which appears as a uniform hypoechoic band overlying the subchondral bone (thin arrows), is thinner in the older child (**B**).

MRI for all the joints ($r = 0.849$ for elbows; $r = 1$ for knees; $r = 0.842$ for ankles). Excellent inter-rater reliability for both the US and MRI in our study further supports the validity of both methods for haemophilia imaging in children.

These results show that the HEAD-US method is reliable in comparison to MRI for the detection and quantification of HA in children. High specificity and sensitivity (81.8% and 98%) confirm the method as a dependable tool for the recognition of the presence of HA, whereas high correlation

proves the method is also reliable in the quantification of the disease progression. Our results indicate that US is reliably applicable for all evaluated joints (elbows, knees, and ankles), however the detailed analysis of the joint components (synovium, cartilage, bone) showed some important differences. The correlation between the methods was the lowest for the evaluation of the cartilage and bone changes of the ankles ($r = 0.546$ and 0.478) and bone changes of the elbows ($r = 0.499$) in comparison to other joint components ($r > 0.7$). The

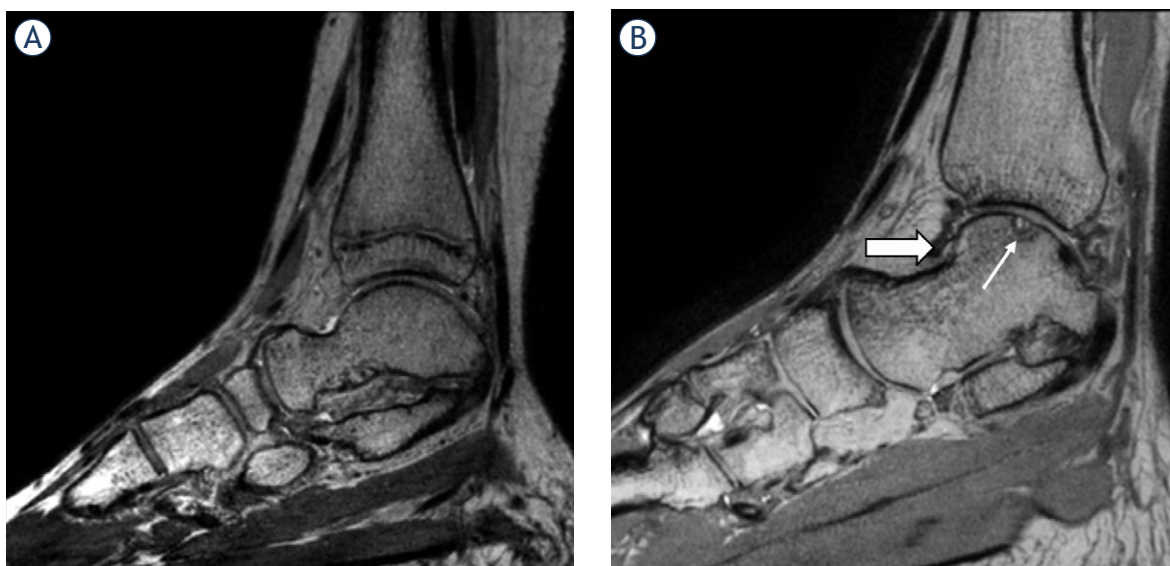


FIGURE 3. PD weighted MRI of ankles in sagittal plane. Image (**A**) shows an ankle with no signs of haemophilic arthropathy in an 11-years old boy, while image (**B**) shows a severely affected ankle in a 17-years old boy. The thin arrow marks a talar osteochondral defect, while the thick arrow marks synovial hypertrophy with hemosiderin deposition.

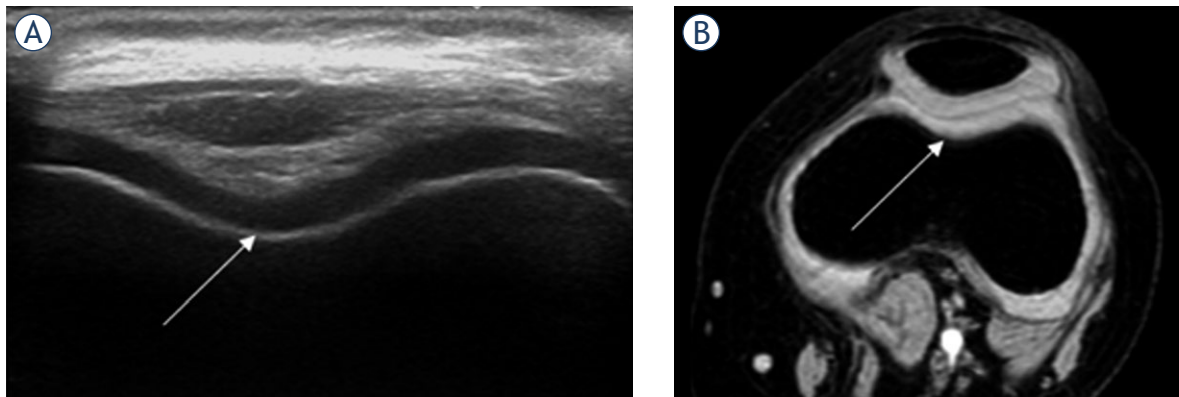


FIGURE 4. An example of good concordance between HEAD-US and MRI in a 7-years old child. US image of the femoral trochlea in the transverse plane is shown (A). T2* weighted MR image in the transverse plane (B) of the same knee is shown for comparison of the corresponding structures. The smooth bone surface and normal thickness trochlear joint cartilage with homogenous structure are shown (white arrow); the corresponding intact structures are shown on MR image. On MRI, there were also no additional arthropathic changes in the parts of the joint not visualized by the US. The images show a perfect concordance between US and MRI findings in this knee with no signs of haemophilic arthropathy.

lower correlation for the evaluation of osteochondral changes in the ankles was due to the limited visualization of the central weight-bearing part of the osteochondral surface of the ankle joint by US, which is a more commonly affected area of the joint. Comparable results were observed in our previously performed study in the adult population.¹⁷ Similarly, the lower correlation for the bone changes in the elbows was due to inability of the US to detect centrally located subchondral cysts. Nevertheless, as noted above, the overall correla-

tion between both methods for all the joint components for all the joints was still substantial. In our study in the adult population, we observed a lower correlation between the US and MRI for the detection and evaluation of synovial hypertrophy in the ankles ($r = 0.561$). In this study in the paediatric population however, this was not the case ($r = 0.722$). We believe this can be attributed to a generally better ability of US to differentiate soft tissues in children due to a higher tissue water content. As synovial hypertrophy is the earliest sign of HA, high reliability to evaluate this finding in all joints in children is important for the clinical application of the method.

In the published literature, the comparisons of the joint assessment between the US and MRI within the paediatric haemophilic population are scant. Only three studies included exclusively children within their study group. Doria *et al.* evaluated ankles and knees in children with haemophilia and von Willebrand disease and reported that if performed by experienced radiologists US is highly reliable for assessing soft-tissue abnormalities and substantially to highly reliable for assessing osteochondral changes in these joints. These results are concordant with the findings of our study. However, it is worthy to note that in their study the US interpreters were unblinded to the MRI results.⁶ Prasetyo *et al.* evaluated knees in 27 children with haemophilia, employing a complex US examination including Doppler evaluation and evaluation of hemosiderin deposits, and reported moderate correlation between the US and MRI scores.¹⁸ In another study that evaluated ankles in

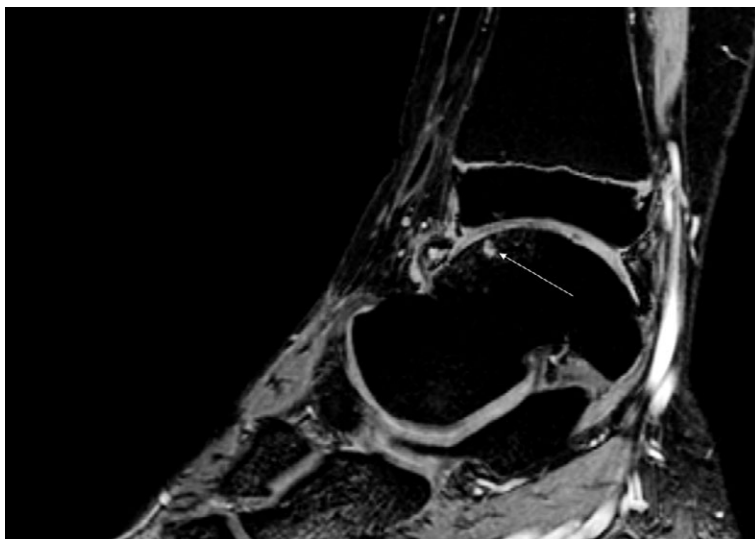


FIGURE 5. An example of a lesion causing a discordance between the US and MRI. A T2* weighted MR image of an ankle of a 16-years old boy in the sagittal plane is shown. A small subchondral cyst covered with intact cortical bone and articular cartilage (white arrow) is shown. MRI demonstrates a defect which cannot be visualized by US.

11 boys with haemophilia, Prasetyo *et al.* evaluated only the ability of US to detect hemosiderin deposits within the joint and determined that the association between the US and MRI for detection of hemosiderin deposits was weak.¹⁹ Additional two studies included children as a part of their study group. Sierra Aisa *et al.* included patients with HA between the age of 4-82 years and reported sensitivity, specificity, positive predictive value, and negative predictive value for diagnosing HA within the same interval as presented in our study.⁵ Acharya *et al.* evaluated the use of US with Power Doppler in comparison to contrast-enhanced MRI to detect haemophilic synovitis in subjects between the ages of 6-60 years and concluded that the correlation between the methods is good.²⁰ All of the aforementioned studies already showed great potential for the use of US in the diagnostics of HA in children, however, each study had some limitations, such as different and complex US protocols or evaluation limited to specific joints or joint components. Therefore, in our study we used a simplified standardized US protocol (HEAD-US) for the joint evaluation, which allows quick examination with great repeatability, we systematically evaluated all three most commonly involved joints in haemophilia, and made sure the US evaluators were blinded to the results of the MRI examination.

The findings of the currently presented study and our previously published study in the adult population¹⁷ made us reconsider our clinical practice. Due to the good availability of US machines and reliability of the US to detect even early HA in clinically asymptomatic joints, we incorporated the US into our regular clinical yearly follow-up of paediatric patients with haemophilia. All the children with severe haemophilia in our country have been included in the screening program, even children younger than 6 years old. During this time, we found early HA in clinically asymptomatic joints with no previously recorded bleeds in two children and consequently modified their prophylactic treatment regimen.

The study had some research design limitations. Although our study group included all children with severe haemophilia A in the country, due to the rarity of the disease, the overall number of patients was relatively low ($n = 10$). Furthermore, we couldn't include the youngest children with haemophilia aged under 6 years due to the requirement of general anaesthesia to perform MRI in this group of children. Most joints we evaluated in our study were either healthy or had only early

HA. This is because HA is a progressive chronic disease and all of the included patients had prophylactic treatment since the early youth, therefore more progressive disease forms were prevented. However, extensive studies evaluating the value of US in comparison with MRI in patients with progressive HA have been already performed in the adult population and, moreover, diagnosing early HA remains the challenge for today's medicine.

Conclusions

Our study proved that US using the HEAD-US method performed by paediatric radiologists is a reliable tool for detection and quantification of haemophilic arthropathy in children in comparison to MRI. Due to its simplicity, availability, and reliability, HEAD-US is an invaluable tool in diagnostics and regular follow-up of children with haemophilia and can be safely included into the regular screening protocols of children with severe haemophilia where possible. Further studies are needed to answer some important questions regarding the use of HEAD-US in children with haemophilia: what is the ideal start age for the screening? How often should the screening be performed during the childhood, and who should perform the scanning (radiologist, clinician, physiotherapist)?

Acknowledgments

This study was funded by Pfizer Inc., USA. The authors have no competing interests. We would like to thank Anja Silič, Marko Gabrijelčič, Damjana Ključevšek, and Lidija Kitanovski for their contribution to the study.

References

1. Gualtierotti R, Solimeno LP, Peyvandi F. Hemophilic arthropathy: current knowledge and future perspectives. *J Thromb Haemost* 2021; **19**: 2112-21. doi: 10.1111/jth.15444
2. Plut D, Faganel Kotnik B, Preložnik Zupan I, Ključevšek D, Vidmar G, Snoj Ž, et al. Detection and evaluation of haemophilic arthropathy: which tools may be considered more reliable. *Haemophilia* 2021; **27**: 156-63. doi: 10.1111/hae.14153
3. Pergantou H, Platokouki H, Matsinos G, Papakonstantinou O, Papadopoulos A, Xafaki P, et al. Assessment of the progression of haemophilic arthropathy in children. *Haemophilia* 2010; **16**: 124-9. doi: 10.1111/j.1365-2516.2009.02109.x
4. Kilcoyne RF, Nuss R. Radiological assessment of haemophilic arthropathy with emphasis on MRI findings. *Haemophilia* 2003; **9**: 57-64. doi: 10.1046/j.1365-2516.9.s1.11.x

5. Sierra Aisa C, Lucía Cuesta JF, Rubio Martínez A, Fernández Mosteirín N, Iborra Muñoz A, Abío Calvete M, et al. Comparison of ultrasound and magnetic resonance imaging for diagnosis and follow-up of joint lesions in patients with haemophilia. *Haemophilia* 2014; **20**: e51-7. doi: 10.1111/hae.12268
6. Doria AS, Keshava SN, Mohanta A, Jarrin J, Blanchette V, Srivastava A, et al. Diagnostic accuracy of ultrasound for assessment of hemophilic arthropathy: MRI correlation. *Am J Roentgenol* 2015; **204**: W336-47. doi: 10.2214/AJR.14.12501
7. De la Corte-Rodriguez H, Rodriguez-Merchan EC, Jimenez-Yuste V. Point-of-care ultrasonography in orthopedic management of hemophilia: multiple uses of an effective tool. *HSS J* 2018; **14**: 307-13. doi: 10.1007/s11420-018-9604-x
8. Martinoli C, Casa Alberighi O Della, Di Minno G, Graziano E, Claudio Molinari A, Pasta G, et al. Development and definition of a simplified scanning procedure and scoring method for haemophilia early arthropathy detection with ultrasound (HEAD-US). *Thromb Haemost* 2013; **109**: 1170-9. doi: 10.1160/TH12-11-0874
9. Di Minno MND, Iervolino S, Soscia E, Tosoletto A, Coppola A, Schiavulli M, et al. Magnetic resonance imaging and ultrasound evaluation of "healthy" joints in young subjects with severe haemophilia A. *Haemophilia* 2013; **19**: e167-73. doi: 10.1111/hae.12107
10. Keshava SN, Gibikote SV, Mohanta A, Poonnoose P, Rayner T, Hilliard P, et al. Ultrasound and magnetic resonance imaging of healthy paediatric ankles and knees: a baseline for comparison with haemophilic joints. *Haemophilia* 2015; **21**: e210-22. doi: 10.1111/hae.12614
11. Soliman M, Daruge P, Dertkigil SSJ, De Avila Fernandes E, Negrao JR, de Aguiar Vilela Mitraud S, et al. Imaging of haemophilic arthropathy in growing joints: pitfalls in ultrasound and MRI. *Haemophilia* 2017; **23**: 660-72. doi: 10.1111/hae.13249
12. Samanta M, Mitra S, Samui PP, Mondal RK, Hazra A, Sabui TK. Evaluation of joint cartilage thickness in healthy children by ultrasound: an experience from a developing nation. *Int J Rheum Dis* 2018; **21**: 2089-94. doi: 10.1111/1756-185X.13374
13. Spannow A, Stenboeg E, Pfeiffer-Jensen M, Fiirgaard B, Haislund M, Ostergaard M, et al. Ultrasound and MRI measurements of joint cartilage in healthy children: a validation study. *Ultraschall Med* 2010; **32**(Suppl 1): S110-6. doi: 10.1055/s-0029-1245374
14. Sidharthan S, Yau A, Almeida BA, Shea KG, Greditzer HG, Jones KJ, et al. Patterns of articular cartilage thickness in pediatric and adolescent knees: a magnetic resonance imaging-based study. *Arthrosc Sport Med Rehabil* 2021; **3**: e381-90. doi: 10.1016/j.asmr.2020.09.029
15. Lundin B, Manco-Johnson ML, Ignas DM, Moineddin R, Blanchette VS, Dunn AL, et al. An MRI scale for assessment of haemophilic arthropathy from the International Prophylaxis Study Group. *Haemophilia* 2012; **18**: 962-70. doi: 10.1111/j.1365-2516.2012.02883.x
16. Chan YH. Biostatistics 104: correlational analysis. *Singapore Med J* 2005; **46**: 153-60.
17. Plut D, Kotnik BF, Zupan IP, Kljucsek D, Vidmar G, Snoj Z, et al. Diagnostic accuracy of haemophilia early arthropathy detection with ultrasound (HEAD-US): a comparative magnetic resonance imaging (MRI) study. *Radiol Oncol* 2019; **53**: 178-86. doi: 10.2478/raon-2019-0027
18. Prasetyo M, Gatot D, Tulaar A, Pandelaki J, Bardosono S, Sukrisman L, et al. Association between US and MRI scores and correlations with urinary C-terminal telopeptide Type II collagen levels for early detection of hemophilic arthropathy of the knee. *J Phys Conf Ser* 2018; **1073**: 042022. doi: 10.1088/1742-6596/1073/4/042022
19. Prasetyo M, Mongan AE, Chozie NA, Prihartono J, Setiawan SI. Hemosiderin deposition evaluation in hemophilic ankle joints: association between US finding and gradient-recalled echo MR imaging sequence. *Insights Imaging* 2021; **12**: 1-7. doi: 10.1186/s13244-021-01050-1
20. Acharya SS, Schloss R, Dyke JP, Mintz DN, Christos P, Dimichele DM, et al. Power Doppler sonography in the diagnosis of hemophilic synovitis - a promising tool. *J Thromb Haemost* 2008; **6**: 2055-61. doi: 10.1111/j.1538-7836.2008.03160.x