

# *Mycobacterium marinum* hand infection masquerading as tinea manuum: a case report and literature review

Katarina Trčko<sup>1</sup>✉, Jurij Plaznik<sup>1</sup>, Jovan Miljković<sup>2</sup>

<sup>1</sup>Department of Dermatology and Venereal Diseases, University Medical Centre Maribor, Maribor, Slovenia. <sup>2</sup>Faculty of Medicine, University of Maribor, Maribor, Slovenia.

## Abstract

Fish tank granuloma is a rare skin infection caused by *Mycobacterium marinum*. It occurs after exposure of skin abrasions to contaminated water or infected fish. The majority of *M. marinum* infections today are fish tank-related. The most common presentation is a solitary nodule, often with sporotrichoid spread. Other presentations do not occur often. The diagnosis is often delayed because of lack of suspicion, nonspecific histopathological findings, and frequently unsuccessful cultivation. Here we present the case of a 37-year-old male with *M. marinum* skin infection, presenting as erythematous scaling plaques. Because the initial results of laboratory and histopathological examinations were negative for a fungal infection or nontuberculous mycobacteria, the patient was treated empirically with several systemic antibiotics and antifungals without any success. Finally, the diagnosis of fish tank granuloma was confirmed 3 months after the initial presentation of the patient. After the introduction of treatment with rifampicin and clarithromycin, complete clinical remission was observed after 6 months of therapy.

**Keywords:** *Mycobacterium marinum*, fish tank granuloma, hand infection, nontuberculous mycobacteria

Received: 30 March 2021 | Returned for modification: 31 May 2021 | Accepted: 3 June 2021

## Introduction

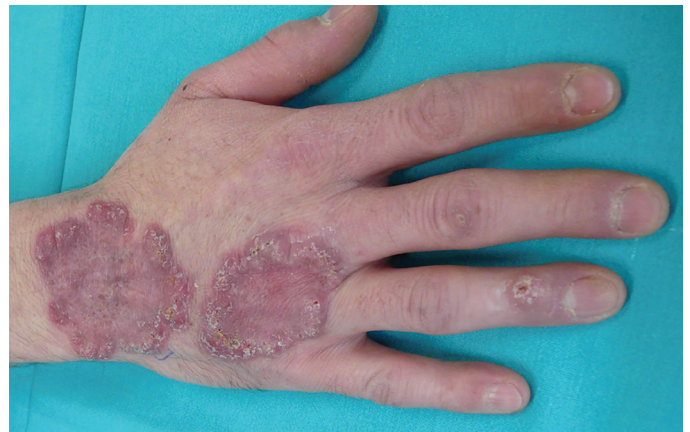*Mycobacterium marinum* is a nontuberculous mycobacterium that is present as a saprophyte in fresh and salt water. It can cause infections in fish and sporadically in humans. The organism is especially prevalent in natural or inadequately chlorinated swimming pools, and in heated aquariums. Infection in humans is uncommon and occurs when contaminated water or infected fish or shellfish come in contact with open skin wounds or abrasions. Since the first reported case of *M. marinum* skin infection in 1951 in swimmers that had swum in a contaminated pool in Sweden, several case reports and case series have been published to date (1–3). The majority of *M. marinum* infections are aquarium-related today, and therefore instead of *swimming pool granuloma* the terms *aquarium granuloma* and *fish tank granuloma* are now used (4). The typical presentation of infection is a solitary or multiple nodules or pustules, and about 25% of patients have a sporotrichoid distribution of nodular lesions (5–6). According to the literature, presentation with erythematous scaling plaques does not occur often. Here we present the case of a 37-year-old male with *M. marinum* skin infection with an unusual clinical presentation. Current diagnostic and treatment recommendations are also reviewed.

## Case report

A 37-year-old man presented with painless livid plaques on the back of his right hand that had appeared 1 year earlier (Fig. 1). The first skin lesions had appeared on the nail fold of the fourth finger as a small warty papule. The lesion grew larger, and after few months a new lesion appeared on the back of his hand and the extensor side of the right wrist. He had been treated with local antifungal and antibiotic cream. The patient was otherwise

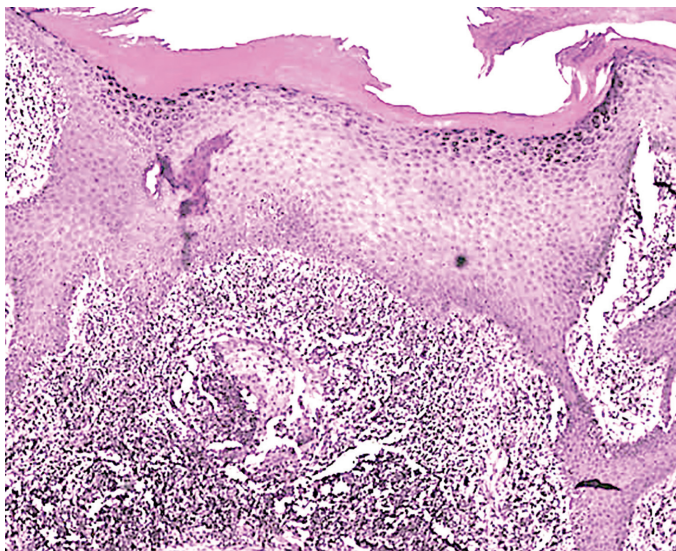
healthy. He had no history of tuberculosis or any other systemic illness. In a detailed medical history, he reported that he had had an aquarium with tropical fish, exotic snakes, and lizards for the past 5 years.

Physical examination revealed two polycyclic livid plaques with irregular hyperkeratotic elevated borders and central regression on the back of his right hand and the extensor side of the right wrist, and two hyperkeratotic papules on the extensor surface of the fourth and third fingers of his right hand. The differential diagnoses included superficial and subcutaneous fungal infections, atypical granuloma annulare, tuberculosis verrucosa cutis, verrucous lupus vulgaris, atypical mycobacterial infection, and vegetative pyoderma. Clinical examination did not reveal other skin or mucosal lesions, lymphadenopathy, or associated systemic manifestations. The Mantoux test was negative. Skin biopsies were taken for histopathological examination and culture



**Figure 1** | Fish tank granuloma: polycyclic livid plaques with irregular hyperkeratotic elevated borders and central regression on the back of the right hand and extensor side of the right wrist, and two hyperkeratotic papules on the extensor surface of the fourth and third fingers of the right hand.

for bacteria, fungi, and mycobacteria. The histopathology showed pseudoepitheliomatous hyperplasia with a nonspecific mixed inflammatory infiltrate with intraepidermal abscess and suggested chronic pyodermic inflammation (Fig. 2). Bacterial culture of the tissue identified *Staphylococcus aureus*. The results of the cultivation of *Mycobacterium tuberculosis* and atypical mycobacteria were negative, as was polymerase chain reaction (PCR) for *M. tuberculosis*. For suspected bacterial skin infection, the patient started treatment with oral clindamycin for 4 weeks without any improvement; after that, he was treated empirically with doxycycline for 4 weeks and then with itraconazole for 4 weeks due to suspicion of deep fungal infection without any success. Although the histopathology findings and culture of a biopsy specimen were negative, our suspicion was aroused by his work with tropical fish in an aquarium. We repeated skin biopsies and, after the third examination, the biopsy sent for culture grew *M. marinum*, confirming the diagnosis of fish-tank granuloma. The patient started treatment with rifampicin at a dose of 750 mg daily in combination with clarithromycin at a dose of 1,000 mg once daily, and after 6 months pronounced regression of the lesions was observed. Follow-up after 12 months was negative.



**Figure 2** | The histopathology showed pseudoepitheliomatous hyperplasia with nonspecific mixed inflammatory infiltrate with intraepidermal abscess.

## Discussion

*M. marinum* infections are uncommon, and estimates of the annual incidence vary from 0.04 per 100,000 in France to 0.27 cases per 100,000 in the United States (7, 8). In the past, outbreaks have been reported among individuals frequenting swimming pools, but, after proper chlorination of this reservoir, the main source of infection has been fish tanks; outbreaks have also been described in fish farms (9). Keeping and cleaning out tanks with infected fish or contaminated water are the main predisposing factors today. In a French study, 84% of cases of *M. marinum* disease were linked to fish tank exposure, and in the majority of cases the infection was located on the hands (5). The incubation period ranges from 5 days to 9 months, but it is usually 2 to 3 weeks (10). Because the optimal temperature for growth of *M. marinum* is 30 to 32 °C, the infection is limited to the skin; less commonly, the infection spreads to deeper structures, such as the joints, tendons, and bones (11–13). Immunocompromised patients may develop disseminated lesions, and a more aggressive course may occur in

transplant recipients and subjects on corticosteroid or biologic therapy (14–18).

The clinical presentations are polymorphous. Skin lesions are most commonly asymptomatic, and some patients occasionally present with pain, pruritus, tenderness, or paresthesia (19). The most common presentation in an immunocompetent patient, as described in about 60% of the cases, is a single granulomatous papule or nodule on a finger or hand, which may ulcerate and discharge a suppurative mass (5). Sporotrichoid dissemination is possible and has been reported in 25% of cases of *M. marinum* infection (20, 21). Less often, skin lesions may present as verrucous plaques, erythematous plaques with scaling, or eczema-like lesions without a significant inflammatory component and infiltration or interstitial granuloma annulare (3, 22, 23). Unusual clinical presentations have also been reported, such as destructive nasal lesions mimicking extranodal natural killer (NK)/T-cell lymphoma (24).

The most common site of infection in a patient with aquarium exposure are the upper extremities, such as a hand or fingers (25). A history of preceding minor trauma is common; however, because the incubation period can be very long, many patients cannot recall skin trauma. Establishing a diagnosis of *M. marinum* infection can be a great challenge, probably due to the rarity and lack of awareness of this infection. If the key medical history of aquatic exposure is not obtained, the diagnosis is frequently delayed (22). The average time from clinical presentation to correct diagnosis varies from 1 to 27 months with a mean interval of 7 months (26). Diagnosis is eventually made through histopathologic examination and the culture of a biopsy sample. Histopathologic findings are important for diagnosis, but they depend on the duration of the lesion. During the first 6 months, a non-specific inflammatory infiltrate may be observed, but acid-fast stains occasionally reveal bacilli. After such a period, lesions show tuberculoid granulomas with fibrinoid masses rather than caseation. The epidermis frequently shows hyperkeratosis, acanthosis, pseudoepitheliomatous hyperplasia, intraepidermal neutrophilic abscesses, and ulceration. Dermal fibrosis and small blood vessel proliferation can be observed (26). The diagnosis must be confirmed by culture on Löwenstein–Jensen medium at 28 to 32 °C. According to the literature data, the positivity rate of cultures ranges from 70 to 80% (5); in the series of 15 cases described by some authors, *M. marinum* was isolated in 13 out of 15 patients (93.3%) (5, 28). The PCR amplification technique is a fast, sensitive, and specific diagnostic tool for diagnosing *M. marinum* infection directly in the biopsy sample. However, it should be interpreted with caution because false-positive results are possible (29, 30).

There is no absolute consensus on the treatment of infections with *M. marinum*, and so therapeutic decisions should be based on reported outcomes in case reports and case series or susceptibility testing (6, 31, 32). In localized and uncomplicated skin infection, monotherapy with various antibiotics is recommended. *M. marinum* is susceptible to clarithromycin, trimethoprim/sulfamethoxazole, sulphonamides, rifampin, rifabutin, and ethambutol, and variably susceptible to doxycycline, minocycline, and streptomycin (26, 33, 34). Clarithromycin seems to be superior to other drugs in terms of drug susceptibility testing and due to fewer side effects (33). Combination therapy, often with clarithromycin plus rifampin and/or ethambutol, is preferred in cases of extensive infection or deep tissue involvement (16). Antibiotic susceptibility testing is routinely not recommended except in cases of treatment failure or relapse (31, 35). According to the literature,

the mean duration of the treatment is 4 months (2, 16). Treatment should be continued for 1 to 2 months after the resolution of symptoms (16, 20). In the case of mild disease, the infection can resolve spontaneously in several months to years (34). Small lesions may be treated with cryotherapy, curettage, or excision (35).

In the case presented, the diagnosis was confirmed 3 months after the first visit to our department, and appropriate treatment was introduced 15 months after the initial lesions appeared. Despite the unusual clinical presentation, a high index of suspicion for fish tank granuloma at the patient's initial visit was present, mainly because of his medical history. The low positivity rate of cultures, which ranges from 70 to 80%, can often result in false negative results (5). Negative results of initial cultures can be explained by inadequate biopsy samples or technical problems with transporting and processing the specimen. Cultivation requires low temperatures for growth and also takes several weeks to become positive. Although the initial results of laboratory and histopathological examinations were negative for a fungal infection or nontuberculous mycobacteria, the patient was treated empirically with clindamycin for 4 weeks and then with doxycycline. Because of no response to therapy after 4 weeks of treatment, an

alternative diagnosis was considered, and treatment with itraconazole was introduced. After 4 weeks, no response was observed, but finally the culture of the biopsy sample confirmed infection with *M. marinum*. The patient received a course of clarithromycin and rifampin, and complete resolution was observed after 6 months of therapy.

## Conclusions

Infection with *M. marinum* is rare and has no pathognomonic clinical presentation. A high level of awareness and accurate medical history are the key factors for establishing a diagnosis, which must be confirmed by histopathologic examination and bacteriologic studies of tissue cultures. Histopathologic appearances are variable and often nonspecific during the first months of infection, and even microbiological tests sometimes do not confirm the infection. We suggest that in all patients with atypical skin lesions and a history of repeated contact with fish tanks, even in the case of negative microbiological results, empirical treatment for *M. marinum* be introduced as soon as possible to avoid progression to deep infections.

## References

- Norden A, Linnell F. A new type of pathogenic mycobacterium. *Nature*. 1951;168:826.
- Castillo NE, Gurram P, Sohail MR, Fida M, Abu Saleh O. Fishing for a diagnosis, the impact of delayed diagnosis on the course of *Mycobacterium marinum* infection: 21 years of experience at a tertiary care hospital. *Open Forum Infect Dis*. 2020;7:ofz550.
- Veraldi S, Molle M, Nazzaro G. Eczema-like fish tank granuloma: a new clinical presentation of *Mycobacterium marinum* infection. *J Eur Acad Dermatol Venereol*. 2018;32:200-1.
- Ang P, Rattana-Apiromyakit N, Goh CL. Retrospective study of *Mycobacterium marinum* skin infections. *Int J Dermatol*. 2000;39:343-7.
- Gluckman SJ. *Mycobacterium marinum*. *Clin Dermatol*. 1995;13:273-6.
- Aubry A, Chosidow O, Caumes E, Robert J, Cambau E. Sixty-three cases of *Mycobacterium marinum* infection: clinical features, treatment, and antibiotic susceptibility of causative isolates. *Arch Intern Med*. 2002;162:1746-52.
- Wentworth AB, Drage LA, Wengenack NL, Wilson JW, Lohse CM. Increased incidence of cutaneous nontuberculous mycobacterial infection, 1980 to 2009: a population-based study. *Mayo Clin Proc*. 2013;88:38-45.
- Waddington E. An outbreak of swimming pool granuloma. *Trans St John's Hosp Dermatol Soc*. 1967;53:122-4.
- Feng Y, Xu H, Wang H, Zhang C, Zong W, Wu Q. Outbreak of a cutaneous *Mycobacterium marinum* infection in Jiangsu Haian, China. *Diagn Microbiol Infect Dis*. 2007;71:267-72.
- Jernigan JA, Farr BM. Incubation period and sources of exposure for cutaneous *Mycobacterium marinum* infection: case report and review of the literature. *Clin Infect Dis*. 2000;31:439-43.
- Barton A, Bernstein RM, Struthers JK, O'Neill TW. *Mycobacterium marinum* infection causing septic arthritis and osteomyelitis. *Br J Rheumatol*. 1997;36:1207-9.
- Powers R, Fisher M. Tenosynovitis due to *Mycobacterium marinum*. *N Engl J Med*. 2004;351:911.
- Saadatmand B, Poulton JK, Kauffman CL. *Mycobacterium marinum* with associated bursitis. *J Cutan Med Surg*. 1999;3:218-20.
- Pandian TK, Deziel PJ, Otley CC, Eid AJ, Razonable RR. *Mycobacterium marinum* infections in transplant recipients: case report and review of the literature. *Transpl Infect Dis*. 2008;10:358-63.
- Lacaille F, Blanche S, Bodemer C, Durand C, De Prost Y, Gaillard JL. Persistent *Mycobacterium marinum* infection in a child with probable visceral involvement. *Pediatr Infect Dis J*. 1990;9:58-60.
- Streit M, Böhlen LM, Hunziker T, Zimmerli S, Tschärner GG, Nievergelt H, et al. Disseminated *Mycobacterium marinum* infection with extensive cutaneous eruption and bacteremia in an immunocompromised patient. *Eur J Dermatol*. 2006;16:79-83.
- Tchornobay AM, Claudy AL, Perrot JL, Lévine V, Denis M. Fatal disseminated *Mycobacterium marinum* infection. *Int J Dermatol*. 1992;31:286-7.
- Zimmerlich S, Eder IB, Simon JC, Kunz M. *Mycobacterium marinum* infection in an immunocompromised patient with infliximab. *Eur J Dermatol*. 2020;30:436-7.
- Sander M, Isaac-Renton JL, Sander MA. Atypical clinical and laboratory features of fish-tank granuloma: a case report. *SAGE Open Med Case Rep*. 2018;6:2050313X18804071.
- Petrini B. *Mycobacterium marinum*: ubiquitous agent of waterborne granulomatous skin infections. *Eur J Clin Microbiol Infect Dis*. 2006;25:609-13.
- Belič M, Miljković J, Marko PB. Sporotrichoid presentation of *Mycobacterium marinum* infection of the upper extremity. A case report. *Acta Dermatovenerol Alp Pannonica Adriat*. 2006;15:135-9.
- Dolenc-Voljč M, Žolnir-Dovč M. Delayed diagnosis of *Mycobacterium marinum* infection: a case report and review of the literature. *Acta Dermatovenerol Alp Pannonica Adriat*. 2010;19:35-9.
- Barr KL, Lowe L, Su LD. *Mycobacterium marinum* infection simulating interstitial granuloma annulare: a report of two cases. *Am J Dermatopathol*. 2003;25:148-51.
- Asakura T, Ishii M, Kikuchi T, Kameyama K, Namkoong H, Nakata N, et al. Disseminated *Mycobacterium marinum* infection with a destructive nasal lesion mimicking extranodal NK/T cell lymphoma: a case report. *Medicine (Baltimore)*. 2016;95:e3131.
- Sia TY, Taimur S, Blau DM, Lambe J, Ackelsberg J, Yacisin K, et al. Clinical and pathological evaluation of *Mycobacterium marinum* group skin infections associated with fish markets in New York City. *Clin Infect Dis*. 2016;62:590-5.
- Dodiuk-Gad R, Dyachenko P, Ziv M, Shani-Adir A, Oren Y, Mendelovici S, et al. Nontuberculous mycobacterial infections of the skin: a retrospective study of 25 cases. *J Am Acad Dermatol*. 2007;57:413-20.
- Abbas O, Marrouch N, Kattar MM, Zeynoun S, Kibbi AG, Rached RA, et al. Cutaneous non-tuberculous mycobacterial infections: a clinical and histopathological study of 17 cases from Lebanon. *J Eur Acad Dermatol Venereol*. 2011;25:33-42.
- Bonamonte D, De Vito D, Vestita M, Del Vecchio S, Ranieri LD, Santantonio M, et al. Aquarium-borne *Mycobacterium marinum* skin infection. Report of 15 cases and review of the literature. *Eur J Dermatol*. 2013;23:510-6.
- Posteraro B, Sanguinetti M, Garcovich A, Ardito F, Zampetti A, Masucci L, et al. Polymerase chain reaction-reverse cross blot hybridization assay in the diagnosis of sporotrichoid *Mycobacterium marinum* infection. *Br J Dermatol*. 1998;139:872-6.
- Harris DM, Keating RK. *Mycobacterium marinum*: current recommended pharmacological treatment. *J Hand Surg*. 2009;34:1734-5.
- Esteban J, Ortiz-Perez A. Current treatment of atypical mycobacteriosis. *Expert Opin Pharmacother*. 2009;10:2787-99.
- Rhomberg PR, Jones RN. *In vitro* activity of 11 antimicrobial agents, including gatifloxacin and GAR936, tested against clinical isolates of *Mycobacterium marinum*. *Diagn Microbiol Infect Dis*. 2002;42:145-7.
- Aubry A, Mougari F, Reibel F, Cambau E. *Mycobacterium marinum*. *Microbiol Spectr*. 2017;5.
- Edelstein H. *Mycobacterium marinum* skin infections: report of 31 cases and review of the literature. *Arch Intern Med*. 1994;154:1359-64.
- Rallis E, Kumanantaki-Mathioudaki E. Treatment of *Mycobacterium marinum* cutaneous infections. *Exp Opin Pharmacotherapy*. 2007;8:2965-78.