

Ekspanzivni procesi v mali medenici, prikriti s sočasno lumbalno kompresijo, kot vzrok lumboishialgije - prikaz treh primerov

Pelvic expansion hidden by concomitant lumbar compression as a cause of sciatica - report of three cases

Avtor / Author

Ustanova / Institute

Gorazd Bunc^{1,2}, Janez Ravnik¹, Matjaž Voršič^{1,2}

¹Univerzitetni klinični center Maribor, Oddelek za nevrokirurgijo, Maribor, Slovenija;

²Univerza v Mariboru, Medicinska fakulteta, Maribor, Slovenija

¹University Clinical Centre Maribor, Neurosurgical Department, Maribor, Slovenia;

²University of Maribor, Faculty of Medicine, Maribor, Slovenia

Ključne besede:

Znotraj-hrbtenična utesnitev živčnih korenin, zunaj-hrbtenična utesnitev živčnih korenin, ledvena radikulopatija, ishiadini živec, maligni tumorji živčnih ovojníc.

Key words:

Intraspinal nerve root compression, extraspinal nerve root compression, lumbar radiculopathy, sciatic nerve, malignant nerve sheath tumors genetic markers.

Članek prispel / Received

10.03.2010

Članek sprejet / Accepted

25.01.2010

Naslov za dopisovanje /

Correspondence

Gorazd BUNC, dr. med.

Univerzitetni klinični center Maribor,
Oddelek za nevrokirurgijo,
Ljubljanska 5, SI-2000 Maribor,
Slovenija

Telefon +386 23211457

Faks +386 23324830

E-pošta: gorazd.bunc@ukc-mb.si

Izvleček

Namen: V članku so predstavljeni primeri treh bolnikov z ishialgično bolečino, povzročeno zaradi sočasne intra- in ekstraspijalne kompresije ishialdičnega živca.

Poročilo o primeru: Diagnostični postopki so sprva razkrili le intraspinalni razlog za bolečino. Vsi trije bolniki so bili operirani, vendar kliničnega izboljšanja po operaciji ni bilo. Dodatni diagnostični postopki, pri enem od bolnikov pa obdukcija, so kot razlog za vztrajajočo bolečino pri dveh bolnikih razkrili tumor živčnih ovojnic, pri tretjem bolniku pa medenični absces s kompresijo lumbosakralnega pleksusa.

Zaključek: O ekstraspijalni kompresiji ishialdičnega živca je potrebno razmisliti predvsem v primerih, ko standardni kirurški poseg z odstranitvijo intraspinalnega vzroka ne privede do ustreznega kliničnega izboljšanja.

Abstract

Purpose: Three patients with sciatica caused by contemporary involvement of intra- and extraspinal compression of the sciatic nerve are presented.

Case report: The diagnostic workup initially revealed intraspinal compression as the cause of sciatica. All patients underwent surgery that did not lead to clinical improvement. Additional diagnosis in two patients and autopsy in one revealed that residual pain was caused by nerve sheath tumors in two cases and pelvic abscess compression of the lumbosacral plexus in the third case.

Conclusion: Extraspinal compression of the sciatic nerve should be considered where standard surgical decompression of the intraspinal cause of sciatica fails to improve the clinical picture.

INTRODUCTION

The most common cause of lumbar radiculopathy is mechanical compression from a herniated lumbar disc or osseous stenosis. A typical feature of sciatica is pain that radiates down the posterior side of the thigh and calf to the foot and is usually associated with paresthesia, motor weakness and sensory dermatomic changes. Extraspinal compression of the sciatic nerve is very rare and is difficult to assess with normal diagnostic procedures (1,2). It can happen anywhere along the nerve but is most often found in the pelvis (1-3). The main complaints of such patients are very similar to the most usual causes of sciatica. There are many causes of extraspinal compression described in the literature, including hematoma and various soft-tissue or osseous tumors.

Three cases of lumbar radiculopathy caused by contemporary involvement of intra- and extraspinal compression of the sciatic nerve are presented. After decompression surgery for lumbar spinal stenosis and herniated disc failed to relieve the radicular pain, additional diagnosis in two patients and autopsy in one revealed that radicular pain was caused by nerve sheath tumors in two cases and pelvic abscess in the third. The difficulty of diagnosing radiculopathy that remains after unsuccessful lumbar surgery is emphasized.

Case reports

Case I

A 53-year old male patient was admitted to our department because of left-sided sciatica, which lasted for several months and persisted after conservative treatment. Neurological examination revealed the distribution of pain and sensory changes over the dermatome S1 on the left side, without clear motor weakness. Lumbar myelography and CT were performed, which revealed osseous stenosis of the left lateral recessus at the L5-S1 level, as a result of arthrosis of the facet joints and dorsal osteophytes (Figure 1). Fenestration at the L5-S1 level on the left side was performed, and the involved nerve was decompressed. After surgery, the patient reported al-

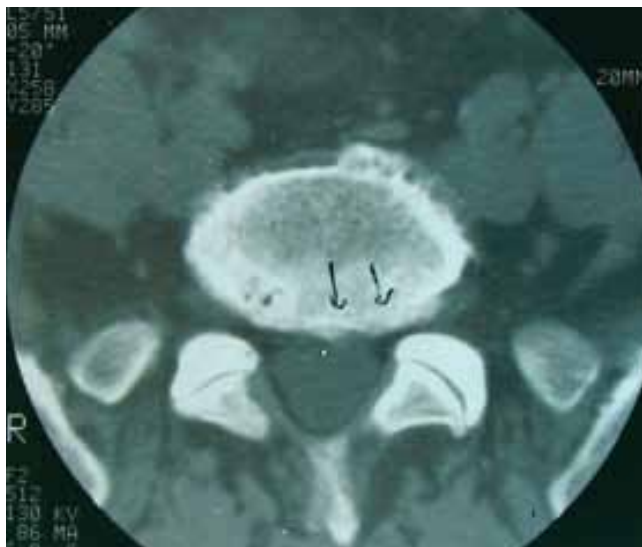

Figure 1. Preoperative CT revealed osseous stenosis of the left lateral recessus at the level L5-S1 caused by arthrosis of the facet joints and dorsal osteophytes.

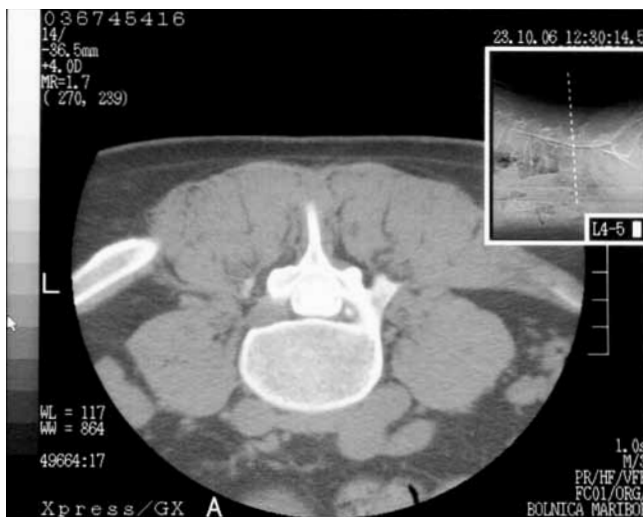


Figure 2. CT myelography revealed a minor left-sided lateral herniated disc at the level L4-L5.

most complete relief from pain in the proximal part of the left leg; however, the distal pain in the left calf and left foot remained the same. Over the following days, the pain increased. On the sixth postoperative day, the patient suddenly became unconscious, with elevated blood pressure and tachycardia, followed by cessation of breathing. Immediate resuscitation began but was unfortunately not successful, and the patient died. The autopsy revealed a massive pulmonary embolism and a completely thrombosed

femoral vein on the left side. A tumor of 10 x 8 cm was found in the left side of the pelvis, which was compressing the sciatic nerve. Histology later showed the tumor to be a malignant schwannoma malignant nerve sheath tumor.

Case 2

A 33-year old male patient was admitted to our department because of left-sided sciatica, which had lasted for 2 months. Ten days before admission, the patient experienced left foot drop. Neurological examination revealed the distribution of pain and sensory changes over the dermatome L5 on the left side, together with clear motor weakness including dorsal flexion, and plantar flexion was normal. The patient had trouble urinating and emptying the bladder, with a large residual volume. Lumbar myelography and CT were performed, which revealed a minor left-sided, lateral herniated disc at the L4-L5 level (Figure 2). Microdiscectomy at the L4-L5 level on the left side was performed, and the herniated disc was removed but proved not to be the cause of major nerve compression. After surgery, the pain in the left leg diminished slightly, although the motor weakness persisted. Additional diagnostic workup (abdominal ultrasound, CT and MRI) was performed. A large tumor (12cm in diameter) was found in the presacral

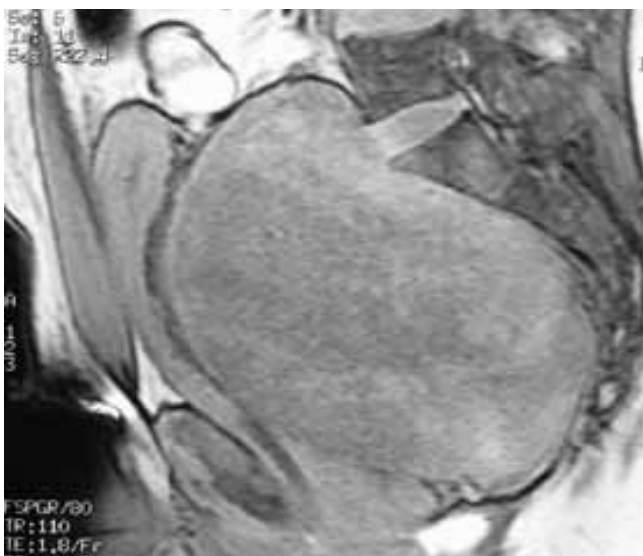

Figure 3. Abdominal T1-weighted MRI with gadolinium revealed large, presacral tumorous mass.

region behind the urinary bladder, which destroyed the sacrum and compressed the sacral nerve plexuses (Figure 3).

A second, abdominal operation was performed. The tumor was removed through a median laparotomy, and histology revealed that it was a malignant schwannoma. Following the surgical procedures, the patient also underwent oncological treatment. The neurological status remained the same: the left-sided foot paresis persisted, but the pain subsided significantly.

Case 3

An 80-year old woman in good physical condition presented with severe, sharp pain that radiated down the left lower extremity, and numbness in both lower extremities from the knees down to the lateral aspect of both feet. Paresis of the left foot and urinary retention ensued. Neurological examination revealed weakened knee extension and dorsal foot flexion on the left side, and knee jerk was reduced on the left. There was also decreased sensation over the L4 to S1 dermatomes on the left side. The patient had urinary retention, and a urinary catheter was inserted. My-

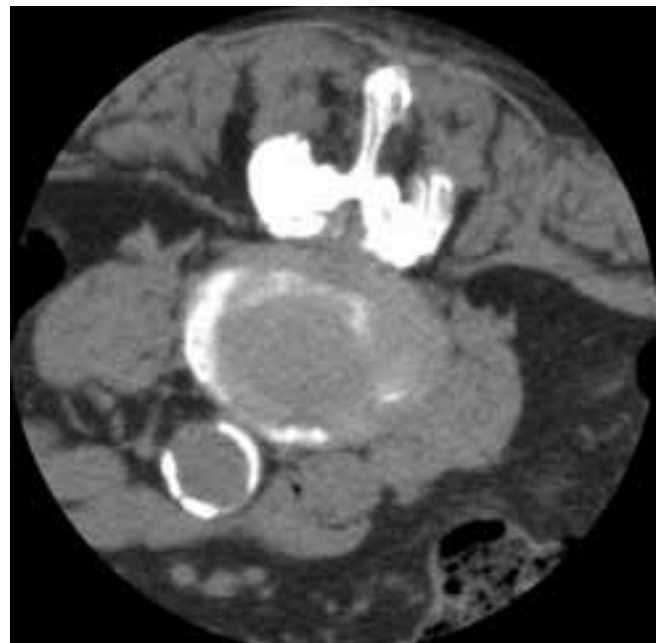

Figure 4. Preoperative CT revealed severe osseous stenosis at the level L3-L4.

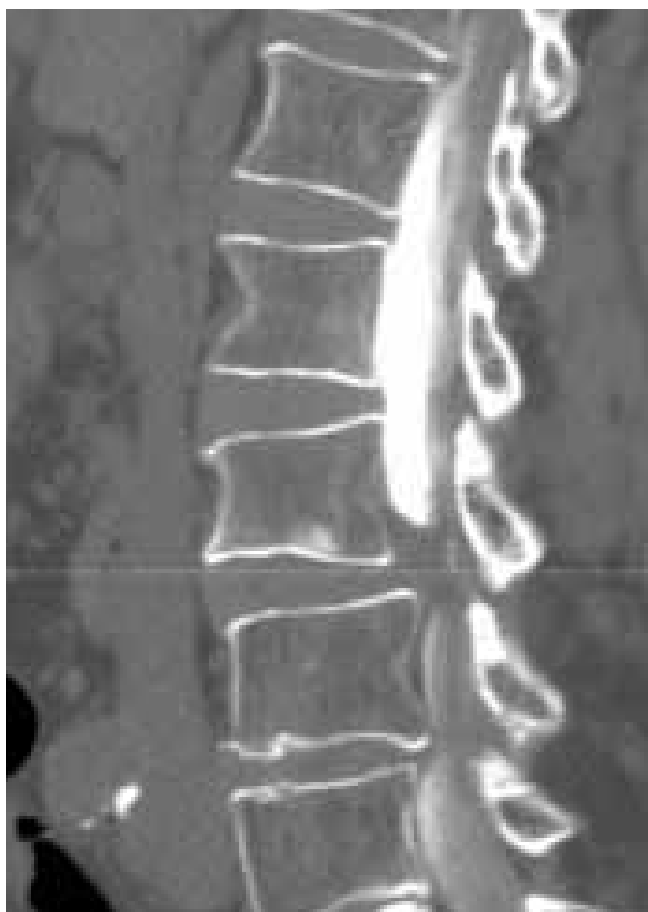

Figure 5. Myelogram (lateral view) demonstrated partial block at the level L3-L4.

elography and CT were performed, which revealed severe spinal stenosis with a partial block at the L3-L4 and L4-L5 level (Figures 4 and 5). Decompressive laminectomy and discectomy were performed at the L3-L4 level. The pain improved slightly, but the neurological deficit remained the same, and the patient became subfebrile with a slight increase in CRP. CT of the abdominal cavity revealed encapsulated fluid that had collected in the pouch of Douglas (Figure 6), which also involved the sacral plexus, which was the cause of the pain and neurological dysfunction. A puncture of the pouch of Douglas was performed, revealing pus, which was evacuated. Appropriate antibiotic treatment was introduced. After 2 weeks, the patient improved, and upon discharge did not complain of pain in the left leg; the dorsal flexion of the left foot improved, although the urinary retention persisted.

DISCUSSION

Lumbar radiculopathy is a common symptom caused by mechanical compression of the lumbar nerve roots that form the sciatic nerve, which is usually from a herniated lumbar disc or osseous stenosis. Extradiscal entrapment of the sciatic nerve

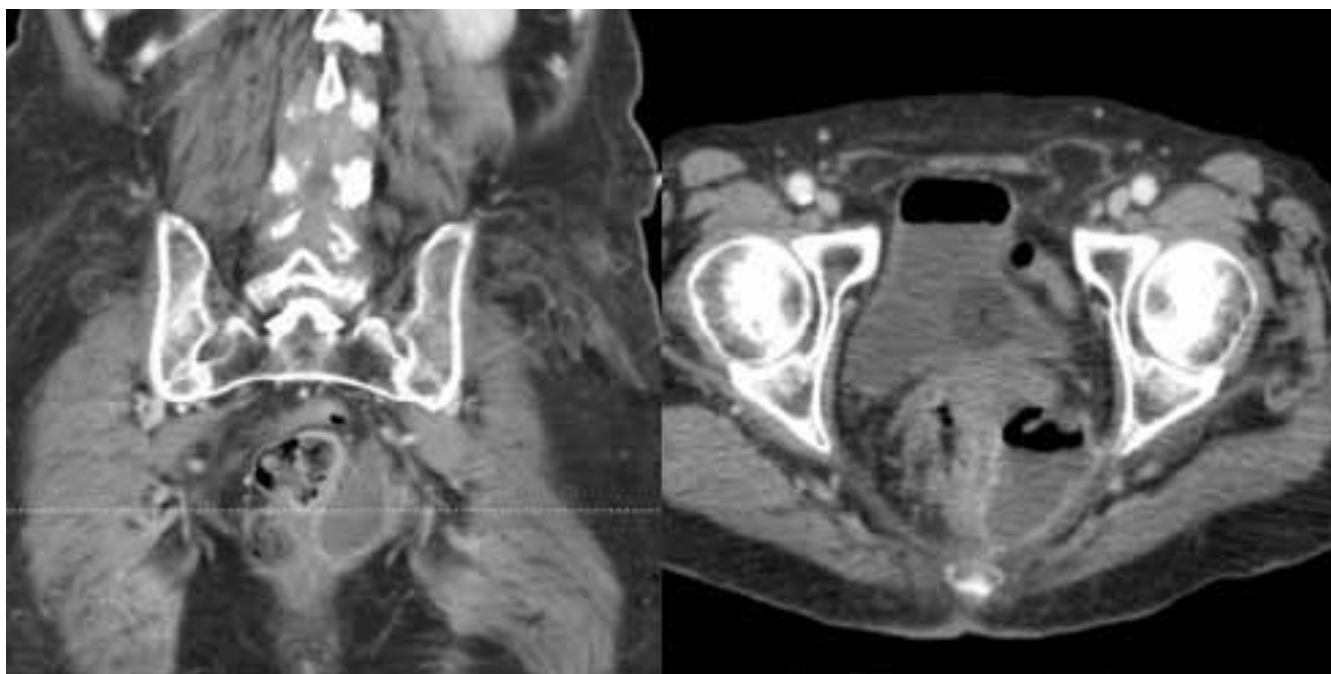


Figure 6. Frontal and axial CT revealed an encapsulated fluid collection in the pouch of Douglas.

is a rare cause of sciatica and difficult to diagnose (1,2). Usually bone and soft tissue tumors along the nerve course (3-8) are the main cause of such pain, but a variety of causes, such as hematoma (8), piriformis muscle syndrome (1), gluteal artery pseudoaneurysm (9), inferior vena cava syndrome (10), traumatic venous varix (11), and gastrocnemius muscle herniation (12), can be found. Clinically, it is usually difficult to distinguish between true, intraspinal radicular lumbar pain and extraspinal compression pain. The situation can be especially misleading in the case of contemporary double compression, because the symptoms are similar in both, which makes these patients difficult to diagnose and treat. The pain pattern is the key to early diagnosis (3), and patients who experience insidious onset of pain that is progressive and unresponsive to position should be given special attention. Early diagnosis of extraspinal compression as a cause of sciatica is the key to proper, effective treatment of such patients.

In our first case, the clinical picture revealed severe sciatic pain caused by osseous stenosis of the lateral recessus at the L5-S1 level on the left side. After surgery, the patient improved, and the proximal pain in the left lower extremity vanished, but the distal pain remained the same. Autopsy revealed a large nerve sheath tumor, found in the left side of the pelvis, as the cause of the extraspinal compression of the sciatic nerve.

The second case involved a patient with left - sided sciatica that improved after excision of a lateral herniated disc at the L4-L5 level; weakness of the dorsal flexion of the left foot remained, however, and urinary problems ensued. Additional diagnostic workup revealed a large pelvic tumor malignant schwannoma, that directly compressed the sciatic nerve during its pelvic course, and compressed the urinary bladder. Removal of the tumor did not lead to neurological improvement, and the prognosis of the patient remained poor because of the malignancy of the tumor.

The third case was a patient with left - sided sciatica and severe degenerative changes at the L3-L5 levels. Decompressive laminectomy was performed, but the clinical picture remained the same after two surgical procedures, and the patient presented with left-side sciatica, weakened dorsal foot flexion, and urinary retention. Later, abdominal CT revealed a pus collection in the pouch of Douglas, which was evacuated. The clinical picture improved.

The intention of our presentation was to stress the importance of additional diagnostic workup in cases in which, although the proper intraspinal surgical procedure was performed in response to sciatic pain, there was no improvement in the clinical picture. One must always consider the pathology and the cause of pain along the extraspinal course of the sciatic nerve.

REFERENCES

1. Filler GA, Haynes J, Jordan SE. Sciatica of non-disc origin and piriformis syndrome: diagnosis by magnetic resonance neurography and interventional magnetic resonance imaging with outcome study of resulting treatment. *J Neurosurg Spine* 2005; 2: 99-115.
2. Lamki N, Hutton L, Wall WJ, Rorabeck CH. Computed tomography in pelvic liposarcoma: A case report. *J Comput Tomogr* 1984; 8: 249-51.
3. Bickels J, Kahanovitz N, Rubert CK. Extraspinal bone and soft-tissue tumors as a cause of sciatica. Clinical diagnosis and recommendations: analysis of 32 cases. *Spine* 1999; 15: 1611-6.
4. Benyahya E, Etaouil N, Janani S. Sciatica as the first manifestation of leiomyosarcoma of the buttock. *Rev Rheum* 1997; 64: 135-7.
5. Harrison MJ, Leis HT, Johnson BA, MacDonald WD, Goldman CD. Hemangiopericytoma of the sciatic notch presenting as sciatica in a young healthy man: Case report. *Neurosurgery* 1995; 37: 1208-11.
6. Odell RT, Key JA. Lumbar disc syndrome caused by malignant tumors of bone. *JAMA* 1955; 157: 213-6.
7. Dudeney S, O'Farrell D, Bouchier-Hayes D, Byrne J. Extraspinal causes of sciatica: a case report. *Spine* 1998; 23: 494-6.
8. Soggard I. Sciatic nerve entrapment: Case report. *J Neurosurg* 1983; 58: 275-6.
9. Yurtseven T, Zileli M, Göker EN, Tavmergen E, Hoscoskun C, Parildar M. Gluteal artery pseudoaneurysm, a rare cause of sciatic pain. Case report and literature review. *J Spinal Disord Tech* 2002; 15: 330-3.
10. Paksoy Y, Gormus N. Epidural venous plexus enlargements presenting with radiculopathy and back pain in patients with inferior vena cava obstruction or occlusion. *Spine* 2004; 29: 2419-24.
11. Maniker AH, Thurmond J, Padberg FT, Blacksin M, Vingan R. Traumatic venous varix causing sciatic neuropathy: case report. *Neurosurgery* 2004; 55: 1224.
12. Alhadeff J, Lee CK. Gastrocnemius muscle herniation at the knee causing peroneal nerve compression resembling sciatica. *Spine* 1994; 20: 612-4.