

Real time compound ultrasound of the shoulder

Alessandro De Candia¹, Stefano Doratiotto¹, Francesco Pelizzo¹,
Elio Paschina², Massimo Bazzocchi¹

¹Department of Radiology,

²Department of Orthopedic Surgery, University Hospital of Udine, Udine, Italy

Background. The purpose of the study was to determinate the value of the ultrasound real time compound imaging in the evaluation of supraspinatus tendon in subacromial impingement disease.

Patients and methods. Preoperative ultrasound was performed on 180 shoulders in 157 patients with clinical suspicion of rotator cuff disease; 71 patients were surgically treated with acromioplasty and cuff repair. The sonograms were obtained under static and dynamic examination using a 5-12 MHz high frequency linear array probe, and compound real time elaboration of multiple images from different viewing angles (Sono CT[®] - ATL). The supraspinatus morphology was classified into the following groups: the absence of tears, the presence of partial thickness tears and the presence of full thickness tears. In the absence of tears, the supraspinatus tendinopathy was classified into three classes according to the Neer stages. The ultrasound findings were compared to the surgical inspection results.

Results. Ultrasound showed 32 (96.9%) out of 33 full thickness tears, only one false negative in a patient with large body, and 9 (75%) out of 12 partial thickness tears. There were three false negative studies in supraspinatus tendons with superficial lesions. Ultrasound correctly showed 26 (100%) out of 26 rotator cuffs with the absence of tear.

Conclusions. Real time compound ultrasound is a useful tool in the evaluation of the supraspinatus tendon diseases; this technique permits the reduction of the presence of conventional ultrasound acoustic artefacts and provides necessary information for preoperative planning.

Key words: shoulder joint - ultrasonography; rotator cuff; shoulder impingement syndrome - ultrasonography; real time compound ultrasound; sono CT

Introduction

Rotator cuff tears are usually described as common pathologic conditions we can meet while performing the ultrasonographic imaging of the shoulder.¹ Technical development in the last few years allowed ultrasonography to be considered one of the best imaging methods for studying those conditions. The newest full-digital equipments in fact allow to

Received 7 June 2002

Accepted 17 June 2002

Correspondence to: Alessandro De Candia, MD, Department of Radiology, University Hospital of Udine, APUGD Via Colugna 50, 33100 Udine, Italy; Phone: +39 43 25 59 266; Fax: +39 43 25 59 867; E-mail: alessandro.decandia@med.uniud.it

obtain a high quality of the ultrasonographic images as never before. High-resolution digital ultrasonography allows increasing the sensitivity, the specificity and the overall diagnostic accuracy in the shoulder lesions characterisation if compared to the conventional ultrasonographic methods.²⁻⁶

The aim of this paper is to describe the features of real time compound ultrasound technique and to introduce its potential benefits on the supraspinatus tendon study comparing sonographic images to surgical results.

Patients and methods

Between January 2000 and December 2000, we performed a prospective study on 180 shoulders in 157 patients (69 males and 88 females aged between 17 and 82 years; mean age of males 49.7 years; mean age of females 58.2 years) with clinical suspicion of rotator cuff tear.

Out of 157 patients 71, aged between 34 and 80 years (31 males, mean age 51.2 years; 40 females, mean age 55 years) underwent surgery on the day after sonography. Surgical intervention on the supraspinatus tendon with tear repair and acromioplasty was performed on all the 71 patients by the same operator who recorded the data using a standard method. The study was performed in a clinical setting with the approval of the Ethics Committee of our Institute.

Sonograms were obtained with an ATL 5000 scanner, using a 7 to 12 MHz linear array probe (Advanced Technology Laboratories, Bothell, WA) applying the soon CT digital algorithm.

This algorithm allows the digital real time image capturing along nine different lines of view at the same time for every point on the patient's shoulder on which the operator places the transducer. The nine virtual images that the transducer receives back at once from the patient are weighted in real time by

a digital beamformer unit and melted into one final image which is the result of the nine different frames compound processing.^{7,8}

In all patients, both the static and the dynamic evaluations were performed.

The static examination was performed on the patient's arm in standard position of the shoulder joint to evaluate the supraspinatus tendon as it is described in the first part of the dynamic evaluation. Dynamic images were obtained by moving passively the patients arm in intrarotated position first and then in extended position: during the first part of the dynamic evaluation, the patient's arm was placed in the abducted and intrarotated position, with the forearm flexed to the arm, and the back face of the fingertips pointing to the tip of the scapula. The second part of the dynamic evaluation was performed by moving the limb passively in adduction\extension but keeping the intrarotation of the forearm during the movement.^{9,10} All the images of the 71 patients were stored digitally on the US unit.

Two radiologists performed separately the image evaluation. Both the observers evaluated each image set for the presence or absence of tendon tear and for the characterisation of the supraspinatus tendon features in the absence of sonographic proof of the tear.

The patients in whom ultrasonography revealed the presence of tendon tear were divided into two groups: the first group comprised the patients with complete rupture of the supraspinatus tendon, while the second group included the patients with partial rupture of the supraspinatus tendon.

In the absence of sonographic appearance of any type of tendon tear, the lesion grade based on the sonographic appearance of the tendon was established. We described tendons by grouping them into three sonographically determined classes. The first class included the tendons which appeared to be thickened with a hyperechogenic surface, but showing a normal fibrillar central region. The

subacromial bursa was thickened but without intratendinous calcifications. The second class grouped the tendons that showed to be thickened and had an irregular and inhomogeneous aspect of their central fibrillar region. This class included the shoulders with the thickened subacromial bursa and intratendinous calcifications. The third class comprised the patients in whom the supraspinatus tendon appeared diffusely hypoechoic, inhomogeneous and thinner. In this class, intratendinous calcifications were also present.

The ultrasonographic findings were compared to surgery outcome, the latter being considered as the gold standard technique in characterising the presence or absence of tear.

Results

Considering the 71 patients who underwent surgery, the real time compound imaging cor-

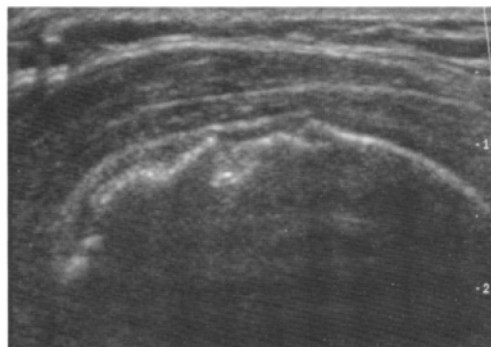


Figure 1. Transverse image of the supraspinatus tendon. Real time compound imaging shows a full thickness tear of the supraspinatus tendon with the deltoid muscle laying on the humeral head. Note the severe humeral head arthrotic degeneration.

rectly identified and characterized 32 (96.9%) out of 33 surgically confirmed full thickness tears of the supraspinatus tendon (Figures 1, 2). The study of the rotator cuff performed on one obese patient was not able to lead to the final right diagnosis (false negative). There was not any false positive study. The real

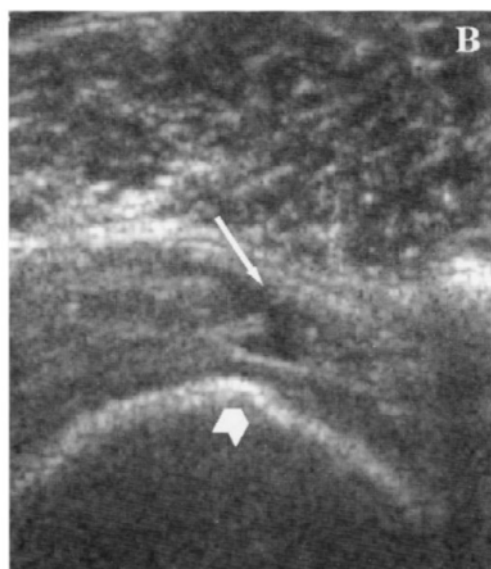
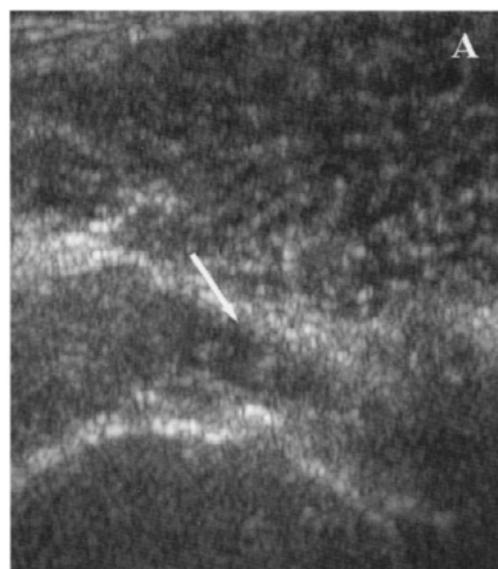


Figure 2. Transverse images of the supraspinatus tendon. A) Conventional ultrasound shows a small full thickness tear on the front side edge of the tendon (arrow); B) Real Time Compound Imaging shows a remarkable increase in lesion conspicuousness and the broken tendon fibres as well (arrow). The cartilage surface is better displayed (arrowhead).

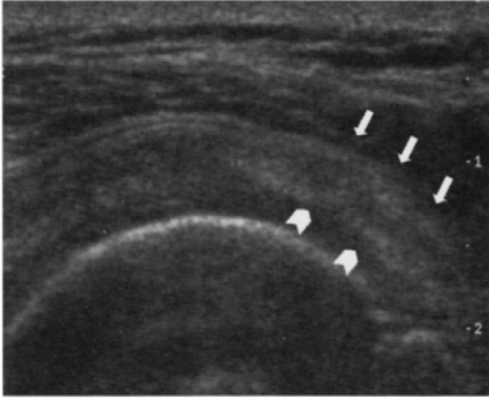


Figure 3. Transverse image of the supraspinatus tendon. Real Time Sono CT imaging is better showing the tendon structure focusing on the hypoechogenic area of tendon suffering on the front side of the tendon (arrows) mixed to the superficial area of abrasive injury (arrowheads).

time compound imaging identified correctly 9 of 12 (75%) partial thickness tears diagnosed by surgery. There were 3 false negative studies (superficial partial thickness tears of the supraspinatus tendon on surgery). There were no false positive studies. The absence of tear was detected in 26 patients by ultrasonography (Figure 3). All these cases were confirmed by surgery as tearless tendons.

In 5 (29%) out of 26 patients, a first-class ultrasonographic aspect of the tearless tendon were described (3 women, two of them aged 39 and the third 79 years old; 2 men aged 41 and 51 years). Surgery on these 5 patients described one case as degeneration of the supraspinatus tendon with no tear, one case as abrasive lesion of the tendon due to impingement syndrome disease with no tear, and three cases without any lesion either in

the tendon or in the bursa. In the first case, the surgeon described a hypertrophic subacromial bursa, in the second one, the bursa was oedematous and swollen, and in the last three cases, the bursa was void of lesions.

Fifteen (57%) out of 26 patients had a second class-like tendon type on ultrasonography (9 men aging between 34 and 61 years; 6 women aging between 54 and 74 years). The surgical examination showed 2 cases of supraspinatus tendon degeneration, 1 case of oedema of the whole rotator cuff, 2 cases of hyperaemic cuff, 2 cases of swollen and hyperaemic cuff; 2 cases of hemorrhagic cuff. There were 6 cases without any lesion of the cuff. The subacromial bursa was described as swollen with oedema in 3 cases, hypertrophic in 4 cases, hypertrophic and hyperaemic in 4 cases, void of lesions in 3 cases. Both sonography and surgery showed one or more calcifications in 9 cases, while 6 cases did not have any calcification.

In 6 (24%) out of 26 patients, ultrasonography detected a third-class tendon (2 men aged 50 and 62 years and 4 women aged between 44 and 55 years). On surgery, the rotator cuffs were described as void of lesions in 2 cases, in the third patient, hyperaemic spot was detected on the rotator cuff (impingement site), the fourth had globally hyperaemic cuff, the fifth inflammation of the cuff, and the sixth degenerated cuff. Both sonography and surgery showed one or more intra-tendinous calcifications in 3 cases, while the other 3 cases did not have any calcification. The comparison between surgery and sono CT findings is shown on Table 1.

Table 1. Comparison between sono CT findings and surgery (gold standard) in shoulders with no tears, partial thickness tear and full thickness tear

		SURGERY			Total
		No tear	Partial tear	Complete tear	
SONO CT	No tear	26	3	1	30
	Partial tear	-	9	-	9
	Complete tear	-	-	32	32
Total		26	12	33	

Discussion

MRI has always played an important role in the identification and characterization of musculoskeletal diseases.^{2,3} The technical drawback of the past conventional sonographic devices was limited possibility to reach the end of the diagnostic path using sonography by itself and forcing the radiologist to get more hints from other imaging techniques because the specificity and sensitivity of ultrasound examination were too low. The ultrasonographic evaluation of the shoulder joint has been performed since late 80's to describe the rotator cuff tears. The sensibility of the sonographic images in those years was not comparable to the MRI ones.^{2,11-13} In 1986, Middleton et al. performed a sonographic examination of the rotator cuff and described the drawbacks of sonography in evaluating the acute tears of the rotator cuff. The sensitivity and specificity obtained by those Authors was lower than 90%. In late 80's, standard criteria to describe the tears of the rotator cuff were not encoded yet.^{12,14} In 1989, Miller et al. performed a study on 56 patients, but the sensitivity of 93%, the specificity of 53% and the overall accuracy of 77% of their study were still too low.¹³

The technical development of the 90's with the introduction of the digital units allowed the image capture to be faster and rich in spatial details and time resolution with no loss of information and opened the possibility of accessing the post-processing tasks.^{5,6,10,15,16}

Those new features allowed Moriggl and Steinlechner to encode the sonographic criteria to describe the features of normal rotator cuff tendons.¹⁷

In our experience we noticed that, in particular, the reduction of noise and the increased overall image contrast resolution, given by the real time compound imaging technique, allowed us to study the supraspinatus tendon with the highest resolution and to

reach the best agreement between sonography and surgical findings.

Our experience with Sono CT on 71 patients demonstrates that the visualization of the rotator cuff tendon tears is possible with a level of accuracy that allowed us to estimate the features of the rotator cuff tendons and describe them in detail.

The possibilities offered by the Sono CT algorithm permitted us to perform a precise measuring of the tendon thickness and of subacromial space, due to less image artefacts, such as the speckle or the image blurring, which no more affected the image quality. In our experience, it was also possible to describe in detail whether intratendinous calcifications and fluid collections in the subacromial bursa were present or not.

In our experience, the full thickness acute tears were the lesions that we could better describe because the borders of the tear into the broken tendon were always visible. It was also always possible to describe other signs of acute full thickness tear as peritendinous inflammation or fluid collection in the subacromial bursa and obtain a good concordance with the surgical results.

Partial thickness tears were visible, but it was not possible to describe any of them as well as the full thickness tears. Actually, partial lesions demonstrated to be better superficial erosions than proper lesions of the tendon and occurred strictly under the lower border of the acromion where the conflict was present.

The drawbacks of the compound technique are linked to those of sonography itself. In obese patients and in people with hypertrophic musculature of the rotator cuff, the tendons are too deep to perform a correct diagnostic study and the high frequency probes are obviously not able to visualize at best those deep structures. The shoulder is perhaps an anatomical district in which the operator can take the best advantage from the compound technique use.

One of the major drawbacks of the compound technology is given by the reduction of the frame rate because of the delay in the multiple image processing. This reduction is sometimes a great limitation, in particular when deep structures are studied (i.e. studying the liver) because the image persistence is often the main artefact affecting the investigation. There are also other artefacts, like the image blurring that may slow down the examination. This is not the case of the shoulder investigation because the superficial position of the structures allows to proceed the study at a higher frame rate, maintaining the real time effect on.^{5,15,18}

Conclusions

The real time compound imaging technique is a full digital algorithm based on the digital beamformer unit. This unit permits the reduction of conventional sonography acoustic artefacts because there is no analogic digital conversion during the image capturing process, but the system is all-digital. The possibility to combine up to nine different digital images, captured in real time under nine different view angles, into a single final image increases the overall image definition. In particular, in the study of the rotator cuff, this new technique allows us to reach a better contrast resolution with smoother and more detailed images than conventional sonography ones. Those features, thanks to the new digital imaging capabilities, allow to obtain a good agreement between surgical findings and sonographic ones.

References

1. King LJ, Healy JC, Baird P. Imaging of the rotator cuff and biceps tendon. *J R Army Med Corps* 1999; **145**: 125-31.
2. Burk DL Jr, Karasick D, Kurtz AB, Mitchell DG, *Radiol Oncol* 2002; **36**(4): 319-25.

- Rifkin MD, Miller CL, et al. Rotator cuff tears: prospective comparison of MR imaging with arthrography, sonography, and surgery. *AJR Am J Roentgenol* 1989; **153**: 87-92.
3. D'Erme M, De Cupis V, De Maria M, Barbiera F, Maceroni P, Lasagni MP. [Echography, magnetic resonance and double-contrast arthrography of the rotator cuff. A prospective study in 30 patients]. [Article in Italian]. *Radiol Med* 1993; **86**: 72-80.
4. Drakeford MK, Quinn MJ, Simpson SL, Pettine KA. A comparative study of ultrasonographic and arthrography in evaluation of the rotator cuff. *Clin Orthop* 1990; **253**: 118-22.
5. Fabis J, Synder M. [The sensitivity and specificity of sonographic examination in detection of rotator cuff tear]. [Article in Polish]. *Chir Narzadow Ruchu Ortop Pol* 1999; **64**: 19-23.
6. Farin PU, Jaroma H. Acute traumatic tears of the rotator cuff: value of sonography. *Radiology* 1995; **197**: 269-73.
7. Leotta DF, Martin RW. Three dimensional ultrasound of the rotator cuff: spatial compounding and tendon thickness measurement. *Ultrasound Med Biol* 2000; **26**: 509-25.
8. Leotta DF. Three dimensional spatial compounding of ultrasound scans with weighting by incidence angle. *Ultrasound Imaging* 2000; **22**: 1-19.
9. Martino F, Mocchi A, Rizzo A, Dicandia V, Strada A, Macarini L, et al. [Echography of the supraspinatus tendon: forced passive adduction maneuver]. [Article in Italian]. *Radiol Med* 1998; **95**: 298-302.
10. Teefey SA, Middleton WD, Bauer GS, Hildebolt CF, Yamaguchi K. Sonographic differences in the appearance of acute and chronic full-thickness rotator cuff tears. *J Ultrasound Med* 2000; **19**: 377-8.
11. Fabis J, Kowalska A. [The value of radiological examination in the diagnosis of rotator cuff tear]. [Article in Polish]. The value of radiological examination in the diagnosis of rotator cuff tear. *Chir Narzadow Ruchu Ortop Pol* 1999; **64**: 447-52.
12. Middleton WD, Reinus WR, Melson GL, Totty WG, Murphy WA. Pitfalls of rotator cuff sonography. *AJR Am J Roentgenol* 1986; **146**: 555-60.
13. Miller CL, Karasick D, Kurtz AB, Fenlin JM Jr. Limited sensitivity of ultrasound for the detection of rotator cuff tears. *Skeletal Radiol* 1989; **18**: 179-83.
14. Middleton WD, Reinus WR, Totty WG, Melson

- CL, Murph. Ultrasonographic evaluation of the rotator cuff and biceps tendon. *J Bone Joint Surg Am* 1986; **68**: 440-5.
15. Teefey SA, Middleton WD, Yamaguchi K. Shoulder sonography. State of the art. *Radiol Clin North Am* 1999; **37**: 767-85.
16. Wallny T, Wagner UA, Prange S, Schmitt O, Reich H. Evaluation of chronic tears of the rotator cuff by ultrasound. *Bone Joint Surg Br* 1999; **81**: 675-8.
17. Moriggl B, Steinlechner M, Genser N. [Determining normal ultrasound values of the supra- and infraspinatus muscles]. [Article in German]. *Ultraschall Med* 1993; **14**: 52-7.
18. Thain L, Adler RS. Sonography of the rotator cuff and biceps tendon: technique, normal anatomy and pathology. *J Clin Ultrasound* 1999; **27**: 446-58.

