

p53 and lung cancer – more frequent p53 overexpression in patients with multiple primary tumours

Tomaž Rott,¹ Mario Poljak,² Olga Staniša,¹ Janez Orel,³ Andrej Debeljak⁴

¹Institute of Pathology and ²Institute of Microbiology, Faculty of Medicine, ³Department of Thoracic Surgery, University Medical Centre, Ljubljana, ⁴Institute for Respiratory Diseases Golnik, Slovenia

The tumor suppressor function of the gene p53 is abolished with its mutations, connected also with lifetime cigarette consumption, leading to growth promoting function of p53, and cancerogenesis in various organs. Seventeen resected primary lung cancers and 14 bronchial/transbronchial biopsy specimens were formalin-fixed and paraffin embedded. Fourteen specimens were from patients with multiple primary tumours. Sections were incubated with mouse anti-p53 antibodies, bound antibodies visualized by incubation with biotinilated rabbit anti-mouse immunoglobulins, followed by streptavidin-alkaline phosphatase. Using X-phosphate and nitro-blue tetrazolium, positive staining is observed as a dark bluish precipitate. Overexpression of p53 was found in 45.2% of all cases, 50% in 14 specimens of patients with multiple, and in 7 of 17 (41.2%) specimens of patients with solitary tumours. Ten of 16 (62.5%) specimens with epidermoid carcinoma showed positive reaction, 2/6 adenocarcinomas, 1/2 small cell, 1/5 large cell, and none 0/2 adenosquamous carcinomas. Bioptic specimens yielded better results than resected specimens. This difference could be attributed to inappropriate fixation. Positive reaction for p53 is more prominent in the basal layers of squamous metaplastic and dysplastic epithelium, disappearing towards better differentiated areas. It can be intense in poorly differentiated parts of invasive carcinomas. Normal respiratory epithelium did not yield positive reaction. p53 is related to the degree of tumor differentiation. We have still to elucidate the relationship between smoking and p53 expression, and controversial opinions about its influence on the survival of the patients. The detection of p53 in routine bronchial/transbronchial biopsis could reveal the patients, especially smokers at higher risk for development of solitary or multiple primary malignancies.

Key words: lung neoplasms; genes, p53; multiple lung neoplasms

Introduction

Tumors arise and progress through a series of genetic changes in cancer-associated genes

Correspondence to: Prof. Tomaž Rott, M.D., Ph.D., Institute of Pathology, Faculty of Medicine, Korytkova 2, 61105 Ljubljana, Slovenia.

UDC: 616.24-006.6-097

known as proto-oncogenes or tumor-suppressor genes. Proto-oncogenes are normal cellular genes that, when inappropriately *activated* as oncogenes, cause dysregulation of growth and differentiation pathways, and enhance the probability of neoplastic transformation. In contrast, tumour-suppressor genes are normal cellular genes, which when *inactivated* lead to a

disturbance of cell proliferation and the development of neoplasias.¹

So far, the best known tumor-suppressor gene is the p53 gene, localized on the chromosome 17. This gene is thought to play an important role in the regulation of cell proliferation, and it has been suggested that the loss of normal p53 function is associated with cell immortalisation or transformation *in vitro*, and development of neoplasms *in vivo* in various organs (lung, breast, ovary, colon, thyroid gland, oral cavity, head and neck, some soft tissue tumours, etc). The alterations within the coding sequences of the p53 gene are among the most frequent genetic changes detected in human cancers. The p53 gene or gene product is a common cellular target in human carcinogenesis provoked by physical factors, chemical carcinogens or tumour viruses.²

In cells, wild-type p53 protein has a short half-life (5–20 min) and, thus, does not accumulate to detectable levels under normal conditions. Mutations in the p53 gene often result in the production of a protein with altered composition and a prolonged half-life. As a result, mutant p53 accumulates in tumour cells and can be detected immunohistochemically. Therefore, a visualisation of this protein usually means mutation, and detection of p53 overexpression by immunohistochemical techniques is currently widely used as an indirect indicator of p53 mutations.³

The aim of the study was to evaluate the appearance of the suppressor gene product p53 in hyperplastic, dysplastic lesions of the lung, and in various histologic types of lung cancer. This is an interim report of our experiences in looking for p53 overexpression in patients with lung cancer. Taking into consideration that p53 gene mutations may be a pathway through which environmental carcinogens (also associated with smoking) trigger lung cancer, we expect more frequent p53 overexpression in patients with multiple primary malignancies and a history of smoking.

Material and methods

Seventeen resected primary lung cancers and

14 bronchial/transbronchial biopsy specimens, 14 of these from patients with metachronous or synchronous multiple primary tumours of the lung or other sites, were formalin-fixed and paraffin embedded.

Dewaxed sections were rehydrated and treated with 0.05% saponin in distilled water for 30 min at room temperature. Subsequently, the sections were incubated with mouse monoclonal anti-p53 antibodies (Ab-2, clone PAb 1801, Oncogene Science, Uniondale, NY, USA, in working dilution 1:2000) overnight at 4°C⁹). Bound antibodies were visualized by incubation with biotinylated rabbit anti-mouse immunoglobulins for 30 min at room temperature (dilution 1:200, Dako E 354, Dakopatts, Glostrup, Denmark), followed by streptavidin-alkaline phosphatase for another 30 min at room temperature (dilution 1:100, Dako D 396, Dakopatts, Glostrup, Denmark). Alkaline phosphatase activity was developed with the McGadey reagent (4-Nitro blue tetrazolium chloride and 5-Bromo-4-chloro-3-indolyl phosphate) containing 1mM levanisole for 30 min in the dark at room temperature. Positive staining was observed as a dark bluish precipitate. Section were counterstained with Mayer's hematoxylin and mounted in glyceryl gelatine.

The sections of laryngeal squamous carcinoma, which had been previously found to overexpress the p53 protein and which reacted with this antibody, were used as a positive control. Sequential sections of patient tissues incubated in buffer without the primary antibody served as negative controls.

Results

Overexpression of p53 was found in 45.2% of all cases, 50% in 14 specimens from the patients with multiple malignancies, and in 7 of 17 (41.2%) specimens from the patients with solitary malignancies.

Ten of 16 (62.5%) specimens with epidermoid carcinoma showed positive reaction of various intensity, however in only 2 of 6 adenocarcinomas (33.3%), 1 of 2 small cell carcinomas, in only 1 of 5 (20%) large cell carcinomas,

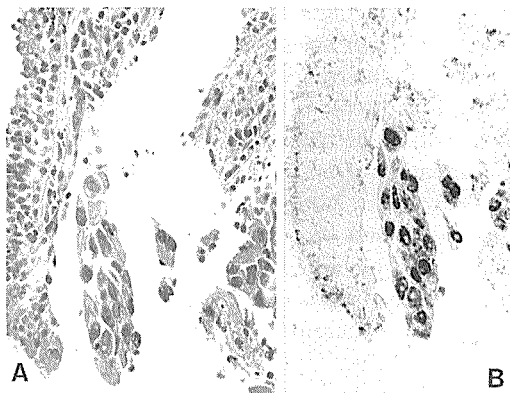


Figure 1. Bronchial biopsy. p53 overexpression in adenocarcinoma in the respiratory epithelium. A. hematoxylin-cosin staining. B. immunohistochemical demonstration of p53.

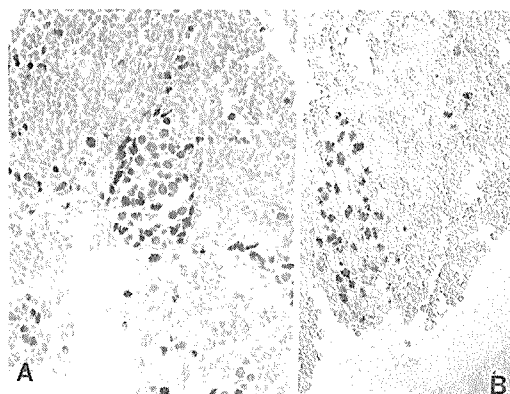


Figure 2. Bronchial biopsy. p53 overexpression in a cell group of small-cell carcinoma. A. hematoxylin-cosin staining. B. immunohistochemical demonstration of p53.

and in none of two adenosquamous carcinomas (Figures 1, 2). Bioptic specimens yielded better results (8/14, 57%) than resected specimens (6/17, 35.3%).

Positive reaction to p53 is more prominent in the basal layers of squamous metaplastic and dysplastic epithelium, disappearing towards better differentiated areas (Figure 3). The expression of p53 was irregular in scattered or more numerous cells in the squamous epithelium: if present, there were only few p53 positive cells in squamous metaplastic respiratory epithelium,

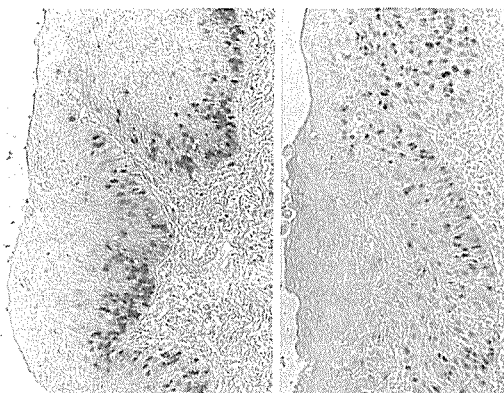


Figure 3. Lung lobe resection. More prominent p53 overexpression in the basal layers of squamous metaplastic and dysplastic epithelium, disappearing in better differentiated areas.

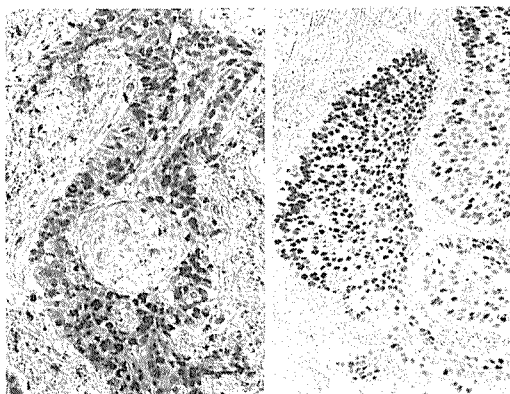


Figure 4. Intense p53 overexpression in the areas of invasive lung cancer.

some more in dysplastic epithelium and numerous in invasive carcinoma, especially in less differentiated areas (Figure 4). Normal respiratory epithelium did not yield positive reaction.

Discussion

It is now known that cancer is caused by a series of genetic changes, each potentially leading to a clonal outgrowth of cells through a selective growth advantage. The determination of the nature and timing of these changes is critical to both clinical and biological understanding of the disease.¹

The frequency of p53 expression in our preliminary limited study is in accordance with the data from other reports (it is detected in 43–79.5% of squamous carcinomas, in 33–52% of adenocarcinomas, and in 20% of small-cell carcinomas.^{4–7} p53 is very probably related to the degree of tumor differentiation and grade⁵, and p53 overexpression is high in cells predetermined to differentiate and decreases upon differentiation.⁸ It is present in premalignant lesions such as metaplastic and dysplastic bronchial epithelium, but not in normal respiratory epithelium.⁷ There is a difference in p53 positivity in various histologic types, with best results in epidermoid carcinoma. The source of the material (biopsy, resection) is probably irrelevant for successful presentation of p53. The difference in our results could be attributed to unappropriate fixation.

Mouse anti-p53 monoclonal antibodies PAb 1801 have been reported to recognise an epitope detectable both in frozen and in formalin-fixed paraffin-embedded tissue sections.^{9,10} This epitope, mapped near the amino terminus of the p53 protein between residues 32 and 79, is shared by the wild-type p53 and by almost all mutant forms so far described.¹¹ There have been, however, some pitfalls in the interpretation of the results of p53 immunohistochemistry described.^{12,13} Negative immunostaining in the presence of a mutation might be the result of gross deletions or null-mutations abolishing all p53 production. Additional mechanisms, such as reduced half-life of p53 protein, mediated by a mutant endogenous protein, or a viral proteins such as human papilloma virus 16 or 18 E6, might contribute to the population of cells in which p53 is not detectable by this method. Positive p53 immunohistochemistry without a mutation present may be due to the interruption of the normal degradative pathway of p53. Despite possible discrepancies between the findings at the DNA level and at the protein level, we believe that p53 immunohistochemistry has value for monitoring the functional status of the p53 protein per se.

The tumor suppressor function of the gene p53, abolished with its mutations, is also asso-

ciated with lifetime cigarette consumption.¹⁴ It leads to growth promoting function of p53, as well as to carcinogenesis in various organs (lung, breast, colon, thyroid gland, oral cavity, some soft tissues etc). Thus it is important for the initiation of malignancies.

As expected, more frequent p53 presentation was also found in tumor specimens from patients with solitary or multiple tumours. But the number of cases is still too small for definite conclusions. Therefore, further study is under way.

The association of tobacco smoking with p53 expression suggests that the p53 gene is a target for specific mutagens in tobacco smoke.⁵ Therefore, we still have to elucidate the relationship between smoking and p53 expression, and also explain the controversial opinions as to whether immunohistologic expression of p53, in any group of patients with lung tumors has really no influence on the patients' survival as believed by some authors,^{4,6} or p53 mutations and accumulation in primary human lung cancers have a statistically significant negative prognostic value, as reported by the others.^{15,16}

Conclusion

Taking into consideration the gradual increase in the p53 overexpression in metaplastic, dysplastic, and carcinomatous tissue, and even more frequent p53 overexpression in multiple primary tumours, the detection of p53 in routine bronchial/transbronchial biopsies could help to identify the patients, especially smokers, with a higher risk for the development of solitary or multiple primary malignancies. In future, p53 could also be considered as a potential target for anticancer drugs.¹⁷

References

1. Wynford-Thomas D. Oncogenes and anti-oncogenes; the molecular basis of tumor behaviour. *J Pathol* 1991; **165**: 187–201.
2. Donehower LA, Bradley A. The tumor suppressor p53. *Biochim Biophys Acta* 1993; **1155**: 181–205.

3. Zambetti GP, Levine AJ. A comparison of the biological activities of wild-type and mutant p53. *FASEB J* 1993; **7**: 855–65.
4. Volm M, Efferth T, Mattern J. Oncoprotein (c-myc, c-crbB1, c-crbB2, c-fos) and suppressor gene product (p53) expression in squamous cell carcinomas of the lung – clinical and biological correlations. *Anticancer Res* 1992; **12**: 11–20.
5. Westra WH, Offerhaus GJA, Goodman SN et al. Overexpression of the p53-tumor suppressor gene product in primary lung adenocarcinomas is associated with cigarette smoking. *Amer J Surg Pathol* 1993; **17**: 213–20.
6. McLaren R, Kuzu I, Dunnill M, Harris A, Lane D, Gatter KC. The relationship of p53 immunostaining to survival in carcinoma of the lung. *Br J Cancer* 1992; **66**: 735–8.
7. Bennett WP, Colby TV, Travis WD et al. p53 protein accumulates frequently in early bronchial neoplasia. *Cancer Res* 1993; **53**: 4817–22.
8. Montemar M. Functional implications of the growth-suppressor/oncoprotein p53. *Int J Oncol* 1992; **1**: 37–45.
9. Bosari S, Roncalli M, Viale G, Bossi P, Coggi G. p53 immunoreactivity in inflammatory and neoplastic diseases of the uterine cervix. *J Pathol* 1993; **169**: 425–30.
10. Bennet WP, Hollestein MC, He A, et al. Archival analysis of the p53 genetic and protein alteration in Chinese esophageal cancer. *Oncogene* 1991; **6**: 1779–85.
11. Nigro JM, Baker SJ, Precisinger AC, et al. Mutations in the p53 gene occur in diverse human tumour types. *Nature* 1989; **342**: 705–8.
12. Wynford-Thomas D. p53 in tumour pathology: can we trust immunocytochemistry? *J Pathol* 1992; **166**: 329–30.
13. Hall PA, Lane DP (editorial) p53 in tumor pathology: can we trust immunohistochemistry? – revisited! *J Pathol* 1994; **172**: 1–4.
14. Suzuki H, Takahashi T, Kuroishi T, Suyama M, Ariyoshi Y, Takahashi T, Ueda R. p53 mutations in non-small cell lung cancer in Japan – association between mutations and smoking. *Cancer Res* 1992; **52**: 734–6.
15. Quinlan DC, Davidson AG, Summers CL, Warden HE, Doshi HM. Accumulation of p53 protein correlates with a poor prognosis in human lung cancer. *Cancer res* 1992; **52**: 4828–31.
16. Mitsudomi T, Oyama T, Kusano T, Osaki T, Nakanishi R, Shirakusa T. Mutations of the p53 gene as a predictor of poor prognosis in patients with non-small-cell lung cancer. *J Natl Cancer Inst* 1993; **85**: 2018–23.
17. Brown R. p53: a target for new anticancer drugs or a target for old drugs. *Ann Oncol* 1993; **4**: 623–9.