

Renal cell carcinoma in the ectopic kidney prospects of diagnosing and treatment of the carcinoma of the kidney: case report

Erika Brenčič¹, Marjeta Stanovnik², Mojca Glušič¹

¹Clinical Radiology Institute, University Medical Centre, Ljubljana, Slovenia

²Institute of Oncology, Ljubljana, Slovenia

Background. An extensive use of ultrasonography and computed tomography have enormously contributed to the early detection of adenocarcinoma of kidney taking into consideration that they have been so far often detected by chance. In addition to provide us with an image of a tumor and contributing to define more easily the nature of tumor, MRI is most helpful in detecting the infiltrations of tumor into its surrounding and changes in the veins.

Case report. This case report presents the patient with adenocarcinoma of the ectopic kidney. The ultrasonography, computed tomography and magnetic resonance imaging detected an abundant non-homogenous tumor mass in pelvis minor. Additionally to the suspected ectopia of one of the kidneys, it was also suspected that there was another pathological process of different etiology too. This suspicion was based on the detection of a different tumor mass in between the intestinal loops. Two months after the nonradical excision of the adenocarcinoma from the ectopic kidney, the following changes were observed: progress of the residual tumor in the pelvis minor and the tumor in between the intestinal loops (that was not removed during the first operation). The patient was given immunochemotherapy and local radiotherapy.

Conclusions. According to the available data in literature, the localization of tumor in ectopic kidney is extremely rare.

Key words: kidney neoplasms - diagnosis - ultrasonography - surgery; carcinoma, renal cell; tomography, computed, magnetic resonance imaging

Introduction

Renal cell carcinoma (adenocarcinoma) of kidney is quite a frequent malignant tumor. It is diagnosed in 90% of all malignant tumors of kidney. This tumor type is characterized by different clinical and morphological properties. It is considerably well radiosensitive. The only mode of treatment assuring a complete cure is surgical removal of primary tumor and solitary metastases.¹

Received 17 May 2000

Accepted 5 June 2000

Correspondence to: Assist. Erika Brenčič, MD, Clinical Radiology Institute, University Medical Centre Ljubljana, Zaloška 7, SI 1525 Ljubljana, Slovenia.
Phone: +386 1 5408 400; Fax: +386 1 133 31 044

Survival of patients depends on their clinical status at the time of diagnosis. The patient's clinical status is determined by spread of disease, involving local infiltration in the surrounding tissue and the presence of distant metastases.

The examinations, such as ultrasonography (US), computer tomography (CT) and magnetic resonance (MR) have enormously contributed not only to obtain better possibilities of detecting malignant or benign tumors of kidneys but also to their more successful detection.² Each renal mass having different density after the injection of contrast media is considered as a tumor until it's proven differently.

Adenocarcinoma of kidney is a rare malignancy in childhood and adolescence. At the time of diagnosis, one half of patients have no signs of hematuria; tumor is usually detected by chance.

Case report

A 37-year-old patient was treated at the Institute for Family Planning in the year 1988, where the dysfunction of the left ectopic kidney accompanied by a compensatory enlargement of the right kidney were observed.

In May 1996, the patient's sperm had been taken for the in vitro fertilization. At that time, hematospermia was observed. The patient was therefore referred to the urologist. Cytoscopic examination detected a substantially enlarged median lobe of the prostate and the wall of bladder was slightly pushed upwards to the usual location of the left ostium. The subsequent US examination confirmed the ectopia of the left pelvic kidney.

By the end of 1996, the patient complained of the problems in discharge of excreta despite normal appetite and digestion. He felt a stifling pain in the lower part of abdomen. In February 1997, the patient himself palpat-

ed the tumor by digital examination of rectum. He was immediately referred to the urologist.

The diagnostic procedure included also US examination which detected a profuse heterogeneous tissue of serous and solid structure, its size was 8x8.3 cm at the back of bladder on the left. These findings were the reason that we suspected a pathologically changed left ectopic kidney or left seminal vesicle. After having performed the biopsy examination, the cytologic findings could not reliably define the nature of this process. The cells resembled to those of spermatogenesis. On the other hand, the suspicion of tumor could not be definitely excluded.

CT examination discovered a non-homogeneous tumor mass of 8x8 cm behind the urinary bladder (Figure 1a). The core of the tumor was hypodense, while the peripheral area was seen as a granular soft-tissue accumulation spreading towards the center. There was no infiltration of the tumor into the bladder observed, while the tumor margins on the side of the prostate, rectal wall and internal obturator muscle were not clear. Seminal vesicles were not seen, while the same examination detected other soft-tissue tumor masses between the loops of the jejunum (Figure 1b).

At the beginning of March 1997, the MR of the pelvis minor confirmed further growth of the tumor mass behind the bladder (Figure 2a). On T2-weighted image, the intensity of signal was different: It was hyperintensive in the core of tumor and hypointensive in its peripheral area. In the sagittal plane, the complete size of tumor mass could be seen, protruding into the wall of the urinary bladder and rectum (Figure 2b). On the T1-weighted image, the tumor was well differentiated after the injection of contrast media, with hypointensive signal in its core and weak hyperintensive signal in the periphery (Figure 3).

The MR image of the tumor was similar to the findings of CT examination. They both

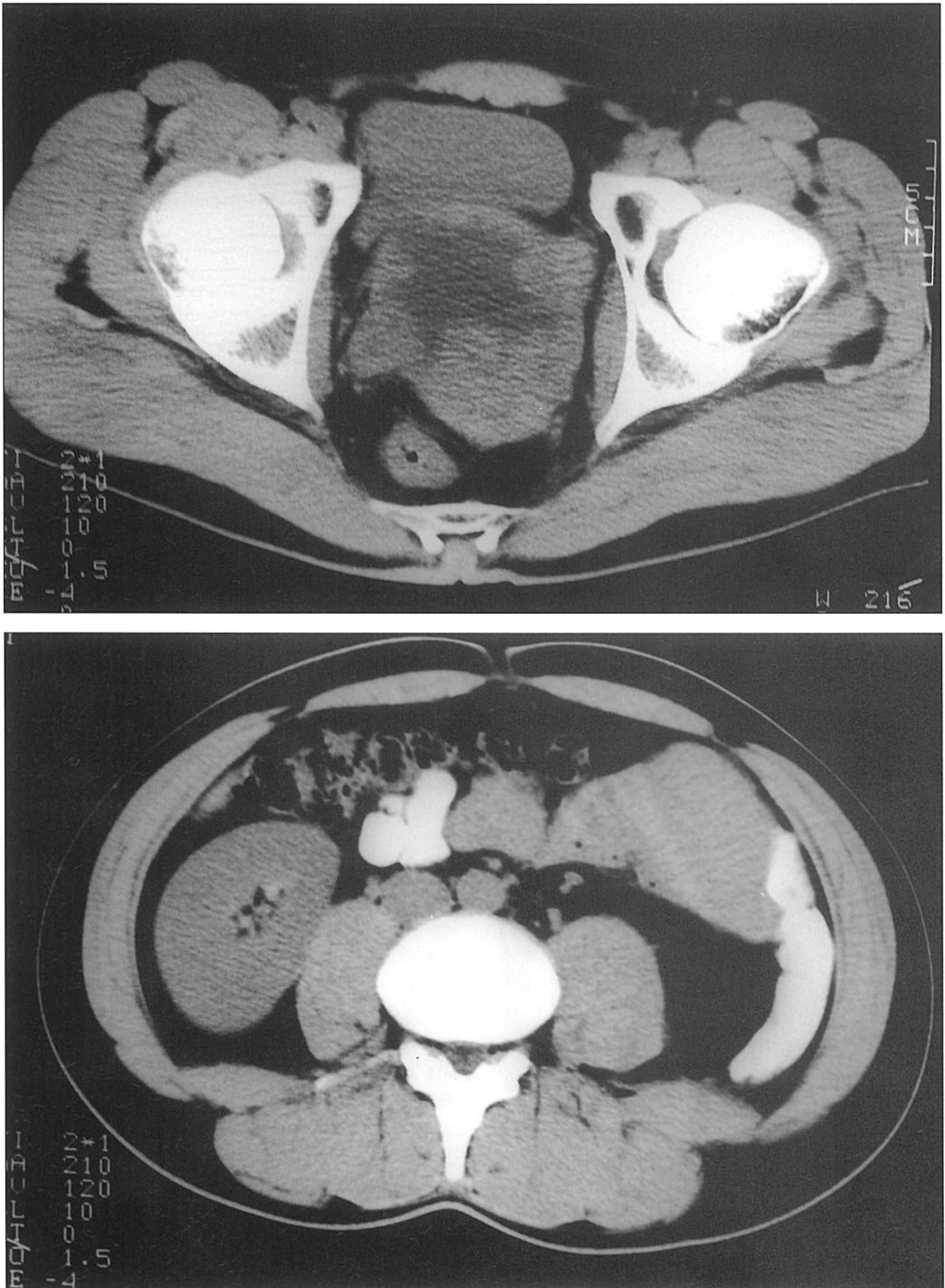


Figure 1. (a) CT visualization of non-homogenous well differentiated tumor in pelvis minor: The core of tumor is hypodense, whereas the periphery is granular soft tissue. (b) Soft tissue tumor.

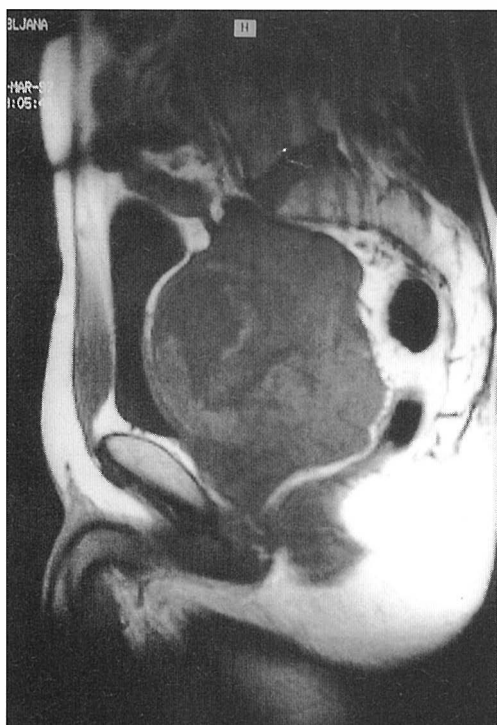
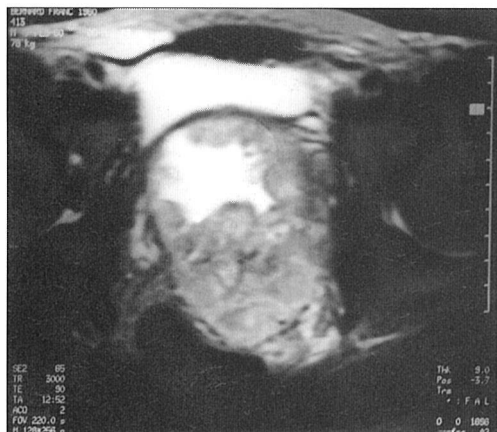
Figure 2. (a) MR image of tumor: On T2-weighted image, the signal in tumor core is hyperintense, whereas in the periphery the signal is hypointense. (b) Sagittal plane: The T1-weighted image of tumor.

confirmed the tumor in the ectopic kidney. Another differential option of these findings was germinal tumor or malignant tumor of another etiology.

Radiol Oncol 2000; 34(2): 191-8.

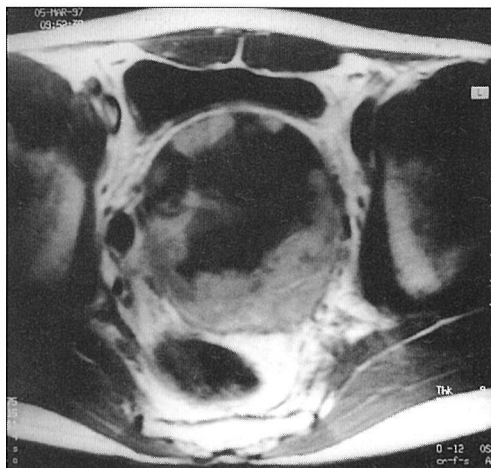


Figure 3. T1-weighted image of tumor: After the injection of contrast medium, the signal in the tumor core is hypointense, whereas in the periphery the signal is mildly hyperintense.

After the MR examination, the tumor in the pelvis minor was surgically removed. The histology findings confirmed the tissue of primarily papillary and partly solid clear cell carcinoma of the kidney, grade II-III. On one spot of the tumor area, the angioinvasion of tumor tissue was observed.

Post-operative treatment of the patient was normal. After having been discharged from the hospital to home care he was quite in a good condition.

At the beginning of May 1997, pains in the lower part of abdomen started again. The patient complained of having complications with excretion as well as of the constant stinging pain in the lower part of abdomen. The US examination at the end of May discovered an echosolid and also palpable formation (size 5x5cm) in the right inferior part of abdomen (Figure 4). It was assumed that this formation was either a residuum of tumor after the operation or recurrence.

Afterwards the patient underwent further diagnostic examinations, among them also the X-ray of thorax which findings were within limits. The cytoscopic findings detected that the trigone and orifice of bladder and

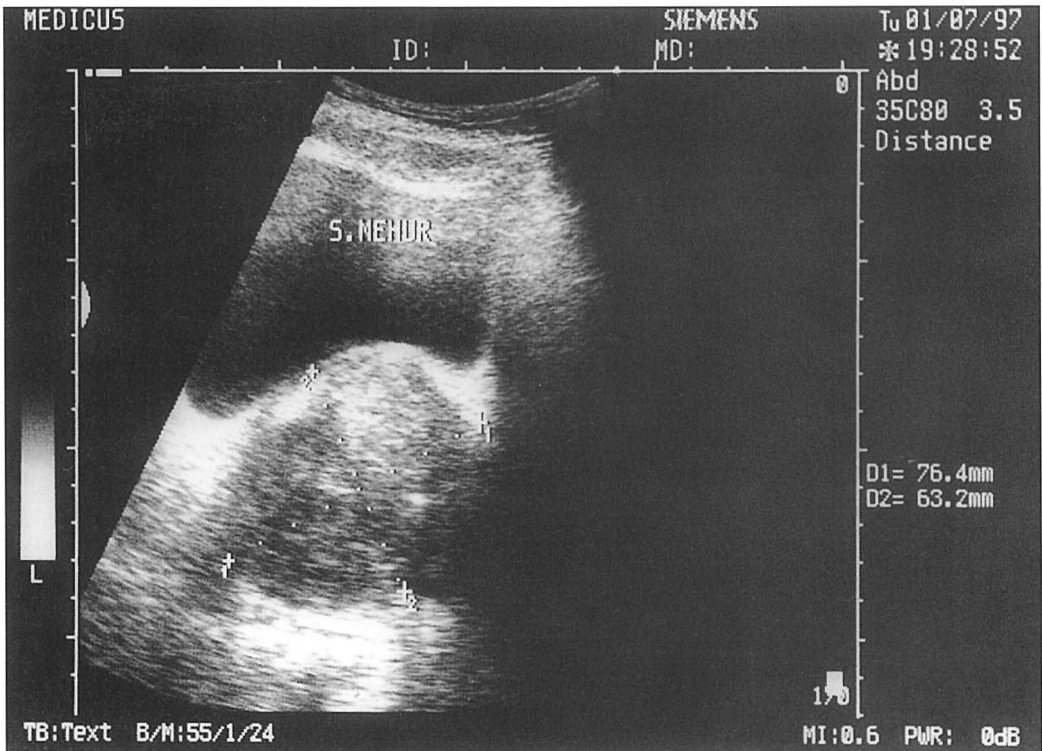


Figure 4. US visualization of echosolid tumor mass in pelvis minor.

prostatic lobe were slightly elevated. The mucous membrane of trigone was edematous. The digital examination of rectum detected a smooth and resilient formation pressing against it.

Another CT scan discovered two different kinds of masses; one was abundant solid tumor mass in between the loops of small intestine and colon, and the other granular solid tumor mass near the pelvic wall on the left and on the very place as it was the primary tumor. Both tumors were not connected to each other. Nevertheless in pelvis minor it was suspected that there was a tumor infiltration into the surrounding.

The patient was admitted to the treatment at the Institute of Oncology, Ljubljana. An US guided biopsy of the tumor in pelvis was performed and the subsequent histology findings confirmed the recurrence of the same type of tumor, as it was the primary one, i.e. small cell

carcinoma corresponding to the carcinoma of kidney. The medical team at the Institute of Oncology decided to treat the patient with combined chemoimmunotherapy.

The patient received Paraplatin 3x750 mg, intravenously, in 3 weeks' interval, Vinblastin 4 mg, 24-hour infusion, in 2 weeks' interval, and Intron A 3.000.00, subcutaneously, 3 x / week. During the therapy, the patient suffered from some mild toxic effects, such as myelosuppression.

During the treatment, several US examinations were performed and two CT scans.

After the immunochemotherapy the clinical status of the patient improved. US examination also confirmed the decrease and colliquation of tumor. After a 3-month combined immunochemotherapy, the patient was referred again, if possible to operate him additionally. The CT scan showed the progression of disease with an extensive tumor masses in

the abdomen. The infiltration of tumor was observed in the surrounding tissue; particularly suspected infiltration was that one growing into the wall of rectum (Figures 5a,b). Another surgery was not possible any more, so the medical team decided for symptomatic palliative irradiation treatment. The tumor in the abdomen was pressing against the wall of rectum and for this reason the patient was obstipated. The patient received radiotherapy with TD 1800 cGy (180 cGy a day). Additionally to the radiotherapy, the patient received sensibilization treatment with Velbe 2mg in 24 hour infusion, 2 x / week. Despite the radiotherapy, progression could not be prevented.

In January 1998, the patient's condition deteriorated. At first he suffered from rectovesicle fistula followed by ileus. In March 1998, a preternatural anus was made in the transversal part of colon. The patient died in April 1998, due to a rapid progression of tumor into the abdomen.

Discussion

Despite properly selected diagnostic method and subsequent treatment modalities, we are not always in a position to influence favorably the course of disease.

Carcinoma of kidney has too often been detected by chance. The detection of this disease has become more successful when US and CT have been applied. With further improvement of diagnostic techniques we have had wider possibilities to detect tumors, even to determine their nature, as well as to distinguish between the benign and malignant one. Staging of the disease may essentially affect its treatment and prognosis. Early and accurate diagnose detected by US and CT should be strictly based on morphological criteria. The adenocarcinoma of kidney is often seen as a solid or non-homogenous accumulation and may be lobulated and clearly demarcated.

Necrosis or hemorrhage often occurs in the core of tumor mass. It is important to assess the density changes in the mass after the injection of contrast medium.

CT scan is a vital diagnostic method at the detection and staging of kidney carcinoma. MR imaging is similar to CT scan, however, it is more successful in staging. It detects eventual anomalies and their extent, the veins and the surroundings of organs are more clearly perceptible.³ CT scan cannot detect the microscopic invasion into the perirenal fatty tissue and cannot distinguish between inflammatory changes and tumor infiltration or identify small collaterals and infiltrations into the lymphatic system.² When defining the nature of tumor mass with an option to distinguish between the adenocarcinoma of kidney and the mesenchymal tumor on the basis of morphological changes and densitometry of CT scan, it would be more likely suspected that adenocarcinoma dominates.⁴ A solitary lesion in kidney is usually the primary tumor, though the distinction between primary and secondary tumors is very complicated.⁵ It is possible to observe simultaneously the renal arteries and veins, parenchyma and renal pelvis system with aid of recent technical innovations using fast sequences and contrast media during MRI. MRI can therefore be performed on any patient irrespective of age and readiness to co-operate in the examination.

It was suspected that our patient had an ectopic kidney. CT scan and MRI detected a large non-homogenous tumor mass in pelvis minor. Considering the images, restrictions and changes after the injection of contrast media, the CT scan and MRI diagnoses were malignant tumor of ectopic kidney. The T1- and T2-weighted MR images showed a tumor with a typical necrosis and hemorrhage in its core. The seminal vesicles were not seen in any MR images. Therefore, it was suspected that tumor was infiltrated into the surrounding tissue. The first CT scan did not detect another tumor which has not been removed

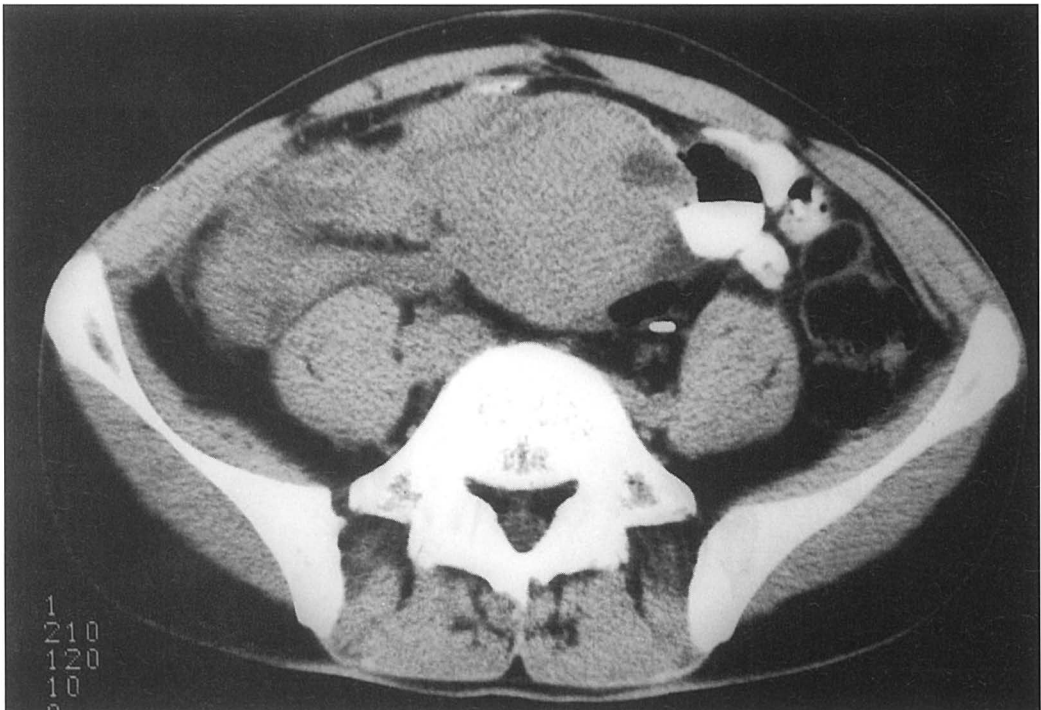
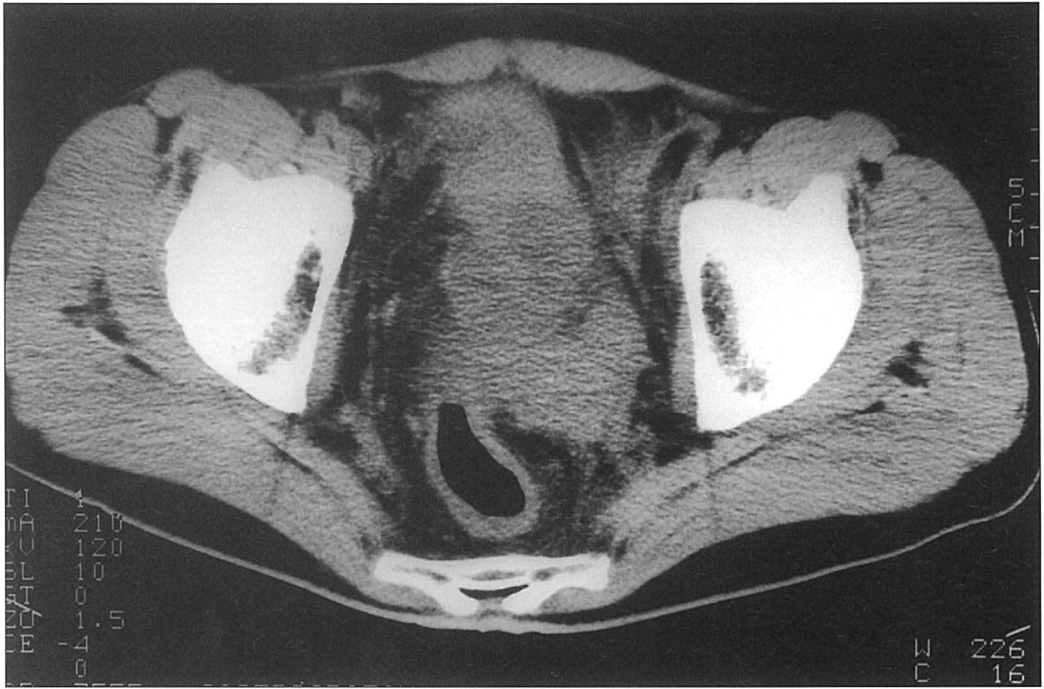


Figure 5. (a) CT visualization of tumor residuum in pelvis minor. (b) CT visualization of soft-tissue tumor in between the intestinal loops.

during the first operation was detected in between the intestinal loops. That tumor could have had the metastatic spread into the pelvis. Another differential diagnostic option was presence of the tumor of different etiology. The histologic findings of surgically removed tumor as well as cytological biopsy of residual tumor and/or its recurrence confirmed the adenocarcinoma of ectopic kidney.

Another review of the images of the first CT scan and MRI did not provide us with any additional data. Neither renal artery nor vein of the ectopic kidney could be seen on those images. The margins between the tumor and the surrounding organs with suspected infiltrations were better seen on MR images. There was no enlargement of lymph nodes detected on any of those images. Unfortunately, all the subsequent CT scans after the operation and during the therapy confirmed only a rapid progression of the disease.

A tumor localized in an ectopic kidney has been rarely reported in literature. Our case report confirms that despite current potential diagnostics, surgical treatment, choice of chemoimmunotherapy and radiotherapy it was not possible to slow down or to prevent from the progression of disease.

References

1. Wegener OH. The kidney. In: *Whole body computed tomography*. Boston: Blackwell Scientific Publications; 1993. p.374.
2. Bechtold RE, Zagoria RJ. Imaging approach to staging of renal cell carcinoma. *Urol Clin N Am* 1997; **14**: 507-22.
3. Kreft BP, Müller-Miny H, Sommer T, Steudel A, Vahlensieck M, Novak D, Müller BG, Schild HH. Diagnostic value of MR imaging in comparison to CT in the detection and differential diagnosis of renal masses: ROC analysis. *Eur J Radiol* 1997; **7**: 542-7.
4. Dalla-Palma L, Pozzi-Mucelli R. Problematic renal masses in ultrasonography and computed tomography. *Clin Imag* 1990; **14**: 83-98.
5. Schubert RA, Soldner J, Steiner T, Schubert J, Kaiser WA. Bilateral renal cell carcinoma in a horseshoe kidney: preoperative assessment with MRI and digital subtraction angiography. *Eur Radiol* 1998; **8**: 1694-7.