

BLINDED PLACEBO STUDY OF BILATERAL OSTEOARTHRITIS TREATMENT USING ADIPOSE DERIVED MESENCHYMAL STEM CELLS

Luka Mohoric¹, Bojan Zorko², Katerina Ceh¹, Gregor Majdic^{3,4*}

¹Animacel biotechnology ltd; ²Small animal clinic, ³Center for Animal Genomics, Veterinary Faculty, University of Ljubljana, 1000 Ljubljana, ⁴Institute of physiology, Medical faculty, University of Maribor, 2000 Maribor, Slovenia

*Corresponding author, E-mail: gregor.majdic@vf.uni-lj.si

Summary: Mesenchymal stem cell therapies attract a lot of attention and also controversy in veterinary medicine. In the present study, mesenchymal stem cell therapy, using autologous cells from adipose tissue was evaluated for the treatment of osteoarthritis in the knee. Ten dogs with bilateral osteoarthritis in the knees were included in the study. After collection of adipose tissue and expansion of cells, 2 to 3 millions of mesenchymal stem cells were injected into one knee while sterile phosphate buffer (same as used for resuspension of cells) was injected into the other knee as a placebo. Dog owners were blind in regard which knee received cells and which placebo. Dogs were clinically evaluated before treatment and 3, 6 and 12 months after the treatment, and synovial fluid was collected and evaluated before treatment and after 12 months. Radiographs of both knees were taken before treatment and 6 and 12 months after the treatment. In 9 out of 10 dogs enrolled in the study, there was a significant improvement of lameness after 1 year. Radiographs did not show improvement in the cartilage condition 1 year after the treatment. However, in 7 out of 10 treated joints the osteoarthritis did not progress while in all 10 of placebo treated joints there was a significant worsening of the osteoarthritis. Analysis of the synovial fluid before and 1 year after the treatment showed no statistically significant differences between mesenchymal stem cells treated and placebo treated knees. Results of this study suggest beneficial effects of mesenchymal stem cells treatment in osteoarthritis in dogs and confirm that mesenchymal stem cells treatment is a viable option for managing this debilitating disease in dogs.

Keywords: dog; osteoarthritis; knee; mesenchymal stem cells

Introduction

Osteoarthritis is a common disease in dogs that affects dogs of all ages. Although large joints such as hips, elbows and knees are most often diagnosed with osteoarthritis, this disease could affect many other joints including vertebral facet joints, carpal and tarsal joints, and also metacarpal and metatarsal joints (1, 2). The incidence of osteoarthritis in general population of dogs is about 20 %, while in aging (older than 8 years) dogs, it can reach up to 80 % (3). Clinical signs of

osteoarthritis are very variable, but most common signs are pain and reduced physical functioning of dogs (1, 2). Currently, osteoarthritis cannot be cured and dog owners are usually offered pain management. With proper pain management the quality of life of dogs could be improved, although the disease cannot be cured and regular pain management therapy is both financial and life-style burden for dogs and their owners, and could have significant side effects (1, 2).

In recent years, stem cells have attracted a lot of attention as potential source of biological agents for regenerative treatments. Basic studies in laboratory rodents are slowly translated into clinical settings.

Stem cells are generally divided into three categories: (i) embryonic stem cells that are obtained from very early embryos, (ii) adult stem cells that can be found in different adult tissues, and (iii) induced pluripotent stem cells which are adult differentiated cells turned into stem cells by activation of several genes in these cells (4-7). Adult stem cells are most often derived from adipose tissue or bone marrow and are usually called mesenchymal stem cells (8). These are currently being exploited in numerous basic studies and clinical trials. Adult mesenchymal stem cells have several important advantages for potential clinical use as they can be easily obtained from different tissues, and they are suitable for autologous treatments as they can be obtained from diseased patients (8).

Several basic and clinical studies have suggested beneficial effect of adult mesenchymal stem cells in the treatment of osteoarthritis in different species from laboratory animals to dogs and horses (9-14), although there is still an urgent need for more clinical trials to confirm the benefit of stem cell treatments in dog osteoarthritis.

In the present study, we have therefore evaluated the efficacy of mesenchymal stem cell treatment for knee osteoarthritis in adult, clinical patients, dogs.

Material and methods

Patients

Ten dogs with bilateral osteoarthritis were included in the current study. All dogs were clinical patients at the Clinic for small animals at Veterinary faculty, University of Ljubljana. Five of them were German boxer and five were other breeds. Five were male and five were female. Average age of dogs was 6.2 years. Dog owners voluntarily participated in the study after being informed about all potential risks and benefits of such trial treatments and have signed an informed consent (in Slovenian language). All animal procedures were performed according to the best practice of Veterinary care. As study was done on a client owned clinical patients, no approval from ethical committee was needed according to the Slovenian legislation.

Before treatment all dogs were clinically, neurologically and radiographically examined and the osteoarthritis was confirmed in both knee joints. All dogs were negative to tick diseases and had no sign of any infection.

On day one all dogs were lame. Lameness was divided into five groups according to Brunnberg (15) from 0 to IV. 0 = normal; I = hardly noticeable lameness; II = noticeable, leg is still loaded; III = noticeable, leg is occasionally not loaded; IV = leg is not loaded.

On radiographs all dogs had severe signs of osteoarthritis and were also divided in five groups according to Brunnberg (28) 0 = normal; I = minimal osteophyte formation; II = obvious osteophyte formation; III = multiple moderate osteophyte formation; IV = large osteophyte formation and deformity of bone ends.

Tissue collection

Dogs were premedicated with morphine (Morphini chl., Alkaloid, Skopje Macedonia) 0.3 mg/kg s/c, and anesthesia was induced with midazolam (Midazolam Torrex, Chiesi Pharmaceuticals, Manchester, UK) 0.1 mg/kg iv and propofol (Norofol, Norbrook Laboratories, Corby, UK) 3 - 4 mg/kg iv and maintained with sevoflurane (Sevorane, Abbott, Maidenhead, UK) in oxygen. Dogs were administered Lactated ringer's solution (Hartmann solution, B Braun, Melsungen, Germany) during anesthesia (5 ml/kg/h i/v). Adipose tissue was collected through small incision on the back between scapulae. Tissue was immediately placed in the transport media and transported into the cell culture laboratory.

Cell preparation

Tissue was dissected into small pieces and incubated with 1 mg/ml collagenase (Sigma, Taufkirchen, Germany) overnight. Following day, digested tissue was centrifuged at 3000 g for 5 minutes. Supernatant was discarded and pellet of cells was resuspended in cell culture media containing DMEM and 10 % fetal bovine serum. Cells were plated into 6 well plates and grown in standard conditions at 37 °C and 5 % CO₂. After reaching confluency, cells were trypsinized and transferred into larger, 25 cm² dish, where they were grown again until confluency. Confluent cells from 25 cm² dish were trypsinized, centrifuged at 3000 g for 5 minutes, washed with 1 ml of PBS, centrifuged again and finally resuspended in 1 ml of sterile PBS.

Cell injection

Two to three millions of cells were placed in the syringe and transported to the orthopaedic veterinarian. Dogs were again anaesthetized. Cells were injected directly into one of the osteoarthritic knees, while sterile PBS was injected as placebo into the other knee. Prior to application, synovial fluid was collected from both knees, and examined for appearance, total protein, albumins, total cell count, alkaline phosphatase (ALP) and alanine transaminase (ALT).

Clinical evaluation

All dogs were examined 3, 6 and 12 months after stem cell application. During clinical examination, differences in lameness, joint pain, signs of inflammation or infection, neurologic deficit and any other diseases were observed. At the same time the owners were asked about their observations.

Radiography

Radiographs of all dogs were taken 6 and 12 months after the treatment and examined for any signs of improvement or progression of osteoarthritis and any signs of infection or other pathologic bone conditions.

Synovial fluid analyses

Synovial fluid was collected at the time of stem cell injection and 1 year after the treatment and also examined for any signs of osteomalacia, infection, inflammation, bone destruction.

Results

Clinical evaluations

All dogs were examined 3, 6 and 12 months after treatment. Before treatment, 7 dogs showed signs of limping scored by 2 according to Brunnberg scale, and 3 dogs showed limping scored by 3. One year after treatment, limping was improved in all but one dog and results for all individual dogs are presented in figure 1.

Radiographic evaluations

Dogs were subjected to radiography before treatment and at 6 and 12 months after the treatment (Figure 2). Although there was no significant improvements in the size of osteophytes in the joints observed on autoradiographs after 12 months, in all (10 out of 10) joints that received placebo treatment there was worsening of the joint status, while in 7 out of 10 joints treated with mesenchymal stem cells the radiographic score in the joints remained the same, suggesting that stem cell treatment did stall the progress of osteoarthritis. The difference was statistically significant using chi-square test with $p < 0.001$ (Table 1).

Synovial fluid examination

Concentration of total protein content, albumins, alkaline phosphatase and alanine aminotransferase did not differ significantly between treated and untreated joints, and before and after the treatment (Fig 3a and 3 b), suggesting that stem cell application did not cause any long

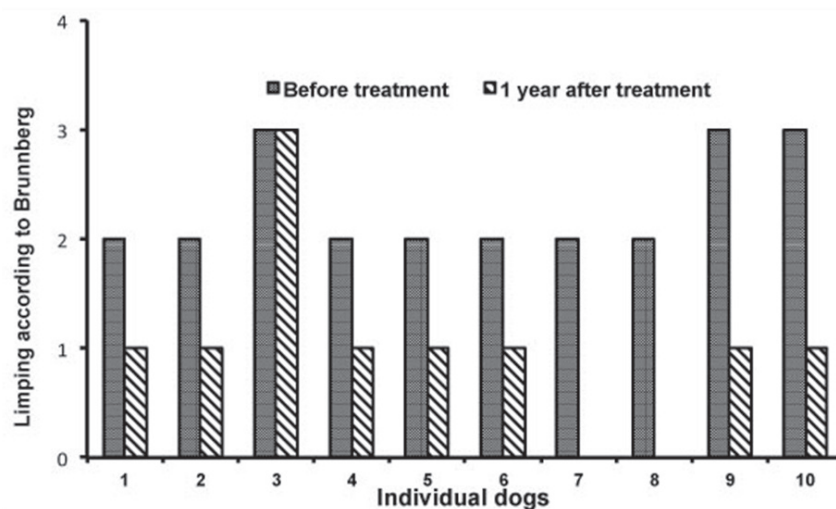


Figure 1: Limping in dogs before treatment and one year after treatment scored according to Brunnberg scale. In all but one dog significant improvement in limping was observed

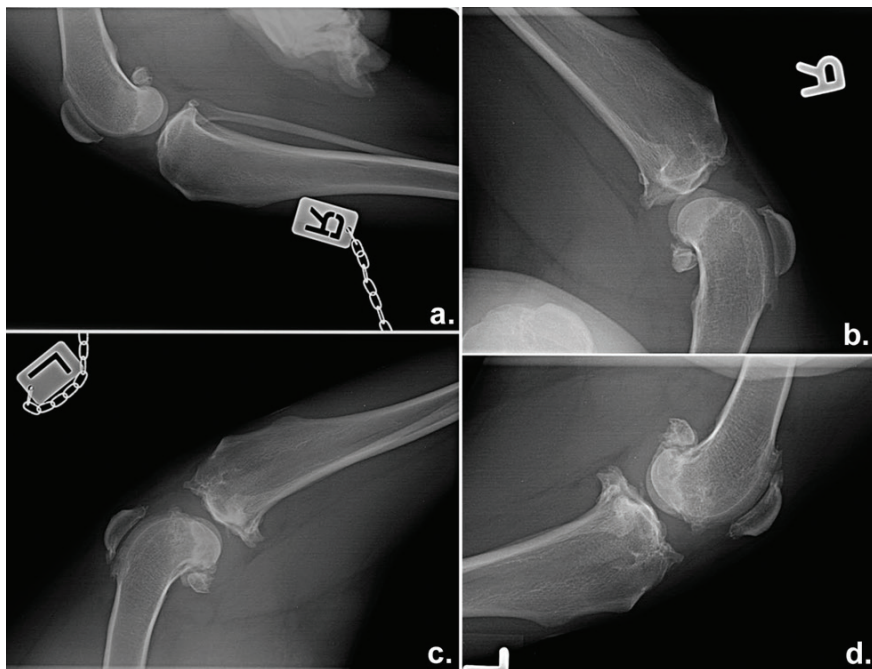


Figure 2: Representative X-ray photographs of both knees from same dog before treatment (a, c) and 12 months after treatment (b, d). In the placebo treated knee, osteoarthritis worsened during one year significantly (a - before treatment, b - 12 months after treatment) while in MSC treated knee, the osteoarthritis did not progress (c - before treatment, d - 12 months after treatment). Similar situation was observed in seven out of 10 dogs

Table 1: Autoradiographic evaluation revealed that size of osteophytes increased in all placebo treated joint while in 7 out of 10 joints treated with MSC the osteoarthritis did not progress (*Chi² p < 0.001)

Radiographic evaluation before and 12 months after treatment	MSC treated joint	Placebo
Same	7*	0
Worse	3*	10

lasting inflammation of the joints. Similarly, total number of cells per ml was similar between treated and untreated joints and before and 1 year after treatment (Fig. 3c). All values were within the physiological levels for synovial fluid.

Discussion

Osteoarthritis is debilitating disease that affects many dogs and could affect different joints (1, 2). Currently, there is no treatment for this disease. In the present study, we have therefore evaluated clinical and autoradiographic outcomes of mesenchymal stem cell treatment in dogs, suffering from osteoarthritis in both knees.

Osteoarthritis is very prevalent in older dogs, where it can affect up to 80 % of dogs over 8 years old, but it could also affect much younger dogs (3). Although some of the symptoms of osteoarthritis can be eased with pain relief therapy, the disease is currently incurable and presents an important

financial and psychological burden for dog owners. Current methods for managing osteoarthritis include classical pain relief and nonsteroidal antiinflammatory drugs, often combined with functional foods, physical therapy and alternative therapies such as acupuncture. In severe cases, surgery and joint replacement could be also performed, but this is very costly procedure and therefore not suitable for average dog owner (2).

Stem cells from different sources have attracted a lot of attention in recent years due to their potential use in regenerative medicine. Several studies, both preclinical and clinical in dogs and also in humans have provided some evidence that mesenchymal stem cells might have beneficial effects in the treatment of osteoarthritis (9-11, 14). However, there are still very few clinical studies that would confirm positive effects of mesenchymal stem cells in clinical patients. In the present study mesenchymal stem cells obtained from adipose tissue of dogs, affected by severe

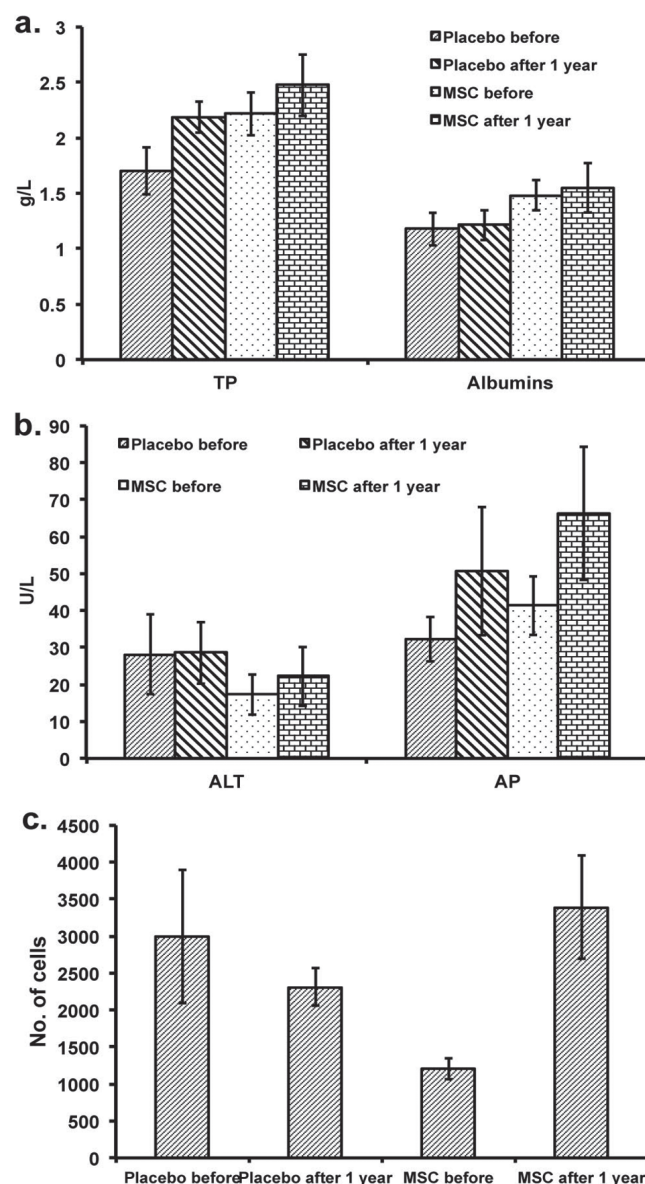


Figure 3: Total protein content (TP) and albumins (a), alanine aminotransferase (ALT) and alkaline phosphatase activity (AP; b) and number of cells (c) were similar in MSC treated and placebo joints before and after the treatment, suggesting that MSC application did not cause any long lasting inflammation of the joints. All values were within the physiological levels for synovial fluid

osteoarthritis, were used for the treatment of dogs with bilateral osteoarthritis in the knee. Adipose tissue derived stem cells were chosen as they are easily obtainable in large quantities from adipose tissue of dogs, affected by osteoarthritis.

Clinical evaluations of our patients revealed significant improvement in limping as assessed by Brunneberg scale (15). Interestingly, the first clinical signs of improvement were noticeable only 2 to 3 months after treatment, and were very obvious one year after treatment. Although some owners reported improvements much earlier, this was not confirmed during clinical examination and is presumably placebo effect on dogs' owners. Interestingly, although there was a marked clinical improvement, autoradiographic

evaluations 12 months after the treatment did not reveal improvements in the joint structure in any of the treated knees. However, in comparison to untreated joints, the stem cell therapy seemed to slow down or even stopped degenerative processes, as in 7 out of 10 treated knees, the autoradiographic evaluation did not show any progression of disease while in all 10 knee joints receiving placebo treatment, osteoarthritis have significantly progressed. Interestingly, 4 out of 10 dogs came to the clinic again 18 months after the treatment and underwent x-ray imaging again. In all four dogs, there was an improvement of joint surface (significant reduction of osteophytes) in treated joints only.

Although several studies have shown beneficial effects of mesenchymal stem cell treatments in osteoarthritis in different species, it is not known how is this beneficial effect achieved. Several studies, mostly in rodents, have tried to track mesenchymal stem cells after injection into affected joints and most studies could not find any evidence of stem cells engrafting into the cartilage or bone tissue (16-20), although some engrafting cells were detected in synovial membranes and menisci in rabbits and goats (16, 19). Dessando et al. (16) have shown that in rabbits, joints treated with MSC had reduced expression of tumour necrosis factor alpha, an inflammatory cytokine, and reduced expression of matrix metalloproteinase 1. Similarly, studies in mice (21), goats (19) and horses (22) have shown anti-inflammatory effects of MSC in osteoarthritic joints. Therefore, it is currently thought that mesenchymal stem cells effect in osteoarthritis might be more due to their anti-inflammatory effects, rather than regenerative capabilities. This is supported by our study as we did detect significant clinical improvement in dogs, but that was not, at least one year after the treatment, accompanied by the improvement in the structure of the joints.

As described before, results of our analysis of the inflammatory response following the application of MSC suggest that the application of stem cells did not cause any long-lasting inflammation in the joint. Nevertheless we have only used synovial fluid as a sample for the analysis due to the non-invasiveness of the collection method, as our study was done on owned dog patients and any more invasive procedures would be unethical. Therefore, the possible effect of stem cells on the local inflammation and concentrations of the immune system mediators in the synovial membranes was not examined. However, there is a substantial body of evidence showing that the secretom of mesenchymal stem cells does reduce the local inflammation in the synovial membrane and in the extracellular matrix of the cartilage. The mediators involved in this process are thought to be Indolamin-2,3-dioxigenase-1, Interleukin 6, Tumor factor alpha and Tumor factor beta (23-25). These mediators would serve as good markers of local inflammatory response for further investigation.

Some studies have reported only short to medium term beneficial effects of MSC treatment in osteoarthritis (26, 27). However, in our study, we

have found that beneficial effect of MSC treatment was prolonged and was evident by clinical examination at least a year after the treatment, and even more interestingly, the improvement of the cartilage appeared in some dogs only 18 months after the treatment. We were not able to trace the cells in the dogs, as all dogs were clinical patients and not laboratory dogs, and therefore we could not use labeled cells. Therefore, we do not know if there was an engraftment of MSC in our study, although prolonged effect of MSC does suggest that stem cells must have engrafted into some tissues. However, this does not mean that stem cells had to engraft into the cartilage and differentiate into cartilage tissue, perhaps, as suggested by previous studies, MSC engraft only in soft tissues but nevertheless secrete anti-inflammatory substances and trophic factors that contribute to the healing of the joint from these tissues.

Presented blind placebo study of bilateral knee osteoarthritis shows that MSC treatment had beneficial effect in almost all treated dogs with the improvement of clinical signs. Although there was no evident improvement in radiographs 1 year after the treatment, it appears that stem cell treatment did stall the progress of osteoarthritis as in all joints receiving placebo, severity of osteoarthritis progressed in one year while in majority of MSC treated joints there was no progression of osteoarthritis. This study therefore suggests a positive effect of MSC treatment for managing osteoarthritis in dogs.

Acknowledgment

This study was supported by ARRS (Slovenian research agency) grant P4-0053. K.C. and G.M. are partial owners of Animacel biotehnologija ltd.

References

1. Rychel JK. Diagnosis and treatment of osteoarthritis. *Top Companion Anim Med* 2010; 25(1): 20-5.
2. Sanderson RO, Beata C, Flipo RM, Genevois JP, Macias C, Tacke S et al. Systematic review of the management of canine osteoarthritis. *Vet Rec* 2009; 164(14): 418-24.
3. Johnston SA. Osteoarthritis. Joint anatomy, physiology, and pathobiology. *Vet Clin North Am Small Anim Pract.* 1997; 27(4): 699-723.

4. Fortier LA, Travis AJ. Stem cells in veterinary medicine. *Stem Cell Res Ther* 2011; 2(1): e9 (6 pp.) <http://stemcellres.biomedcentral.com/articles/10.1186/scrt50>
5. Koh S, Piedrahita JA. From “ES-like” cells to induced pluripotent stem cells: a historical perspective in domestic animals. *Theriogenology* 2014; 81(1):103–11.
6. Sylvester KG, Longaker MT. Stem cells: review and update. *Arch Surg* 2004; 139(1): 93–9.
7. Whitworth DJ, Banks TA. Stem cell therapies for treating osteoarthritis: prescient or premature? *Vet J* 2014; 202(3): 416–24.
8. Minter DM, Marra KG, Rubin JP. Adipose stem cells: biology, safety, regulation, and regenerative potential. *Clin Plast Surg* 2015; 42(2): 169–79.
9. Arnhold S, Wenisch S. Adipose tissue derived mesenchymal stem cells for musculoskeletal repair in veterinary medicine. *Am J Stem Cells*. 2015; 4(1): e1-12. <https://www.ncbi.nlm.nih.gov/pmc/articles/PMC4396154/>
10. Black LL, Gaynor J, Adams C, et al. Effect of intraarticular injection of autologous adipose-derived mesenchymal stem and regenerative cells on clinical signs of chronic osteoarthritis of the elbow joint in dogs. *Vet Ther* 2008; 9(3): 192–200.
11. Black LL, Gaynor J, Gahring D, et al. Effect of adipose-derived mesenchymal stem and regenerative cells on lameness in dogs with chronic osteoarthritis of the coxofemoral joints: a randomized, double-blinded, multicenter, controlled trial. *Vet Ther* 2007; 8(4): 272–84.
12. Nixon AJ, Dahlgren LA, Haupt JL, Yeager AE, Ward DL. Effect of adipose-derived nucleated cell fractions on tendon repair in horses with collagenase-induced tendinitis. *Am J Vet Res* 2008; 69(7): 928–37.
13. Patruno M, Martinello T. Treatments of the injured tendon in veterinary medicine: from scaffolds to adult stem cells. *Histol Histopathol* 2014; 29(4): 417–22.
14. Vilar JM, Batista M, Morales M, et al. Assessment of the effect of intraarticular injection of autologous adipose-derived mesenchymal stem cells in osteoarthritic dogs using a double blinded force platform analysis. *BMC Vet Res* 2014; 10: e143 (7 pp.) <http://bmcvetres.biomedcentral.com/articles/10.1186/1746-6148-10-143>
15. Brunnberg L, Johnson KA. Diagnosing lameness in dogs. Oxford : Blackwell Science, 2001: uporab. str. ?
16. Desando G, Cavallo C, Sartoni F, et al. Intra-articular delivery of adipose derived stromal cells attenuates osteoarthritis progression in an experimental rabbit model. *Arthritis Res Ther* 2013; 15(1): R22 (15 pp.) <http://arthritis-research.biomedcentral.com/articles/10.1186/ar4156>
17. Hatsushika D, Muneta T, Horie M, Koga H, Tsuji K, Sekiya I. Intraarticular injection of synovial stem cells promotes meniscal regeneration in a rabbit massive meniscal defect model. *J Orthop Res* 2013; 31(9): 1354–9.
18. Horie M, Choi H, Lee RH, et al. Intra-articular injection of human mesenchymal stem cells (MSCs) promote rat meniscal regeneration by being activated to express Indian hedgehog that enhances expression of type II collagen. *Osteoarthritis Cartilage* 2012; 20(10): 1197–207.
19. Murphy JM, Fink DJ, Hunziker EB, Barry FP. Stem cell therapy in a caprine model of osteoarthritis. *Arthritis Rheum* 2003; 48(12): 3464–74.
20. ter Huurne M, Schelbergen R, Blattes R, et al. Antiinflammatory and chondroprotective effects of intraarticular injection of adipose-derived stem cells in experimental osteoarthritis. *Arthritis Rheum* 2012; 64(11): 3604–13.
21. Diekman BO, Wu CL, Louer CR, et al. Intra-articular delivery of purified mesenchymal stem cells from C57BL/6 or MRL/MpJ superhealer mice prevents posttraumatic arthritis. *Cell Transplant* 2013; 22(8): 1395–408.
22. Frisbie DD, Kisiday JD, Kawcak CE, Werpy NM, McIlwraith CW. Evaluation of adipose-derived stromal vascular fraction or bone marrow-derived mesenchymal stem cells for treatment of osteoarthritis. *J Orthop Res* 2009; 27(12): 1675–80.
23. Lee DH, Sonn CH, Han SB, Oh Y, Lee KM, Lee SH. Synovial fluid CD34(-) CD44(+) CD90(+) mesenchymal stem cell levels are associated with the severity of primary knee osteoarthritis. *Osteoarthritis Cartilage* 2012; 20(2): 106–9.
24. Schelbergen RF, van Dalen S, ter Huurne M, et al. Treatment efficacy of adipose-derived stem cells in experimental osteoarthritis is driven by high synovial activation and reflected by S100A8/A9 serum levels. *Osteoarthritis Cartilage* 2014; 22(8): 1158–66.
25. van Buul GM, Villafuertes E, Bos PK, et al. Mesenchymal stem cells secrete factors that inhibit inflammatory processes in short-term osteoarthritic synovium and cartilage explant culture. *Osteoarthritis Cartilage* 2012; 20(10): 1186–96.
26. Vilar JM, Morales M, Santana A, et al. Con-

trolled, blinded force platform analysis of the effect of intraarticular injection of autologous adipose-derived mesenchymal stem cells associated to PRGF-Endoret in osteoarthritic dogs. *BMC Vet Res* 2013; 9: e131 (6 pp.) <http://bmcvetres.biomed-central.com/articles/10.1186/1746-6148-9-131>

27. Wilke MM, Nydam DV, Nixon AJ. Enhanced early chondrogenesis in articular defects following

arthroscopic mesenchymal stem cell implantation in an equine model. *J Orthop Res* 2007; 25(7): 913–25.

28. Brunnberg L. Myeloperoxidase, a highly sensitive and specific pain indicator in osteoarthritis. In: *Hill's European Symposium on Osteoarthritis and Joint Health*. Genova, 2005: 20–5.

SLEPA PLACEBO RAZISKAVA ZDRAVLJENJA VNETJA KOLENSKEGA SKLEPA Z MEZENHIMSKIMI MATIČNIMI CELICAMI

L. Mohoric, B. Zorko, K. Ceh, G. Majdic

Povzetek: Zdravljenje z mezenhimijskimi matičnimi celicami v zadnjih letih priteguje veliko pozornosti in tudi razprav v veterinarski medicini. V predstavljeni raziskavi smo preverjali učinkovitost zdravljenja z matičnimi celicami pri vnetju kolenskih sklepov pri psih. V raziskavo je bilo vključenih 10 psov z vnetjem obeh kolenskih sklepov. Psom je bil odvzet košček maščobnega tkiva, iz katerega smo osamili in pripravili mezenhimijske matične celice. Dva do tri milijone celic v sterilnem fosfatnem pufru smo nato injicirali v eno obolelo koleno, medtem ko smo v drugo obolelo koleno injicirali samo fosfatni pufer kot placebo. Lastniki psov niso vedeli, v katero koleno so psi prejeli celice in v katero koleno placebo. Psi so bili klinično pregledani 3, 6 in 12 mesecev po zdravljenju. Sinovialno tekočino smo iz sklepa odvzeli ob vnosu matičnih celic ter 12 mesecev po zdravljenju. Ob začetku zdravljenja ter 6 in 12 mesecev po zdravljenju smo naredili tudi rentgenske posnetke obeh kolenskih sklepov. Od 10 zdravljenih psov smo po enem letu pri devetih opazili značilno izboljšanje šepanja po enem letu. Rentgenske slike po enem letu sicer niso pokazale izboljšanja sklepne površine, vendar pa pri 7 od 10 zdravljenih sklepov ni prišlo do napredovanja bolezni, medtem ko je pri vseh 10 nezdravljenih sklepih prišlo do značilnega poslabšanja sklepne površine (večje število oziroma velikost izrastkov). Analiza sinovialne tekočine ob začetku zdravljenja ter eno leto po zdravljenju ni pokazala statistično značilnih razlik v preiskovanih parametrih, kar kaže, da v sklepih ni prišlo do vnetnih sprememb kot posledica zdravljenja z mezenhimijskimi matičnimi celicami. Rezultati te raziskave kažejo pomembne učinke mezenhimijskih matičnih celic pri zdravljenju vnetja sklepov pri psih in potrjujejo, da je takšno zdravljenje primeren način zdravljenja te nevarne kronične bolezni psov.

Ključne besede: pes; vnetje sklepov; koleno; mezenhimijske matične celice