

LISTERIA MONOCYTOGENES SEPTICAEMIA IN A FOAL

Tina Pirš¹, Irena Zdovc¹, Mitja Gombač², Tanja Švara², Polona Juntos², Modest Vengušt³

Addresses of authors: ¹ Institute of Microbiology and Parasitology, ² Institute of Pathology, Administrative and Forensic Veterinary Medicine, ³ Clinic for Reproduction and Horses, Veterinary Faculty, Ljubljana, Gerbičeva 60, 1000 Ljubljana, Slovenia

* Corresponding author, E-mail: tina.pirs@vf.uni-lj.si

Summary: We describe *Listeria monocytogenes* septicaemia in a Slovenian warm-blood 3-day old filly. When admitted to the hospital, the foal was weak and severely dehydrated. Due to poor response to therapy and grave prognosis, the foal was euthanized. Postmortem examination was performed and significant findings included multifocal hepatitis, diffuse enteritis and pulmonary and spleen haemorrhages. The histopathological examination revealed pyogranulomatous hepatitis, mononuclear meningitis, acute septic embolic pneumonia, acute catarrhal enteritis as well as congestion and acute haemorrhages in most of examined tissues. *Listeria monocytogenes* was isolated on primary culture from the liver, spleen, kidney, lung, intestine and brain, and was therefore considered as the cause for the septicaemia in this foal. *L. monocytogenes* septicaemia in foals is rarely diagnosed, and the present report is, to our knowledge, the first to describe *L. monocytogenes* septicaemia in a foal in Slovenia. Despite being rare, a definitive diagnosis based on post-mortem examination and bacteriological culture is important because it allows preventing transmission of the disease and/or development of healthy carriers. This may be of particular importance in herds where several foals are expected to be born.

Key words: Listeria infection-diagnosis; *Listeria monocytogenes*; sepsis; horses

Introduction

Listeriosis is an infectious disease caused by bacteria of the genus *Listeria*. These Gram-positive and facultative anaerobic rods are ubiquitous in the nature; however, especially its presence in poorly ensiled feed has always been the cause of great concern in the animal husbandry. The genus *Listeria* comprises six species, of which only two are pathogenic. *Listeria monocytogenes* is responsible for most infections in humans and animals. However, *L. ivanovii* may cause the significant numbers of cases of disease in domestic animals, especially in sheep (1). All domestic animals can be infected with *L. monocytogenes*, although sheep, cattle, goats and chickens are considered the most susceptible species (2). Clinical forms of listeriosis include encephalitis, abortion and, relatively uncommon, septicaemia in neonates (3, 4). In septicaemic listeriosis, small necrotic foci are often found in liver and other abdominal organs (5).

Listeriosis in horses is rare (6, 7, 8, 9, 10, 11, 12, 13, 14). Even less reports are available for *L. monocytogenes* in foals. In 1943, Grini reported *L. monocytogenes* septicaemia in the equine neonate (6). Since then of *L. monocytogenes* septicaemia in equine neonates have been reported worldwide. In other reports, *L. monocytogenes* was isolated from a group of six ponies with fever, colic and jaundice (7), an aged mare and a two-year old foal with septicaemia (8), a three-week old foal with diarrhoea (9), two foals with necrotizing hepatitis and septicaemia (10), a six-day old foal with diarrhoea (11) and three foals with septicaemia and signs of diarrhoea and neurological disease (12). *Listeria monocytogenes* was also described as a cause of meningitis in a one-month old foal with combined immunodeficiency (13) and as a cause of abortion of a near-term equine foetus (14). Only two of the above-mentioned cases had a successful outcome (9, 12). All other diagnoses, including ours, were made post-mortem.

In Slovenia listeriosis most commonly occurs in ruminants (15). This is the first report of *L. monocytogenes* infection in a foal in Slovenia.

Material and methods

Case history and clinical signs

A 3-day-old Slovenian thoroughbred filly was presented to the Equine hospital of the Clinic for reproduction and horses at the Veterinary Faculty Ljubljana for evaluation of generalised weakness. Parturition was normal. Initially, in the presence of owners, the mare allowed the foal to nurse. However, few hours later it completely rejected the foal. The foal was then bottle-fed.

On physical examination, the foal was weak and severely dehydrated. Rectal temperature of 37.2°C, pulse rate of 92 beats per minute and respiratory rate of 20 breaths per minute were within normal limits. The mucous membranes were pale and the capillary refill time prolonged on 3 seconds. Despite intermediate treatment with intravenous polyionic fluids (lactated Ringer's solution) and intravenous antibiotic (Ceftiofur Sodium), the foal's condition rapidly deteriorated and it had to be euthanised soon after admission. Complete blood count and serum biochemistry were available only after euthanasia. Significant abnormalities included severe leucopenia, increased blood urea nitrogen (BUN) and creatinine, hypoalbuminaemia and hypoglobulinaemia.

Clinical examination of the mare did not show significant abnormalities. Mild nasal discharge was the only complaint reported by the owners regarding mare's health status during pregnancy. There was another pregnant mare present on the premises that did not show signs of any kind of disease for the past year. Animals did not travel from the premises and did not come in contact with other horses. Animals did not undergo preventive vaccinations and were dewormed every six months.

Gross pathology and histopathology

Blocks of liver, kidneys, lung, heart, stomach, intestines, mesenteric lymph nodes, adrenal gland and brain were fixed in 10 % buffered formalin and paraffin-embedded for histopathology. 4 µm thick tissue sections were then deparaffinised, stained with hematoxylin and eosin (HE) and examined under a light microscope.

Bacteriological examination

Samples of liver, spleen, lungs, intestines and brain for bacteriological examination were collected during necropsy. The samples were inoculated on nutrient agar (Oxoid, Hampshire, UK) supplemented with 5% of sheep blood and Drigalski agar (Oxoid) and incubated at 37°C for 24 hours. In addition, brain stem tissue was inoculated into selective enrichment media half Fraser and Fraser broth (Oxoid), and onto selective differential solid media Oxford and Palcam Agar (Oxoid). Bacteria were Gram stained and tested for catalase activity (Difco-BBL, Maryland, USA). The biochemical characteristics were evaluated using API *Listeria* (bioMerieux, Marcy l'Etoile, France) according to the manufacturer's instructions. CAMP reaction was determined on blood agar with *Staphylococcus aureus* (ATCC 25923) and *Rhodococcus equi* (CAPM 6312). Testing for motility was performed in tryptic soy broth (Biolife, Milan, Italy), which was incubated at 20°C and 37°C. Diagnosis was confirmed with AccuProbe *Listeria monocytogenes* hybridisation assay (GenProbe, San Diego, USA). The strain was serologically determined with commercial antisera (Bacto-*Listeria* O Antiserum, Difco-BBL). Susceptibility to the following antibiotics was tested by disc diffusion method on Mueller-Hinton agar (Merck, Darmstadt, Germany) with discs: amikacin, gentamicin, oxytetracycline, penicillin, trimethoprim-sulphamethoxazole, cefalexin, ceftriaxone, cefoperazone (all Difco-BBL) and ceftiofur (Rosco, Taastrup, Denmark). The mare's vaginal swab was inoculated onto blood agar and half Fraser and Fraser broth (Oxoid). The presence of specific antibodies in the mare's serum was tested by complement fixation assay (Institut Virion Serion GmbH, Wurzburg, Germany).

Results

Post-mortem findings

The foal was emaciated and dehydrated. The findings included acute diffuse gastroenteritis and typhlocolitis with enlarged and congested mesenteric lymph nodes, obstipation of large intestine with accumulated dry intestine content, congestion, disseminated haemorrhages and oedema of the lung and enlarged spleen due to severe congestion. Numerous petechial haemor-

Figure 1: Cerebellar meninges, foal. Mononuclear cell infiltrate and congested blood vessels. HE×400

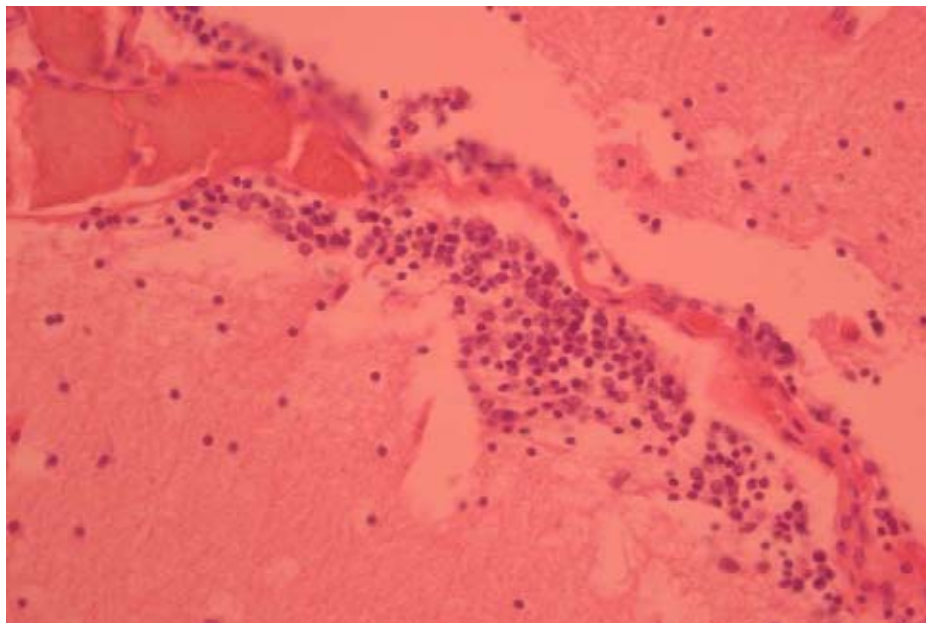
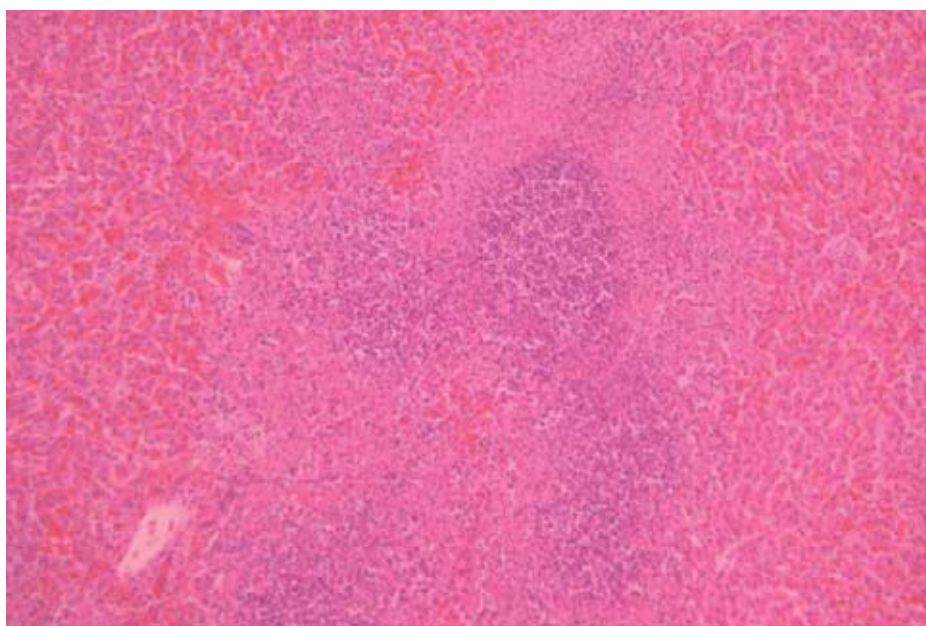


Figure 2: Liver, foal. Pyogranulomatous hepatitis. HE×400



rhages were found on serosal surfaces of the lung and spleen. Liver was congested and many randomly distributed white, clearly demarcated spots measuring up to 3 mm in diameter were visible on the surface and on the cross section. Right heart ventricle was dilated and congestion of the kidneys, adrenal gland, brain and meninges were also noted.

Histopathology

Brain was oedematous, blood vessels were congested and some were filled with large bacter-

ial colonies and fibrinous clots. In cerebellar meninges, mononuclear cell infiltrate was found around congested blood vessels (Figure 1). Multiple pyogranulomatous inflammatory lesions, characteristic for listeriosis were distributed randomly in the parenchyma of hepatic lobules (Figure 2). Lungs were congested, atelectatic and oedematous with disseminated acute haemorrhages and accumulations of neutrophils in alveolar spaces, many pulmonary blood vessels were filled with rod-shaped bacteria. Lesions were diagnosed as an acute embolic pneumonia. Other lesions reflected gross pathology lesions:

catarrhal desquamative enteritis with hyperplastic Peyers patches, lymphopenic and hyperaemic mesenteric lymph nodes, reactive hyperplasia, extramedullar haematopoiesis, congestion and multifocal haemorrhages of the spleen, multifocal cortical haemorrhages of adrenal gland and kidney cortex.

Bacteriological examination

Bacteriological cultures of the organs on blood agar yielded abundant growth of smooth transparent colonies, 1-2 mm in diameter, with narrow zone of beta-haemolysis. Gram stained cultures revealed short round-ended Gram-positive rods. The obtained numerical profile in API Listeria system was 6510, which is consistent with *L. monocytogenes*. *L. monocytogenes* produces haemolysin listeriolysin O, which enhanced the effect of *S. aureus* beta-toxin. Weak CAMP effect with equi factor of *R. equi* was also observed (16, 17, 18). The culture incubated in tryptic soy broth at 20°C showed the characteristic tumbling motility end-over-end. In 37°C broth culture the bacteria were not motile. After confirmation by standard cultural method, the strain was positive for *L. monocytogenes* in nucleic acid hybridisation assay. It was serologically identified as serotype 1. We also isolated Listeria from selective enrichment medium. The colonies had typical morphology on solid selective differential media, so further identification was not performed as *L. monocytogenes* had already been confirmed directly. The strain was sensitive to amikacin, gentamicin, oxytetracycline and trimethoprim-sulphamethoxazole, and intermediate sensitive to penicillin. However, the strain was resistant to cefalexin, ceftriaxone, cefoperazone, and ceftiofur.

The bacteriological examination of the mare's swab and the complement fixation assay were both negative.

Discussion

Gross and histopathology findings i.e. pyogranulomatous hepatitis, mononuclear meningitis, pneumonia, haemorrhages in the spleen and other organs and enlarged lymph nodes consistent with septicaemia and isolation of the *L. monocytogenes* in a pure culture from different tissues strongly suggest that *L. monocytogenes* was the etiologic agent for the disease in this foal. Severe

suppurative bronchopneumonia with necrotizing vasculitis and microabscesses in liver caused by *L. monocytogenes* was described previously in a 6-day-old foal (11).

Listeria monocytogenes is ubiquitous and, although non-sporing, very resistant in the environment. Many healthy individuals are intestinal carriers. Carriage rate for animals depends on the species and is a little higher rate during indoor season, as compared to animals on pasture (19). Weber et al. found *L. monocytogenes* in 4.8% of 400 faecal samples of healthy horses (20). The route of infection is mainly by ingestion, through the nasal mucosa, conjunctiva or wound. Infection can also be transmitted by aerogenic route, transplacentally or to foals via the mare's milk (9, 11). In the case presented herein, we were not able to determine the source of infection. The mare's milk was not available any more, and the vaginal swab bacteriology and the complement fixation assay were negative. The foal did not have any contact with ruminants and there were no history of diseased horses or other animals on the farm. The animals had not been fed silage, the most frequent source of feed-borne listeriosis. In situation when hosts are immunosuppressed due to stress, primary disease or infection, pregnancy, immunodeficiency disorder or high infective dose, clinical symptoms can develop. The most likely source of infection in this case may have been the contaminated environment and inadequate passive immunity. In fact, the passive transfer of immunity was probably not adequate in this foal with the serum globulin concentration of 19g/l (normal >20g/l). Serum IgG concentration, unfortunately, was not specifically determined.

In general, isolates of *L. monocytogenes*, as well as strains of other *Listeria* spp., are susceptible to a wide range of antibiotics, but show a high natural resistance to cephalosporins, especially to those that are broad spectrum (21). In our case, the antibiotic of choice was ceftiofur as the exact diagnosis could not be made by clinical observation alone. Anyway, the foal had been euthanised before possible effects of the therapy could be seen.

This report is the first to describe *L. monocytogenes* septicaemia in a foal in Slovenia. Although the disease is rare in horses, the possibility of *L. monocytogenes* infection should always be considered in cases expressing clinical signs such as those presented with this case. It is important to

define the diagnosis and etiology of the disease as, in the case of *L. monocytogenes*, interspecies disease transmission and/or development of healthy carriers can occur. This may be of particular importance in herds where we expect several foal to be born.

References

1. McLauchlin J, Jones D. Erysipelothrix and Listeria. In: Balows A, Duerden BI, eds. Topley and Wilson's microbiology and microbial infection, systematic bacteriology. Vol. 2. London: Arnold, 1999: 692.
2. Wesley IV. Listeriosis in animals. In: Ryser ET, Marth EH, eds. Listeria, listeriosis, and food safety. New York, Basel: Marcel Dekker, 1999: 39-40.
3. Low C, Linklater K. Listeriosis in sheep. In Pract 1985; 7: 66-7.
4. Low JC, Donachie W. A review of Listeria monocytogenes and listeriosis. Vet J 1997; 153: 9-29.
5. Quinn PJ, Carter ME, Markey B, Carter GR. Clinical veterinary microbiology. London: Mosby International, 2002: 170-4.
6. Grini O. Listerella monocytogenes som assak til septico-pyemi hos foll. Norsk Vet Tidsskr 1943; 55: 57-104.
7. Emerson FG, Jarvis AA. Listeriosis in ponies. J Am Vet Med Assoc 1968; 152: 1645-6.
8. McCain CS, Robinson M. Listeria monocytogenes in the equine. In: Proceedings of the 18th Annual Meeting of the American Association of Veterinary Laboratory Diagnosticians. Portland, 1975: 257-61.
9. Wallace SS, Hathcock TL. Listeria monocytogenes septicemia in a foal. J Am Vet Med Assoc 1995; 207: 1325-6.
10. Laroche D, Mysore J, Walker R. Necrotizing hepatitis in foals with a Listeria monocytogenes septicemia. In: 42nd Annual Meeting of American Association of Veterinary Laboratory Diagnosticians, 1999: 104.
11. Wilkins PA, Marsh PS, Acland H, Del Piero F. Listeria monocytogenes septicemia in a thoroughbred foal. J Vet Diagn Invest 2000; 12(2): 173-6.
12. Jose-Cunilleras E, Hinchcliff KW. Listeria monocytogenes septicemia in foals. Equine Vet J 2001; 33(5): 519-22.
13. Clark EG, Turner AS, Boysen DG, Rouse BT. Listeriosis in an Arabian foal with combined immunodeficiency. J Am vet med Ass 1978; 172: 363-6.
14. Welsh RD. Equine abortion caused by Listeria monocytogenes serotype 4. J Am Vet Med Assoc 1983; 182: 291.
15. Zdovc I, Mehle J. Current situation of animal listeriosis in Slovenia. In: Proceedings of ISOPOL XIV. Mannheim, 2001: 93.
16. Fraser G. The effect on animal erythrocytes of diffusible substances produced by bacteria. J Pathol Bacteriol 1964; 88: 43-53.
17. Skalka B, Smola J, Elischerova K. Routine test for in vitro differentiation of pathogenic and apathogenic Listeria monocytogenes strains. J Clin Microbiol 1982; 15: 503-7.
18. Prescott JF, Lastra M, Barksdale L. Equi factors in the identification of Corynebacterium equi Magnusson. J Clin Microbiol 1982; 16: 988-90.
19. Iida T, Kanzaki M, Maruyama T, Inoue S, Kaneuchi C. Prevalence of Listeria monocytogenes in intestinal contents of healthy animals in Japan. J Vet Med Sci 1991; 53: 873-5.
20. Weber A, Potel J, Schafer-Schmidt, R, Prell A, Datzmann C. Studies on the occurrence of Listeria monocytogenes in fecal samples of domestic and companion animals. Zentralbl Hyg Umweltmed 1995; 198(2): 117-23.
21. Hof H, Nichterlein T, Kretschmar M. Management of listeriosis. Clin Microbiol Rev 1997; 10: 345-57.

LISTERIOZNA SEPSA PRI ŽREBIČKI

T. Pirš, I. Zdovc, M. Gombač, T. Švara, P. Juntos, M. Vengušt

Povzetek: Opisali smo listeriozno sepsu pri tridnevni žrebički slovenske toplokrvne pasme. Žrebička je bila ob sprejetju na kliniko slabotna in močno dehidrirana. Kljub terapiji se ji je zdravstveno stanje slabšalo, zato je bila potrebna evtanazija. Najočitnejše spremembe, ugotovljene pri raztelesbi, so bile multifokalni hepatitis, difuzno vnetje črevesja ter krvavitve po pljučih in vranici. S patohistološko preiskavo smo ugotovili piogranulomatozni hepatitis, mononuklearni meningitis, akutno septično embolično pljučnico, akutni kataralni enteritis ter polnokrvnost in akutne krvavitve v večini pregledanih tkiv. Iz jeter, vranice, ledvic, pljuč, črevesa in možganov smo izolirali bakterijo *Listeria monocytogenes*, ki smo jo določili kot povzročitelja sepse pri tej žrebički. Listeriozna sepsa je pri žrebetih le redko diagnosticirana in po nam dostopnih podatkih je to prvi opisan primer v Sloveniji. Čeprav je listeriozna sepsa redka, je povzročitelja pomembno ugotoviti, saj tako lahko preprečimo širjenje bolezni in/ali nastanek zdravih klicenoscev, kar je še posebej pomembno v čredah, kjer pričakujemo večje število novorojenih žrebet.

Ključne besede: Listerija infekcije-diagnostika; *Listeria monocytogenes*; sepsa; konji