



Early prosthetic rehabilitation of severe oligodontia with implant-retained overdenture: A case report

Zgodnja protetična oskrba bolnika s hudo obliko oligodontije z implantatno podprto totalno protezo – prikaz primera

Sonja Žarković Gjurin,¹ Nataša Ihan Hren,² Tanja Tomažević,³ Čedomir Oblak¹

Abstract

Background: Ectodermal dysplasia is a rare hereditary disease, characterized by defects in the development of two to five tissues derived from the embryonic ectoderm. As a part of the manifestation, oligodontia can occur. The implant-prosthetic therapy at an early age is a unique solution for providing good orofacial functions and a satisfactory aesthetic appearance in accordance with the social and emotional maturity of the patient.

Case presentation: The authors report the clinical case of a 8-year-old Caucasian boy with X-linked hypohidrotic ectodermal dysplasia and severe oligodontia (3 permanent and 3 deciduous teeth in the upper jaw and 1 permanent tooth in the lower jaw). In this patient, a functional rehabilitation with a conventional denture was not possible without the support of dental implants.

Conclusion: Inserting dental implants in the growing skeleton is still controversial. However, this approach was necessary for this patient with ectodermal dysplasia associated with severe oligodontia to restore oral function and appearance. A multidisciplinary approach was mandatory. It seems that with carefully determined time point of the implant insertion, properly chosen insertion site and full information of the patient and parents on all aspects of implant insertion and rehabilitation, this kind of rehabilitation might be a good option when other prosthetic means are not possible or have failed.

Izveleček

Izhodišče: Ektodermalna displazija je skupina redkih dednih bolezni, ki jih opredeljujejo razvojne motnje v 2–5 ektodermalnih strukturah. Kot del klinične slike se pogosto pojavlja tudi oligodontija. Implantatno-protetična oskrba pri zgodnji starosti je sicer še vedno kontroverzna odločitev, vendar je hkrati edina funkcionalna oralna rehabilitacija, ki poleg dobrega žvečenja zagotavlja tudi ustrezen videz in omogoča socialno rehabilitacijo.

Prikaz primera: Prikazan je klinični primer 8-letnega dečka z na kromosom vezano hipohidrotično ektodermalno displazijo, pri kateri se kaže obsežna oligodontija (le 3 stalni in 3 mlečni zobje v zgornji čeljusti in 1 stalni zob v spodnji čeljusti). Funkcionalne oskrbe s klasičnima protezama ni bilo mogoče izvesti, zato je bila potrebna podpora spodnje proteze z vstavitvijo dveh zobnih vsadkov.

Zaključek: Vstavljanje zobnih vsadkov v še rastočo kost je še vedno nedorečeno vprašanje. Predstavljena rehabilitacija bolnika z ektodermalno displazijo, povezano s hudo oligodontijo, je vendar še najboljša možna oskrba za vzpostavitev ustrezne funkcije in videza obraza. Načrtovali smo

¹ Department of Prosthodontics, Faculty of Medicine, University of Ljubljana, Ljubljana, Slovenia

² Department of Maxillofacial and Oral Surgery, Medical Faculty Ljubljana, Ljubljana, Slovenia

³ Department of Pediatric Dentistry, Faculty of Medicine, University of Ljubljana, Ljubljana, Slovenia

Correspondence/

Korespondenca:

Sonja Zarkovic Gjurin, e:
sonja.zarkovic@mf.uni-lj.si

Key words:

ectoderm; dysplasia; child; prosthodontics; dental implants

Ključne besede:

ektoderm; displazija; otrok; protetika; zobni vsadki

Received: 4. 11. 2019

Accepted: 15. 3. 2020



multidisciplinarno oskrbo s pravilno izbranim časom vstavitve vsadkov in natančno določenim mestom vstavitve.

Cite as/Citirajte kot: Zarkovic Gjurin S, Ihan Hren N, Tomažević T, Oblak Č. Early prosthetic rehabilitation of severe oligodontia with implant-retained overdenture: A case report. *Zdrav Vestn.* 2020;89(9–10):521–7.

DOI: <https://doi.org/10.6016/ZdravVestn.3004>



Copyright (c) 2020 Slovenian Medical Journal. This work is licensed under a Creative Commons Attribution-NonCommercial 4.0 International License.

1 Introduction

Ectodermal dysplasia (ED) is a hereditary disease, characterized by defects in the development of two to five tissues derived from the embryonic ectoderm. The National Foundation for Ectodermal Dysplasias (NFED) states that there exist more than 180 different ED that are recognized and named based on specific combinations of symptoms (1). Each ED has its own combination of symptoms - baldness, thin and abnormally shaped nails, thin, dry and pale skin, abnormally functioning sweat glands and missing or distinctively shaped teeth. Other symptoms include deficient saliva and tears, poorly functioning mucous membranes, frequent respiratory infections, hearing and vision anomalies, missing fingers and toes, cleft lip and/or palate and immune system deficiency (2). The incidence of ED is about 7 per 10,000 live births (3).

The most common anomaly of the dental development in humans is dental agenesis with a prevalence from 2.6% to 11.3% in different populations (4). Dental agenesis may occur in isolation or as a part of the syndrome (5). Fournier et al. have shown that the pattern of dental agenesis provides information about the gene mutation and could give molecular diagnosis for geneticists (5).

As a part of ED manifestation, oligodontia and anodontia can occur.

Oligodontia is defined as the congenital absence of 6 or more permanent teeth, excluding the third molars (4,6). Anodontia is a rare phenomenon and is characterized by the absence of all teeth (6). In affected patients, the extensive lack or even complete absence of teeth results in an atrophy and a reduced growth rate of the affected alveolar processes (7). Both of the above contribute to reduced occlusal vertical dimension (OVD) (3). Due to all mentioned characteristics, an old age appearance is common in affected patients (8). However, the importance of the dental rehabilitation is still underestimated in the whole syndrome treatment (5).

The missing teeth, underdeveloped alveolar ridges and even the underdevelopment of the maxillofacial skeleton in patients with ED, cumulatively contribute to aesthetic, functional and physiological problems (6). The peculiar facial features compared to other peers contribute to psychological problems of the patient. Therefore, an early interdisciplinary approach is needed to provide a beneficial overall development and well-being for young patients with ED. The aim of this case report is to present a functional and aesthetic rehabilitation of a young boy with severe oligodontia caused by hypohydrotic ED.

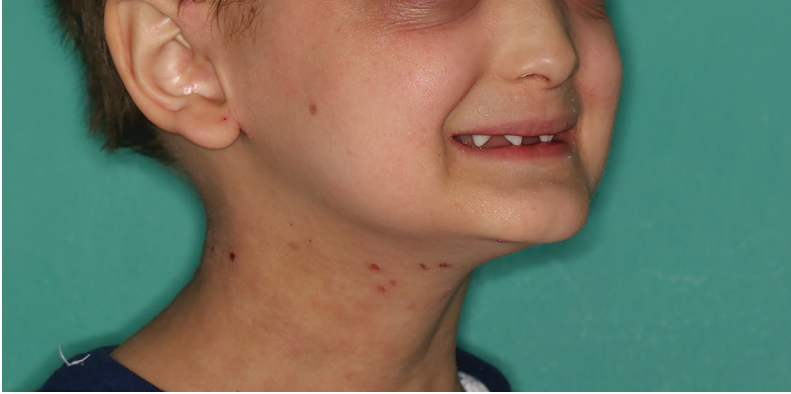

Figure 1: Lower part of the face of the patient at the age of seven with ectodermal dysplasia and severe hypodontia in mandible and maxilla.

2 Case presentation

The patient (male, white, Caucasian) exhibited X-linked hypohydrotic ED (mutation of the EDA gene). At the age of 7, the clinical evaluation revealed a child with a growth disorder, thin and dry scaly skin with eczema. His hair and eyebrows were thin, sparse and pale with no eyelashes (Figure 1). Eyeballs were big and prominent. The nose and mouth were small. An insufficiency in the lower third of the facial height was identified, caused by the bone deficiency due to the disturbed embryogenesis of the bone as a result of missing tooth germs.

The intraoral examination revealed

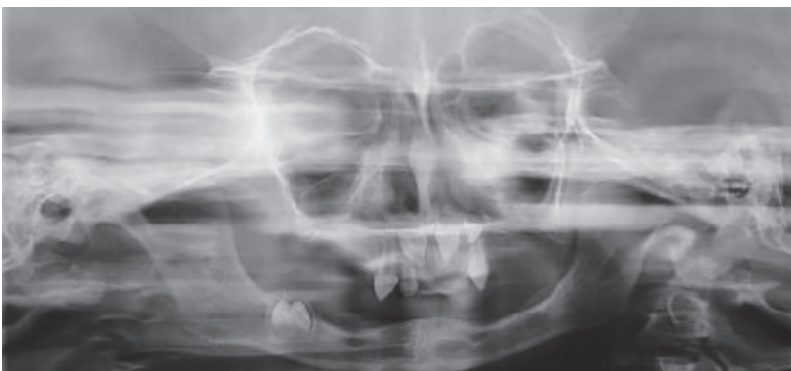

Figure 2: Orthopantomogram of the patient with persistent teeth in the maxilla and one tooth in the mandible.

serious atrophy of the alveolar ridges and severe oligodontia. In the deciduous dentition only the central maxillary incisor and both maxillary canines were identified. These teeth were conically shaped. A basic panoramic radiograph exposed five germs of both maxillary central incisors, the upper left canine and the first right mandibular molar (Figure 2). The crowns of the permanent teeth were malformed with not definitively evolved roots.

The patient was enrolled at a primary school and he and his parents increasingly worried about his looks and pronunciation of words. After an interdisciplinary consultation of the paediatric dentist, orthodontist, maxillofacial surgeon and prosthodontist, an optimal therapy decision about the interdisciplinary rehabilitation was met. The main goals of the therapy were to recover the masticatory functions, to improve the aesthetic appearance and to reduce psycho-social handicaps of the patient. After the orthodontic extrusion of the upper incisors, the insertion of two implants in the anterior mandible and a prosthetic rehabilitation with the upper and lower overdenture were planned.

Following general anaesthesia and orotracheal intubation, two 9.5 mm long implants with a diameter of 3.5 mm (Ankylos C/X, Dentsplay, Germany) were placed in the canine region of the mandible. During the same procedure, two orthodontic implants (Forestadent, Pforzheim, Germany) were inserted medially from the dental implants, to retain orthodontic guidance for fenestration of both impacted upper first incisors. After 4 months, again following general anaesthesia, the implants were exposed and covered with healing screws, the orthodontic implants were removed. The dental implants resulted in a safe primary

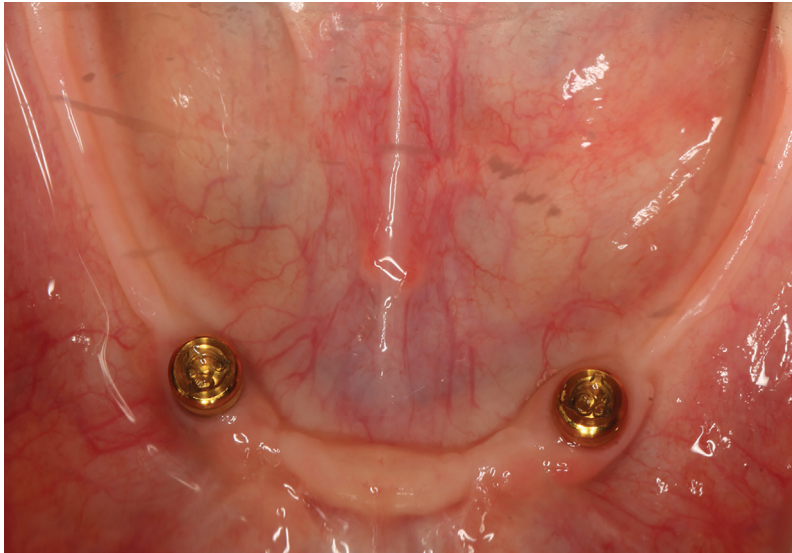


Figure 3: Position of the implants with two retentive elements (Locator®).

stability.

The prosthodontic procedures started three weeks later, as soon as the soft tissue around the healing abutments had healed. In the upper jaw, a conventional tooth overdenture with covered two permanent incisors and two deciduous canines was planned. The impression for the upper overdenture was made of Isofunction thermoplastic material

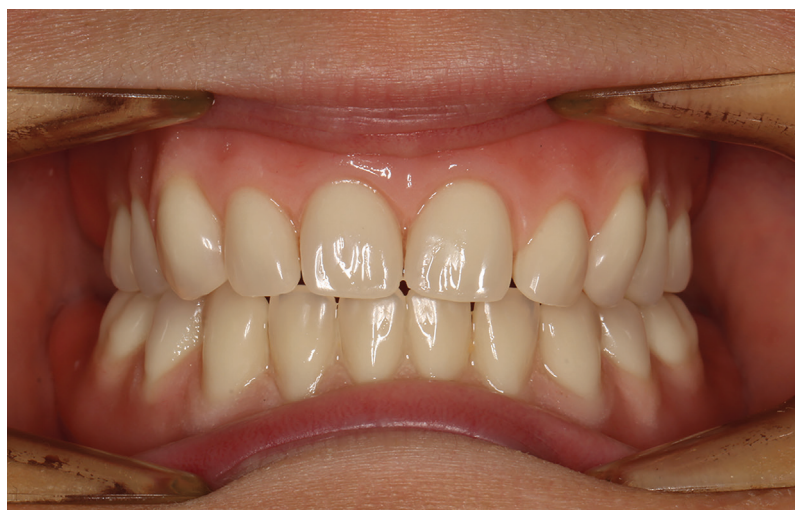

Figure 4: Intraoral appearance of the patient with upper and lower overdentures. Every four months the dentures were corrected according to skeletal growth changes and allowed eruption of the teeth.

(GC Corporation, Tokyo, Japan) and Impregum polyether impression material (3M Espe AG, Seefeld, Germany).

A combination of polyether (Impregum, 3M Espe AG, Seefeld, Germany) and thermoplastic (Ex-3-N Gold, Johannes Meist, Schopfloch, Germany) impression of the lower jaw with abutment copings was taken. After the bite registration, the upper and lower models were mounted in an articulator (Artex, Amann Girrbach AG, Koblach, Austria). We opted for overdenture Locator® attachment system (Zest Dental Solutions, Carlsbad, CA, USA) (Figure 3).

The patient seemed to be very satisfied when both dentures were first inserted (Figure 4). After inserting the dentures, he was enrolled in the logopaedic therapy for a few weeks. He has no speech defects and is well adapted. The dentures have now been in situ for 2 years and have functioned well.

Every four months, the patient is scheduled for a recall. Each time the dentures are checked with silicon (Fit Checker Advanced GC Corporation, Tokyo, Japan), corrected according to changes in the skeletal growth and if necessary, a relining of the dentures is carried out. At the check-up after two years, a control orthopantomogram was made that showed good osseointegration of both implants (Figure 5). The teeth under the upper tooth – overdenture are exposed to an aggressive environment, therefore they require cleaning and professional care. Every three months a professional teeth cleaning and a fluoride treatment by paediatric dentist is provided.

After the skeletal growth is completed, a definitive fixed prosthetic rehabilitation is planned. Due to the underdeveloped alveolar ridges augmentation

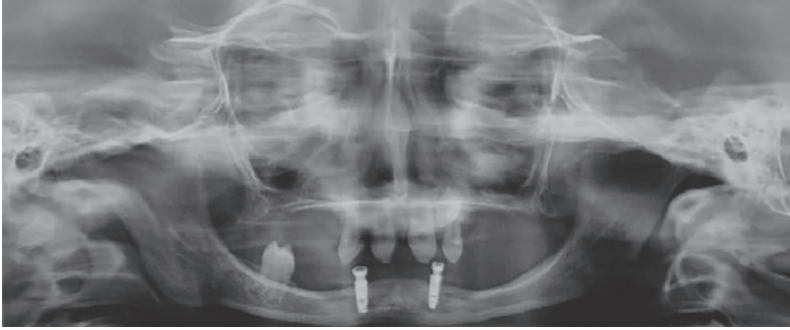


Figure 5: Orthopantomogram at a check-up after 2 years.

procedures are planned in the future. Furthermore, the upper and lower transitional overdentures are also conducive to the patient's aesthetic appearance satisfaction.

3 Discussion

Rehabilitation of patients with a large number of missing teeth predominantly requires an interdisciplinary treatment approach, involving a paediatric dentist, an orthodontist, a maxillofacial surgeon and a prosthodontist. The treatment plan depends on the severity of the development of the disorder. In this study, we present the prosthetic rehabilitation of an 8-year old patient with severe oligodontia (3 permanent and 3 deciduous teeth in the upper jaw and 1 permanent tooth in the lower jaw). In this patient a functional rehabilitation with a conventional denture was not possible without the support of dental implants. Another important reason for rehabilitation was the urgency of restoring the patient's health and improving his facial appearance. In addition to the small number of permanent teeth and their abnormal shape, the most common problems in the rehabilitation of patients with ED are the underdeveloped alveolar ridges (3,7). As the alveolar bone development is dependent on the presence of teeth,

patients with ED have little or even no bone ridge upon which a denture may be constructed (9,10). The benefits of the implant use in growing patients are as important as the concerns about their premature use (11). Some researchers claim that implant treatment should be postponed until the jaw has stopped growing, but this type of treatment might be an alternative in specific cases, considering the balance between the patient's needs and prognosis (12).

The insertion of dental implants in children before the completion of the craniofacial growth is accompanied by several problems (7). It has been previously shown that the placed implants can imitate the effects of ankylosed teeth (7,11,13). Inserted implants do not participate in growth processes and therefore result in an infra-occlusion and multidimensional dislocation (7). Transversal growth of the maxilla occurs mostly at the mid-palatal suture (11). Thereupon, fixed implant constructions crossing the mid-palatal suture will result in a transversal growth restriction of the maxilla (11). The insertion of implants in the growing maxilla should therefore be avoided until the end of the growth period (7,11).

In the mandible, the transversal skeletal or alveolo-dental changes are less dramatic than in the maxilla (7). In the posterior mandible, growth changes occur predominantly in the late childhood with large amounts of anteroposterior, transverse and vertical growth (11). In the anterior mandible, the alveolar growth seems relatively small when teeth are missing (6,11). Consequently, in children with severe oligodontia, the anterior mandible might represent the most suitable site of the implant placement (7,11). At a later point in time, the implants located at the anterior mandible

will probably seem affected by the mandibular growth rotation that may result in a change in the implant angulation (11). In the monocentric prospective studies of Marieke Filius et al., the survival rate of implants placed in the anterior mandible of paediatric patients with ED was reported to be 91% (6,11). Yap and Klineberg report implant survival rates along the same lines, varying between 88.5 and 97.6% in patients with ED (14). Bergendal et al. noted a 35.7% implant success rate in five young patients (13,15). All failures occurred before the loading of implants (13,15). The poor result was attributed to the small jaw size and not to ED (15).

The multidisciplinary team approach to the patients' follow-up is critical in ensuring a successful result and avoiding complications (16). Since the edentulous alveolar ridge is loaded at an early age, progressive alveolar bone resorption might be the issue of concern (17). To address changes in the occlusion and the fit of the prostheses, every three months the denture should be relined and, after 4 - 6 years, a new denture should be made (4,17). Furthermore, a satisfactory oral hygiene and maintenance of dental implants could prove to be demanding (16,17). Periodontal complications and increased caries rate may further put the prosthetic work at risk (17).

Many reports suggest that children with disabilities compare themselves with other peers already at the age of 9, and are able to recognize the particularities of their own condition. The latter probably leads to the state of depression (7). The implant location, the sex of the patient and the skeletal maturation level are the most important factors in the final decision of when and where to place the implants (11). It has been recommended that the safest time to place implants

seems to be during the lower portion of the declining adolescent growth curve or near adulthood, which can be determined by cephalometric analysis (11,12). Filius et al. imply that the implants for the mandibular overdenture support may be inserted from the age of 6 onwards (6).

4 Conclusion

In order to provide good orofacial functions and a satisfactory aesthetic appearance in accordance with the social and emotional maturity of the patient, the use of a specific multidisciplinary clinical approach was mandatory. Following the presented case report and the reviewed literature, dental implants in growing patients suffering from ED associated with severe oligodontia or anodontia can be inserted, when other means of prosthetic rehabilitation fail or are not suitable. The most suitable site of insertion is found to be the anterior mandible, and the implant insertion in the maxilla should be avoided. The time point of the implant insertion should be carefully determined. Accurate informing of the patient and the patient's parents of all oral rehabilitation procedures is imperative before the beginning of the treatment.

5 Consent to publish

Written informed consent was obtained from the parents for publication of this case report and any accompanying images. A copy of consent is available for the journal.

6 Acknowledgments

We thank the patient and his parents for allowing the publication of this case report.

References

1. Oblak C, Ovsenik M, Ihan Hren N. Interdisciplinary treatment of ectodermal dysplasia with oligodontia: review and case report. *Zdrav Vestn*. 2013;82:266-72.
2. Yenisey M, Guler A, Unal U. Orthodontic and prosthodontic treatment of ectodermal dysplasia—a case report. *Br Dent J*. 2004;196(11):677-9. DOI: [10.1038/sj.bdj.4811344](https://doi.org/10.1038/sj.bdj.4811344) PMID: [15192726](https://pubmed.ncbi.nlm.nih.gov/15192726/)
3. Bidra AS, Martin JW, Feldman E. Complete denture prosthodontics in children with ectodermal dysplasia: review of principles and techniques. *Compend Contin Educ Dent*. 2010;31(6):426-33. PMID: [20712106](https://pubmed.ncbi.nlm.nih.gov/20712106/)
4. Dharmo B, Kuijpers MA, Balk-Leurs I, Boxum C, Wolvius EB, Ongkosuwito EM. Disturbances of dental development distinguish patients with oligodontia-ectodermal dysplasia from isolated oligodontia. *Orthod Craniofac Res*. 2018;21(1):48-56. DOI: [10.1111/ocr.12214](https://doi.org/10.1111/ocr.12214) PMID: [29271123](https://pubmed.ncbi.nlm.nih.gov/29271123/)
5. Fournier BP, Bruneau MH, Toupenay S, Kerner S, Berdal A, Cormier-Daire V, et al. Patterns of Dental Agenesis Highlight the Nature of the Causative Mutated Genes. *J Dent Res*. 2018;97(12):1306-16. DOI: [10.1177/0022034518777460](https://doi.org/10.1177/0022034518777460) PMID: [29879364](https://pubmed.ncbi.nlm.nih.gov/29879364/)
6. Filius MA, Vissink A, Raghoebar GM, Visser A. Implant-retained overdentures for young children with severe oligodontia: a series of four cases. *J Oral Maxillofac Surg*. 2014;72(9):1684-90. DOI: [10.1016/j.joms.2014.04.034](https://doi.org/10.1016/j.joms.2014.04.034) PMID: [25109582](https://pubmed.ncbi.nlm.nih.gov/25109582/)
7. Kramer FJ, Baethge C, Tschernitschek H. Implants in children with ectodermal dysplasia: a case report and literature review. *Clin Oral Implants Res*. 2007;18(1):140-6. DOI: [10.1111/j.1600-0501.2006.01180.x](https://doi.org/10.1111/j.1600-0501.2006.01180.x) PMID: [17224035](https://pubmed.ncbi.nlm.nih.gov/17224035/)
8. Hekmatfar S, Jafari K, Meshki R, Badakhsh S. Dental management of ectodermal dysplasia: two clinical case reports. *J Dent Res Dent Clin Dent Prospects*. 2012;6(3):108-12. PMID: [22991648](https://pubmed.ncbi.nlm.nih.gov/22991648/)
9. Alvarez-Arenal A, Gonzalez-Gonzalez I, deLlanos-Lanchares H, Martin-Fernandez E, Brizuela-Velasco A, Ellacuria-Echebarria J. Effect of implant- and occlusal load location on stress distribution in Locator attachments of mandibular overdenture. A finite element study. *J Adv Prosthodont*. 2017;9(5):371-80. DOI: [10.4047/jap.2017.9.5.371](https://doi.org/10.4047/jap.2017.9.5.371) PMID: [29142645](https://pubmed.ncbi.nlm.nih.gov/29142645/)
10. Bani M, Tezkirecioglu AM, Akal N, Tuzuner T. Ectodermal dysplasia with anodontia: a report of two cases. *Eur J Dent*. 2010;4(2):215-22. DOI: [10.1055/s-0039-1697832](https://doi.org/10.1055/s-0039-1697832) PMID: [20396456](https://pubmed.ncbi.nlm.nih.gov/20396456/)
11. Mankani N, Chowdhary R, Patil BA, Nagaraj E, Madalli P. Osseointegrated dental implants in growing children: a literature review. *J Oral Implantol*. 2014;40(5):627-31. DOI: [10.1563/AAID-JOI-D-11-00186](https://doi.org/10.1563/AAID-JOI-D-11-00186) PMID: [22214484](https://pubmed.ncbi.nlm.nih.gov/22214484/)
12. Bohner L, Hanisch M, Kleinheinz J, Jung S. Dental implants in growing patients: a systematic review. *Br J Oral Maxillofac Surg*. 2019;57(5):397-406. DOI: [10.1016/j.bjoms.2019.04.011](https://doi.org/10.1016/j.bjoms.2019.04.011) PMID: [31076220](https://pubmed.ncbi.nlm.nih.gov/31076220/)
13. Bergendal B, Ekman A, Nilsson P. Implant failure in young children with ectodermal dysplasia: a retrospective evaluation of use and outcome of dental implant treatment in children in Sweden. *Int J Oral Maxillofac Implants*. 2008;23(3):520-4. PMID: [18700377](https://pubmed.ncbi.nlm.nih.gov/18700377/)
14. Yap AK, Klineberg I. Dental implants in patients with ectodermal dysplasia and tooth agenesis: a critical review of the literature. *Int J Prosthodont*. 2009;22(3):268-76. PMID: [19548409](https://pubmed.ncbi.nlm.nih.gov/19548409/)
15. Créton M, Cune M, Verhoeven W, Muradin M, Wismeijer D, Meijer G. Implant treatment in patients with severe hypodontia: a retrospective evaluation. *J Oral Maxillofac Surg*. 2010;68(3):530-8. DOI: [10.1016/j.joms.2009.09.012](https://doi.org/10.1016/j.joms.2009.09.012) PMID: [20171472](https://pubmed.ncbi.nlm.nih.gov/20171472/)
16. Bergendal B, Bjerklin K, Bergendal T, Koch G. Dental Implant Therapy for a Child with X-linked Hypohidrotic Ectodermal Dysplasia—Three Decades of Managed Care. *Int J Prosthodont*. 2015;28(4):348-56. DOI: [10.11607/ijp.4242](https://doi.org/10.11607/ijp.4242) PMID: [26218015](https://pubmed.ncbi.nlm.nih.gov/26218015/)
17. Maroulakos G, Artopoulou II, Angelopoulou MV, Emmanouil D. Removable partial dentures vs overdentures in children with ectodermal dysplasia: two case reports. *Eur Arch Paediatr Dent*. 2016;17(3):205-10. DOI: [10.1007/s40368-015-0212-x](https://doi.org/10.1007/s40368-015-0212-x) PMID: [26645986](https://pubmed.ncbi.nlm.nih.gov/26645986/)