

Magnetic resonance cholangiography in patients with bile duct obstruction

Lidija Lincender, Ermina Sadagic, Dunja Vrcic, Sandra Vegar, Nataša Stevic

Institute of Radiology, Clinical Center of Sarajevo University, Sarajevo, Bosnia and Herzegovina

Background. The aim of this study was to assess the diagnostic value of magnetic resonance cholangiography (MRC). This is a new non-invasive imaging technique for the evaluation of bile duct obstruction.

Patients and method. MRC was performed on patients with bile duct obstruction at 1.0 T U. Over a period of 26 months, 44 patients, 23 males and 21 females, mean age 51 years, were examined. The basis were T2-weighted sequences through the liver to accentuate the fluid fill bile duct, and fast spin echo sequences. Usually, the thickness of the slices was 4 mm. Two spatial planes were performed, coronal and axial, with the breath held and released, and with maximum intensity projection (MIP) reconstruction. In our case, with Machine 1.0T, we compared the results of ultrasound and CT with MRC in the patients with bile duct obstruction before surgical intervention or drainage procedure.

Results. We examined 44 patients with jaundice by MRC and with the 100% accuracy identified the level of the obstruction. Clinical applications of MRC were evaluated on the basis of personal experience, and data literature. The main indication for MRC study was the evaluation of common bile duct obstruction without using contrast medium and biliary intervention.

Conclusions. MR technique has been dictated by image performance and sequence availability. Our experience and results confirmed that MRI is more accurate than US and CT in patients with bile duct obstruction.

Key words: cholestasis-diagnosis; magnetic resonance imaging; bile ducts neoplasms; cholelithiasis,

Introduction

Current non-invasive imaging techniques, such as ultrasound (US) and computerized tomography (CT), have a limited potential in diagnosing biliary duct disorders. As a result, many patients with suspected biliary duct disorders undergo more invasive diagnostic procedures, such as endoscopic retrograde cholangiopancreatography (ERCP) and percutaneous transhepatic cholangiography (PTC).

Received 19 June 2000

Accepted 6 July 2000

Correspondence to: Prof. Lidija Lincender, MD, PhD, Institute of Radiology, Clinical Center of Sarajevo University, Bolnička 52, BH-71000 Sarajevo, Bosnia and Herzegovina. E-mail: lidijal@yahoo.com

Those procedures have low, yet significant morbidity and mortality.¹ Magnetic resonance cholangiography (MRC) techniques can be an alternative to non-invasive methods of imaging of the biliary duct.² The techniques developed over the past 5 years have a diagnostic performance comparable to diagnostic ERCP and are being utilized clinically in the management of the biliary and pancreatic disease.^{3,4} The interpretation involves the review of typically maximum intensity projection (MIP) after the processing of the volume data to allow a 3 D visualization of the biliary anatomy. An alternative approach which utilizes a projection technique allowing rapid assessment of the biliary and pancreatic duct systems without the need for post processing has been proposed.⁵ RARE (Rapid Acquisition with Relaxation Enhancement) technique requires a long effective echo time of 750 - 1000 ms with the imaging contrast obtained by fluid alone, the so-called MR hydrography.⁶

Patients and methods

The MRC technique is based on heavily T2 weighted images which yields a remarkable increase in contrast between stationary fluids (bile) and background (hepatic parenchyma, abdominal fat). As a result, the bile presents a very high signal intensity compared with low signal intensity background. At our Institute, MRC examinations were performed by 1.0T super conductive magnet with body coil. We used T2 weighted images, fat suppressed (FS), turbo spin echo (TSE) axial sequences. Imaging parameters modified during the past two years experiences were as follows: TR - 3500ms, TE - 99ms. Images were acquired on the coronal plane with 4 mm partition thickness, with the breath held. The imaging volume was positioned to the bile duct using axial sequences as scout view. FOV was 380 mm. Image matrix size was 256 x 256. We

used MIP reconstruction techniques (scan time 4min 43 sec). No patient preparation and sedation are required.

In 26 months, 44 patients were examined. The MRC was performed in the patients with bile duct obstruction. Our group of 44 patients included 23 males and 21 females, mean age 51.

Analysis

In each case, the investigators evaluated MRC (Figure 1) irrespective of the presence or absence of obstruction, the level and suspected cause of obstruction. Later, MRC findings were compared with the findings of US and CT that were made for all our patients before MRC.

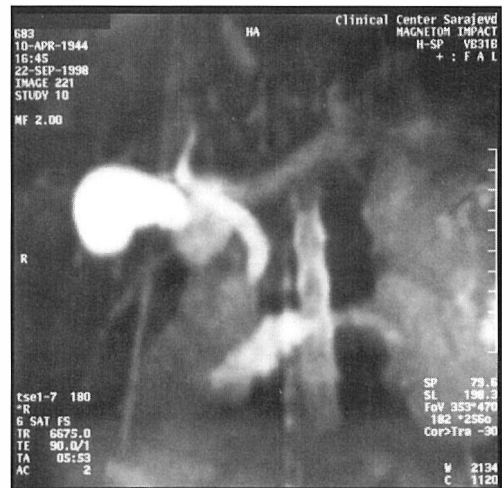

Figure 1. Normal anatomy on MIP reconstructed magnetic resonance cholangiography (MRC) images.

Results

In 44 patients, biliary obstruction represents the main indication for MRC study because of the potential of this technique to assess the presence, site and cause of the obstruction. All our patients had US and CT examination before MRC (Table 1).

Table 1. The MRC in biliary obstruction compare with US/CT

Finding	US/CT	MRC
Benign and malignant		
biliary strictures	4	6
Choledocholithiasis	6	8
Choledochoduodenal anastomosis with stones	0	2
Hilar lymphadenopathy, Tu hepatitis	4	5
Cholangiocarcinoma	6	8
Pancreatic head carcinoma	14	15
Biliary tree dilatation - icterus	10	0
Total	44	44

In 6 patients, MRC revealed benign or malignant biliary stricture (Figure 2), in 8 choledocholithiasis (Figure 3), in 3 choledocholithiasis with choledochoduodenal anastomosis (Figure 4), in 5 hilar lymphadenopathy

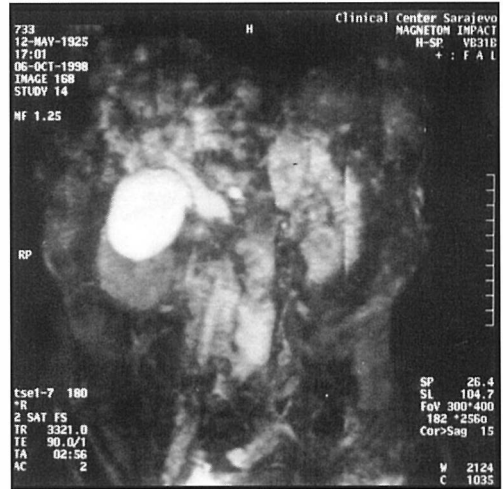

Figure 3. Maximum intensity projection (MIP) reconstructed MRC complete obstruction CBD with marked dilatation of the intrahepatic ducts and filling defects at the distal level of calculus.

Discussion

Biliary obstruction represents the main indication for MRC. The potential of this technique is to identify the presence, site, and cause of the obstruction. The accuracy in detecting the presence of the obstruction

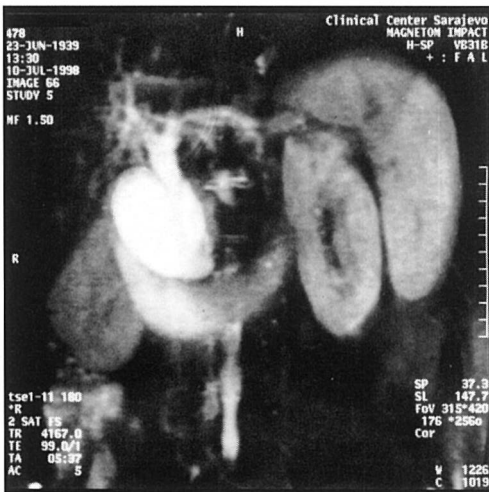


Figure 2. Common bile duct (CBD) is dilated with distal malignant stenosis.

and tumor hepatitis (Figure 5), in 8 cholangiocarcinoma (Figures 6a and 6b.), and in 15 pancreatic head carcinoma (Figures 7a and 7 b).

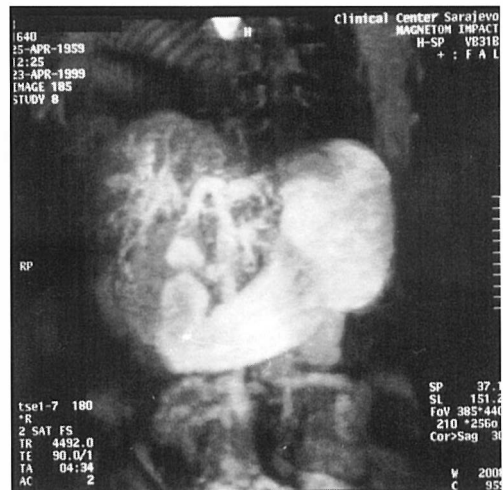

Figure 4. MIP reconstructed MRC complete obstruction CBD at the level of choledochoduodenal anastomosis, with remaining calculus.

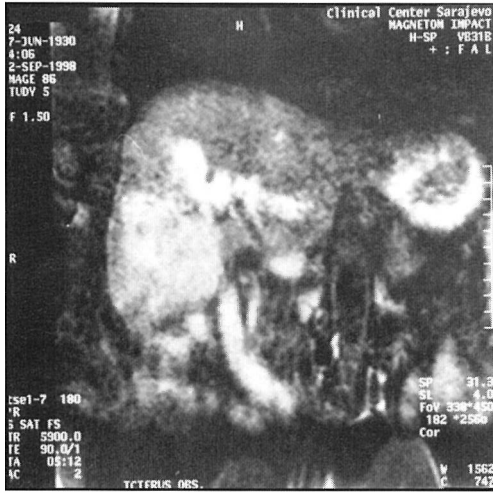


Figure 5. Liver tumor with the subsequent obstruction and intrahepatic biliary dilatation.

ranges between 91 - 100 % whereas the level of the obstruction can be correctly evaluated in 85 - 100 % of cases.^{7,8}

We examined 44 patients with jaundice and determined the level and cause of obstruction by MRC with 100 % and 86 % accuracy. The typical cholangiographic appearance of pancreatic head carcinoma is represented by a sudden obstruction at the

level of the head of the pancreas with a double duct sign due to biliary and pancreatic duct dilatation and evidence of mass effect. Usually, the obstruction, due to pancreatic cancer, is seen as "mouse tail" pattern or with a sudden reduction of the caliber of bile duct. In case of pancreatitis, the bile duct stenosis has a tapered aspect.⁹

The role of imaging modalities in cholangiocarcinoma is to identify the lesion, its stage, and, if unresectable, to plan the adequate palliative treatment. Cholangiocarcinoma may be presented as a stricture, involving CBD (30 - 36%), the common hepatic duct (15 - 30%), the biliary bifurcation with the typical aspect of mass lesion, or as a nodular process with intrahepatic solid mass.

MRC can provide a dilated map of the biliary tree above the stricture. Conventional MR images are needed for correct lesion identification and staging. In this case, T1weighted image, after contrast medium injection, can be very helpful for a correct identification of the lesion and of its relation with surrounding organs, even in the case of stenosing lesion.⁹ The evaluation of the strictures by MRC usually depends on the morphology and

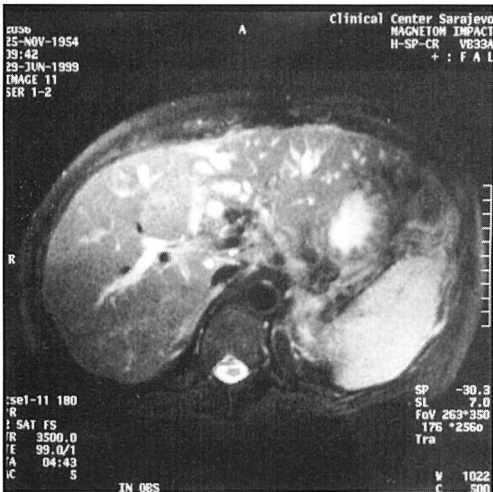


Figure 6a. Hilar cholangiocarcinoma with the marked dilatation of the intrahepatic duct; T2 weighted turbo spin echo (TSE).

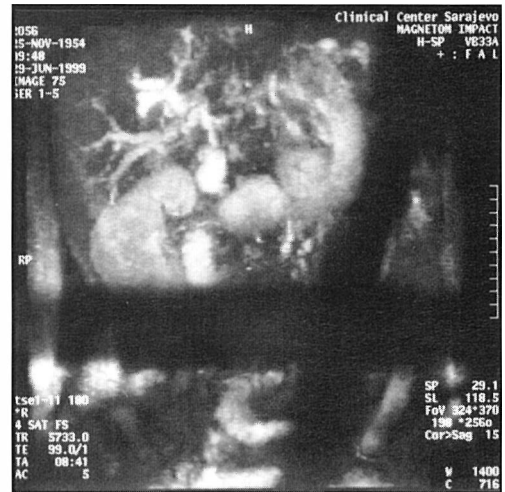

Figure 6b. Hilar cholangiocarcinoma with the marked dilatation of the intrahepatic duct; MIP reconstruction.

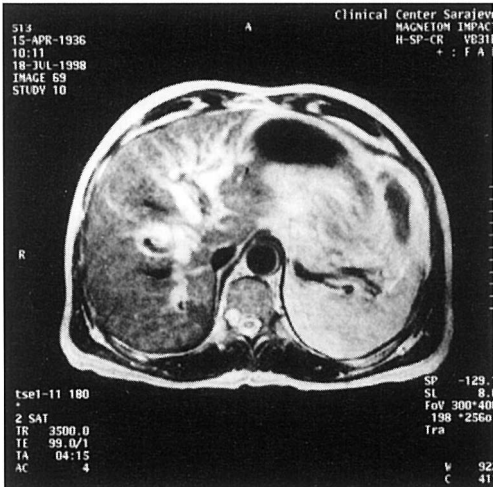


Figure 7a. Dilated bile duct - malignant obstruction due to pancreatic head carcinoma; axial T2 weighted.

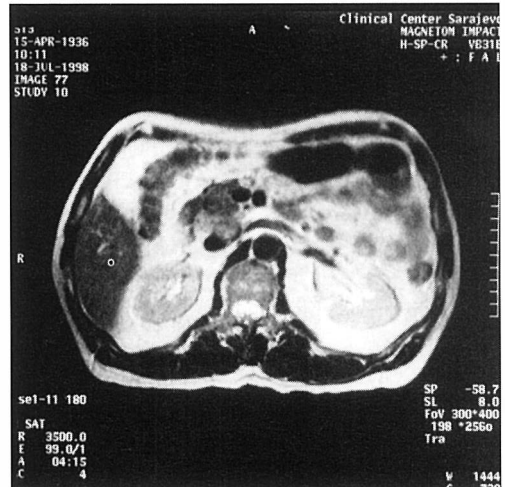


Figure 7b. Dilated bile duct - malignant obstruction due to pancreatic head carcinoma.

length of strictures. MRC in malignant strictures has to be considered as a part of complete abdominal evaluation, together with conventional MR images. Therefore, the role of MR images is to diagnose the obstruction, to define its cause, and to provide any additional information for CT and ERCP and that would require a change of the treatment plan.⁹ In the study of 79 patients with biliary obstruction, the sensitivity and specificity of the MR diagnose of malignant obstruction were 86 and 98%, respectively.¹⁰ Choledocholithiasis, irrespective of calcium content, almost always presents with low signal intensity on MR images.¹⁰ Therefore, the stone is identified as round or oval "filling defect" within the CBD, surrounded by the high signal intensity bile. The diagnostic accuracy of MRC in the choledocholithiasis is very high, ranging between 89 and 97%.¹¹⁻¹⁴

Nevertheless, different pitfalls can be observed which require a correct identification in order to avoid false diagnosis. They are represented by (a) artefacts on MIP reconstructed images, (b) CBD completely filled with stones, (c) pneumobilia, and (d) differential diagnosis between air bubbles and small stones. Secondary biliary involvement

can be caused by hilar lymphadenopathies, or hepatic metastases with the occlusion of segmental or subsegmental branches. In these cases MRC, can show the intrahepatic duct dilatation and the level of the intrahepatic hilar or subhilar occlusion. MRC displays the biliary map with the evaluation of dilated segments that may require percutaneous drainage.⁹

The role of MRC in the diagnostic algorithm of the patients with biliary - enteric anastomosis is to avoid unnecessary invasive imaging modalities.^{14,15} In the patients with hepaticojejunostomy, only PTC may be performed while MRC can also serve as a screening method for patients requiring treatment or as further evaluation with PTC or ERCP. MRC may also be used as a guide for a subsequent interventional procedure. Only 3 patients who had previously undergone biliary surgery and choledochoduodenostomy were included into our study.

Conclusion

The dilatation of the biliary tree due to tumor, stones or stricture was depicted with

excellent contrast resolution. It is known from literature that MRC technique has been dictated, to some extent, by the image performance and sequences availability. MRC can provide non-invasive comparable diagnostic information for the diagnostic ERCP of biliary disorders and may allow selective use of therapeutic ERCP. Sometimes MRC, together with conventional MR images, may replace CT and ERCP in pre-surgical evaluation of patients.

References

1. Bilbao MK, Dotter CT, Lee TG, Katon RM. Complications of retrograde cholangio-pancreatography (ERCP): a study of 10,000 cases. *Gastroenterology* 1976; **70**: 314-20.
2. Walher BK, Schumacher KA, Weidenmaier W, Fridrich JM. Dilated biliary tract: evaluation with MR cholangiography with T2 weighted contrast enhanced fast sequences. *Radiology* 1991; **181**: 578-80.
3. Hart R, Classen M. Complications of diagnostic gastrointestinal endoscopy. *Endoscopy* 1990; **22**: 219-23.
4. Patel JC, McInnes GS, Bagley JS, Needham G, Krukovski ZH. The role of intravenous cholangiography in pre-operative assessment for laparoscopic cholecystectomy. *Br J Radiol* 1993; **66**: 1125-7.
5. Laubenberger J, Buchert M, Schneider B, Blum U, Hennig J, Langer M. Breathhold projection magnetic resonance cholangiopancreatography (MRCP): a new method for the examination of the bile and pancreatic ducts. *Magn Res Med* 1995; **33**: 823-33.
6. Henning J, Nauerth A, Friedburg H. RARE Imaging: a fast imaging method for clinical MR. *Magn Reson Med* 1986; **3**: 823-33.
7. Ishizaki Y, Wakayama T, Okada Y, Kobayashi T. Magnetic resonance cholangiography of obstructive jaundice. *Am J Gastroenterol* 1993; **88**: 2072-7.
8. Hall-Craggs MA, Allen CM, Owens CN, Theis BA, Donalds JJ, Paley M, et al. MR Cholangiography: clinical evaluation in 40 cases. *Radiology* 1993; **189**: 423-7.
9. Pavone P, Laghi A, Panebianco U, Catalano C, Lobina L, Passariello R. MR Cholangiography: techniques and clinical applications. *Eur Radiol* 1998; **8**: 901-10.
10. Baron RL, Shuman WP, Lee SP, Rohrmann CA Jr, Golden RN, Richards TL, et al. MR appearance of gallstones in vitro at 1.5 T: correlation with chemical composition. *AJR* 1989; **153**: 497-502.
11. Guibad L, Bret MP, Reinhold C, Atri M, Barkun ANG. Diagnosis of choledocholithiasis : value of MR cholangiography. *AJR* 1994; **163**: 847-50.
12. Guibard L, Bret PM, Reinhold C, Atri M, Barkun AN. Bile duct obstruction and choledocholithiasis: diagnosis with MR cholangiography. *Radiology* 1995; **197**: 109-115.
13. Pavone P, Laghi A, Catalano C, Broglio L, Digirolamo M, Passariello R. MR Cholangiography predictive value in assessing main duct stones before laparoscopic cholecystectomy [abstract]. *Radiology* 1995; **197**: 342-3.
14. Papp J, Tulassay Z, Bielawski J, Hajos E, Kollin E, Pfeiffer I. Diagnostic value of endoscopic retrograde cholangiopancreatography in biliodigestive anastomoses. *Acta Hepato Gastroenterol* 1997; **24**: 41-3.
15. Pavone P, Laghi A, Catalano C, Broglio L, Panebianco L, Messina A, et al. MR cholangiography in the examination of the patients with biliary-enteric anastomoses. *AJR* 1997; **169**: 807-11.