

## Differential diagnosis between bone metastases and osteomalacia

Branko Zakotnik, Simona Borštnar, Tadeja Movrin, Breda Jančar, Andreja Zidar

*The Institute of Oncology, Ljubljana, Slovenia*

*In oncology the diagnosis of skeletal metastases is a frequent one, in fact so frequent that other diagnoses such as metabolic bone diseases affecting patients with cancer may be overlooked. In our report two cases of osteomalacia referred to an oncologist are presented; in both of them the diagnosis of diffuse bone metastases of unknown origin was suspected. The differential diagnosis is discussed and the importance of bone marrow biopsy using Yamshidi needle for diagnosis of metabolic bone disease is emphasized.*

*Key words:* bone neoplasm-secondary, osteomalacia, diagnosis, differential

### Introduction

Bone metastases represent 60-65 % of malignant lesions in the bones. They are often the first manifestation of malignant disease and sometimes the primary site of malignancy remains unknown. The spine and pelvis are most often affected, lesions distal to elbows and knees are rare. Malignancies most often associated with skeletal metastases are lung, breast, prostate, renal and thyroid cancer.<sup>1</sup>

The diagnosis is usually established with the help of history (pain), clinical examination (painful succussion, altered mobility, deformities due to pathologic fractures), laboratory tests (elevated serum alkaline phosphatase, sometimes serum calcium), X-ray of the skeleton (osteolytic, osteoplastic, osteolytic-osteoplastic lesions, pathologic fractures), skeletal scintigraphy and sometimes CT and MR.

*Osteomalacia* is a disease due to pathologic loss of mineralized bone.<sup>2</sup> Because of a low serum calcium concentration a substantial part of the bone matrix is not normally mineralized. The density of the bone is thus diminished, which leads to bending of bones and pathologic fractures.

Clinical conditions associated with osteomalacia are:

1. Deficiency of vitamin D (dietary absence of vitamin D or inadequate exposure to sunlight)

2. Diminished absorption of vitamin D (diseases of the bile ducts, diseases of proximal part of the small bowel, exocrine pancreatic insufficiency, gastrectomy)

3. Disorders of vitamin D metabolism (liver diseases, drugs that activate hepatic oxidative enzymes, resistance to vitamin D)

4. Kidney disorders (loss of phosphates)

5. Chronic use of large amount of antacids containing Mg and Al, which form with phosphates insoluble complexes

Osteomalacia usually presents clinically as bone, joint and muscle pain and fatigue.

Beside the medical history and clinical examination the most important diagnostic procedures for osteomalacia are laboratory findings (low values of serum calcium and phosphates, elevated serum PTH and later alkaline phosphatase) and aspecific and specific x-ray changes of bones.

### Case histories

#### *Case 1*

A 47 year old woman was admitted to our Institute with a diagnosis of bone metastases of unknown origin.

She was a smoker for several years and 16 years ago a diagnosis of Bürger's disease was established.

She had diabetes mellitus regulated with diet and oral therapy, and angina pectoris.

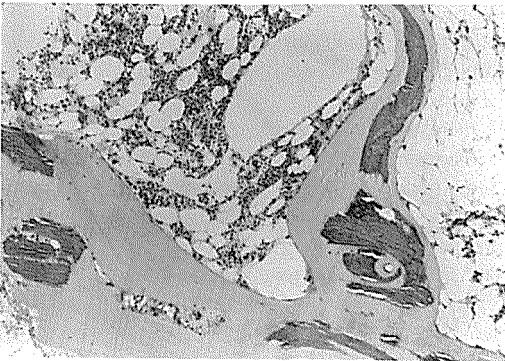
Two years previously she noticed pain in her legs when walking which became so severe that for half a year she could only move around in a wheelchair.

On clinical examination, she was found to have pale skin, ataxia, dextroconvex scoliosis of thoracic spine, painful spine on succussion, muscular weakness of all muscles of the lower extremities.

The laboratory tests revealed a normocytic normochromic anemia Hb 81 g/l (normal 120-180 g/l), elevated chlorides 110 mmol/l (normal 95-105 mmol/l), elevated alkaline phosphatase to 4.32  $\mu$ kat/l (normal 0.50-1.50), lowered serum phosphate 0.7 mmol/l (normal 0.8-1.4) and serum calcium to 1.7 mmol/l (normal 2.10-2.60). All other laboratory parameters (biochemical, protein electrophoresis) were within normal limits.

On skeletal X-ray, the spine showed structural atrophy (osteopenia). In the pelvis and ribs numerous fractures in the area of Looser zones were seen.

We performed a bone marrow biopsy of spina iliaca posterior superior with a Yamshidi needle. Histologically the bone marrow aspirate was within normal limits while bone tissue showed osteomalacia (Figure 1).



**Figure 1.** Trabecular bone of patient with osteomalacia. Wide osteoid seams cover trabecular surfaces without increased numbers of osteoclasts.

We concluded that the changes in the bone were due to osteomalacia and not to bone metastases. The patient was referred to an endocrinologist for further investigations and treatment. At follow up, after three years, her symptoms lessened and otherwise she was doing well.

#### Case 2

A 72-year old woman was referred to our Institute with a diagnosis of diffuse skeletal metastases. A

partial resection of her stomach (Billroth II) was performed 37 years ago for unknown reason. She was treated 13 years ago with radioactive iodine because of goiter. At recent follow-up examination, she had no problems related to thyroid.

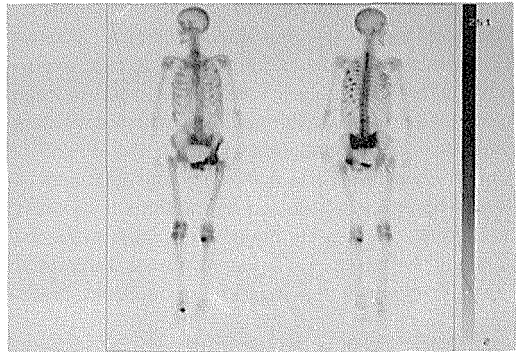
Her main complaint was pain in her hips, spine, legs and thorax for two years which worsened with weather changes.

Clinical examination showed 1x1cm elastic lump in the right breast; the mobility in the left hip was painful and limited, she was limping.

Pathologic laboratory findings were as follows: elevated serum chlorides (107 mmol/l), elevated alkaline phosphatase (4.42  $\mu$ kat/l), lowered serum calcium (2.0 mmol/l).

Mammography and ultrasound guided fine needle aspiration biopsy of the lump in her left breast were negative for carcinoma, but showed benign dysplasia.

On bone scintigraphy accumulation of the isotope was seen in the ribs, sacrum, sacroiliac joints, head of the left femur, os pubis and proximal epiphysis of left tibia (Figure 2).

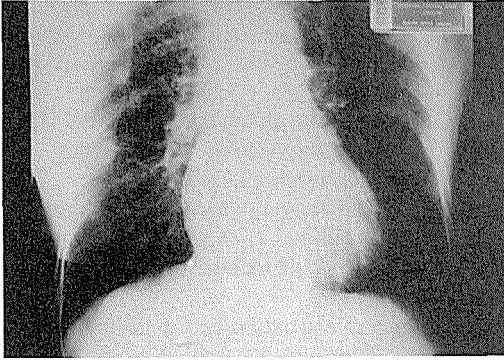


**Figure 2.** Increased uptake in the ribs, sacrum, sacroiliac joints, head of the left femur, os pubis, knees, small joints of the right foot and along both femurs – fractures? The scintigram is not typical for osseous metastases.

On bone X-rays, multiple old fractures of bilateral ribs were seen with abundant callus formation (Figure 3). In the spine, structural atrophy was seen with osteochondrosis. In the pelvis old fractures with callus formation were seen

We performed a bone marrow biopsy with a Yamshidi needle at the typical site. Aspiration of bone marrow revealed normal bone marrow with 2% of

plasma cells and histology osteomalacia. The patient was referred to an endocrinologist for therapy (vitamin D, Ca) and is doing well after one year of follow up.



**Figure 3.** Multiple fractures of ribs mainly seen on the right side with abundant callus formation.

## Discussion

Bone pain, associated with multiple bone lesions on X-ray is most often caused by metastases. In most of such cases, the treatment can only be palliative (surgery and/or radiotherapy and/or hormone or chemotherapy) and sometimes only symptomatic. Patients in whom the first manifestation of disease are bone lesions are examined for occult malignancy and if a diagnosis is not established, a bone biopsy is performed. For patients with established malignant disease and bone lesions, the diagnosis of bone metastases is usually easy and treatment is given. The aim of our case presentations is to stress some points when some doubt about such a diagnosis should be raised and some other rare differential diagnostic possibilities such as osteomalacia, entertained.

How can medical history, clinical examination and laboratory and radiological findings lead us to a diagnosis other than bone metastases in such cases?

### Medical history

The quality of bone pain is essentially the same in osteomalacia and bone metastases. The pain in osteomalacia is localized most often in the pelvis and hips<sup>2</sup> while in bone metastases the patients usually localize pain at the affected site. The duration of pain is very important. In osteomalacia it may be present for several years.

Data regarding possible abnormalities in vitamin D intake or absorption (Billroth II operation in our

second case) should lead us to more detailed investigations regarding the bone changes.

### Clinical examination

There are no essential differences in clinical evaluation of patients suffering from bone metastases, myeloma or metabolic bone disease, if we do not find obvious signs of the primary malignancy.

### Laboratory tests

Typical findings for osteomalacia are decreased values of serum calcium and phosphate and elevated alkaline phosphatase and PTH<sup>2,3</sup> which was also the case in both of our patients.

In metastatic bone disease the alkaline phosphatase is also usually elevated but hypocalcemia is rarely seen and is sometimes associated with osteoblastic metastases,<sup>4</sup> the serum calcium might be elevated, more often in association with malignancies of lung, breast, head and neck.<sup>1</sup>

Serum chloride was also increased in both of our patients probably due to secondary hyperparathyroidism.<sup>5</sup>

### Bone scintigraphy

Bone scintigraphy (with Tc<sup>99m</sup> diphosphonate) is mostly used to detect primary and secondary bone tumors, metabolic bone disease and inflammatory bone disease.

In metastatic bone disease the typical finding are multiple bone lesions of enhanced activity with asymmetric arrangement, more common in the axial part of the skeleton. The metastases may give an impression of photopenic effect.<sup>6</sup>

The lesions of osteomalacia on bone scans are very similar to metastases although they are usually more symmetric.<sup>7</sup>

Bone scan in osteomalacia demonstrates increased uptake of tracer in pseudofractures usually in the ribs when mild disease is present. In severe cases characteristic metabolic feature may be seen; increased tracer uptake in axial skeleton, in long bones, in periarticular areas, prominent calvaria and mandibule, absent kidney images, beading of costochondral junction. The same pictures may be found in other metabolic diseases and in metastases. While the bone scan is nonspecific, there are often seen recognizable patterns of abnormality and may strongly suggest (not confirm) a specific diagnosis.<sup>8</sup>

The scintigraphy is non-specific. A comparison with skeletal x-ray is necessary.<sup>9</sup>

As a detecting method for pseudofractures bone scintigraphy is more sensitive than x-ray.<sup>7,8,10</sup>

### Skeletal X-rays

A definite x-ray diagnosis of osteomalacia is not easy. The bone density is usually diffusely diminished.

Radiographic findings include a decrease in bone density, loss of secondary trabeculae with prominence of the remaining primary trabeculae, blurred, indistinct cortical margins, and characteristics pseudofractures or Looser zones (unmineralized osteoid seams) which are typically symmetrical in distribution, and most frequently seen in the axillary margin of the scapula, femoral neck, pubic and ischial rami, and ribs oriented at 90° to the cortical margin.<sup>11-12,13</sup> Specific signs of hyperparathyroidism as subperiosteal erosions, especially of the phalanges, long bones and distal ends of the clavicles are in the severe cases often present.<sup>14</sup>

### Bone biopsy

Bone biopsy with Yamshidi needle (from spina iliaca posterior superior under local anesthesia) is adequate for metabolic and infiltrative bone marrow disease and thus decreases the need and importance of some complex biochemical and radiological procedures. The frozen section can be used for fluorescent microscopy, enzyme and immunohistochemical procedures. The method can be performed in any histologic laboratory with a cryostat and the diagnosis can be established quickly.<sup>15</sup> Bone biopsy performed in this manner cannot confirm the bone metastases (unless they are localized right at the site of biopsy) but can disclose a number of metabolic and infiltrative bone diseases - in our cases osteomalacia. Bone biopsy may be combined with tetracycline labeling.<sup>5</sup>

### Conclusion

Osteomalacia is a rare disease, and may on occasion be confused with metastatic bone disease. However, there are some clues that might lead us to the right direction, or at least shed some doubt into the diagnosis of bone metastases. From our cases such clues are: long history of pain and hypocalcemia with hypophosphatemia and elevated serum alkaline phosphatase. In the first case there were quite typical radiological findings, in the second case it

was only after biopsy that a diagnosis was made. Bone biopsy seems a simple and reliable method to diagnose osteomalacia.

### References

1. Rosier RN, Boros L, Kanski A. Bone tumors. In: Rubin P ed. *Clinical oncology*. Philadelphia: W.B. Saunders Company, 1993: 509-30.
2. Krane MS, Holick MF. Metabolic bone disease. In: Isselbacher KJ, Adams RD, Braunwald E, Petersdorf RG, Wilson JD, Martin JB, Fauci AS, eds. *Harrisons principles of internal medicine*. New York: McGraw-Hill, 1991: 1921-33.
3. Rosenthal NR. Metabolic bone disease. In: Dugdale DC, Eisenberg MS, eds. *Medical diagnostics*. Philadelphia: W.B. Saunders Company, 1992: 456-60.
4. Buskin P. Hypocalcemia associated with metastatic bone disease. *Arch Intern Med* 1973; **132**: 539-47.
5. Wallach J. *Interpretation of diagnostic tests*. Boston: Little, Brown and Company, 1996: 47-279.
6. Mc Afee JG. Radionuclide imaging in metabolic and systemic skeletal diseases. *Seminars in Nuclear Medicine* 1987; **17**: 334-9.
7. Singh BN, Spies SM, Mehta SP, et al. Unusual bone scan presentation in osteomalacia: Symmetrical uptake-A suggestive sign. *Clin Nucl Med* 1978; **3**: 292-5.
8. Fogelman I, McKillop JH, Greig WR, et al. Pseudofracture of the ribs detected by bone scanning. *J Nucl Med* 1977; **18**: 1236.
9. Velchik MG, Makler PT, Alvi A. Osteomalacia. An Inposter of osseus metastasis. *Clin Nucl Med* 1985; **10**: 783-5.
10. Macfarlane JK, Lutkin JE, Burwood A. The demonstration by scintigraphy of fractures in osteomalacia. *Br J Radiol* 1977; **50**: 369.
11. Edeiken J. Metabolic and dystrophic bone disease. In: Edeiken J, ed. *Roentgen diagnosis of disease of bone*. Baltimore: Williams & Wilkins, 1981: 829-1046.
12. Rosenthal L, Lisbona R: Metabolic bone disease. In: Rosenthal L, Lisbona R, eds. *Skeletal imaging*. Norwalk: Appleton- Century- Crofts, 1984: 225-42.
13. Pitt MJ: Rickets and osteomalacia. In: Resnick D, Niwayama G, eds. *Diagnosis of bone and joint disorders with emphasis on articular abnormalities*. Philadelphia: W B Saunders, 1981: 1683-1713.
14. Alper SL, Lodish HF. Disorders of the kidney and urinary tract. In: Isselbacher KJ, Adams RD, Braunwald E, Petersdorf RG, Wilson JD, Martin JB, Fauci AS, eds. *Harrisons principles of internal medicine*. New York: McGraw-Hill, 1991: 1131-218.
15. Stevens A, Palmer J. Frozen sections of bone biopsies in metabolic and other bone diseases. *Histopathology* 1985; **9**: 315-4.