

Malignant bone tumours of the extremities: The role of limb sparing surgery

M. Čuček-Pleničar,¹ J. Novak,² M. Špiler,² B. Baebler,¹ J. Červek,² J. Lamovec²

¹University Orthopaedic Hospital, ²Institute of Oncology, Ljubljana, Slovenia

The aim of our retrospective analysis was to evaluate the treatment outcome in 88 patients with malignant bone tumours of extremities treated in Ljubljana between 1980 and 1995. The histologic type of tumours were: osteogenic sarcoma 61, chondrosarcoma 12, Ewing sarcoma 4, PNET 2, malignant giantocellular tumour 2 and unclassified malignant tumour in 7. Of these 40 were resected and 48 amputated. The percentage of amputations is decreasing by time (first 5 year period 74%, second 46% and third 42%). The overall survival at ten years for the resected patients is 60% and for the amputated 50%, while these figures for patients with osteosarcoma are 52% and 34% respectively. We could achieve an improvement of our results with strict use of core needle biopsies, application of more effective chemotherapy preoperatively and multidisciplinary surgical approach.

Key words: bone neoplasms; amputation; extremities; survival rate

Introduction

With the development of effective preoperative chemotherapy for malignant bone tumours limb sparing procedures replaced amputations in an important percentage of patients.¹

The aim of our retrospective analysis was to evaluate the treatment outcome in patients with malignant bone tumours of extremities treated in Ljubljana between 1980 and 1995.

Patients and methods

During this period 88 patients with malignant bone tumours of extremities underwent treatment. Chemotherapy was administered at the University Paediatric Hospital or Institute of Oncology,

Ljubljana. Surgery was performed at the University Orthopaedic Hospital with a combined team consisting of an oncological surgeon who performed the resection of the tumour, and orthopaedic surgeon for reconstruction. Of the 88 patients treated 40 had a limb sparing procedure (15 males, 25 females, age 9 to 64 years, median 21 years), and 48 were amputated (32 males, 15 females, age 6 to 68 years, median 25 years). Tables 1, 2 and 3 show the distribution of TNM Stage,² site and histology between the resected and amputated patients. Table 4 shows the distribution of TNM Stage in osteogenic sarcoma patients for whom follow-up data are available. In the resected patients the preoperative diagnosis was obtained by open biopsy in 20 and by core needle biopsy in 20 patients. In the amputated patients the preoperative diagnosis was obtained by open biopsy in 33 and by core needle biopsy in 15. Preoperative histology erroneously classified 3 cases of classical osteogenic sarcomas as paraosteal osteogenic sarcomas. Preoperative chemotherapy was administered in 26/40 resected patients and in 29/48 amputated patients.

Correspondence to: Dr. M. Čuček-Pleničar, University Orthopaedic Hospital, Zaloška 9, SI-1000 Ljubljana, Slovenia

UDC: 616.717/718-006.6-089.87

Table 1. Distribution of all patients by TNM Stage and type of surgery

	Ia	Ib	IIa	IIb	IVa	IVb	All
Resections	2	5	12	19	0	2	40
Amputations	1	6	1	36	1	3	48
All	3	11	13	55	1	5	88

Table 2. All patients by site of primary tumour and type of surgery

	Resections	Amputations	All
Distal femur	21	23	44
Proximal femur	2	1	3
Distal tibia	2	5	7
Proximal tibia	6	15	21
Humerus	8	4	12
Other	1	0	1
All	40	48	88

Table 3. All patients by histology and type of surgery

	Resections	Amputations	All
Osteogenic sarcoma	22	31	53
Paraosteal osteogenic sarcoma	6	2	8
Chondrosarcoma	7	5	12
Ewing sarcoma	2	2	4
PNET	1	1	2
Gigantocellular tumour	1	1	2
Unclassified malignant tumour	1	6	7
All	40	48	88

Table 4. Distribution of osteogenic sarcoma patients with available follow-up information by TNM Stage and type of surgery

	Ia	Ib	IIa	IIb	IVa	IVb	All
Resections	1	2	5	15	0	2	25
Amputations	0	2	1	22	1	3	29
All	1	4	6	37	1	5	54

Surgery in resected patients

After resection of the tumour the reconstruction was performed with endoprosthesis in 24, in 3 with rotation plasty tibia pro femur, in 3 with autograft fibula pro humerus (two of them with vascularized graft and microsurgery) in 7 patients with a combination of auto and homografts. In 3 patients expendable bones (2 fibulas, 1 clavicle) were resected.

Surgery in amputated patients.

5/48 patients had pathologic fractures at the site of the tumour, in 13/48 patients an inadequate surgical procedure was performed previously (excochleation of the tumour) elsewhere, and in 3 patients there was a rapid progression despite chemothera-

py. All others had large advanced tumours and a resection was not feasible.

Results

Table 5 shows the grade of necrosis after preoperative chemotherapy (almost all osteogenic sarcoma patients) in resected and amputated patients.

Table 5. Effect of preoperative chemotherapy and type of surgery performed

	Grade I	Grade II	Grade III	Grade IV	All
Resection	5	9	5	7	26
Amputation	14	8	3	1	29
All	19	17	8	8	53

Out of the 40 resected patients 26 are alive, one of these with pulmonary metastases, 10 patients died and 4 are lost to follow-up. Causes of death were local recurrence and generalised disease in 5 and generalised disease in 5 patients. In the group of 26 survivors there were 10 patients with grade III and IV response to preoperative chemotherapy whereas in 10 patients who died only one had grade IV response. Complications after surgery occurred altogether in 12/40 patients and were as follows: local infection requiring amputation in 2 patients, 3 loosening of the prosthesis requiring replacement and fracture of the prosthesis in 1 patient. There were 7 local recurrences. In 4 of these amputations were performed, 2 patients refused further treatment.

Out of the 48 amputated patients 20 are alive without evidence of disease, 4 are alive with metastatic disease, 17 patients died and 7 are lost to follow up. Causes of death were local recurrence and generalised disease in 2 patients, and generalised disease in 14, one patient died in the postoperative period due to heart failure.

In Figure 1 overall survival of all patients by type of surgical procedure is shown (Kaplan-Meyer method). In Figure 2 the same plot is shown for the patients with osteogenic sarcoma with available follow up information.

Discussion and conclusions

In our series of 88 patients with malignant bone tumours we performed limb sparing surgery only in 40 but in Figure 3 we can see that the proportion of

amputations is decreasing substantially by time. This rather low percentage of resections can be attributed to the advanced stage of tumours in our series as well as previous inadequate surgical interventions. Even in the group of patients with resections 50% had IIb or IVa stage of disease according to TNM classification.

The overall incidence of local recurrence 7/40 (17.5%) in the resected patients and 2/48 (4%) in the amputated patients is high in comparison with many similar reported series^{3,4} and could be connected either with advanced stage or poor effect of preoperative chemotherapy or high incidence of previous inadequate surgery in our series.

We could achieve an improvement of our results with strict use of core needle biopsies, application of more effective chemotherapy preoperatively and multidisciplinary surgical approach.

Resection of tumours should be performed by an oncologic surgeon and reconstruction by an orthopedic and plastic surgeon.

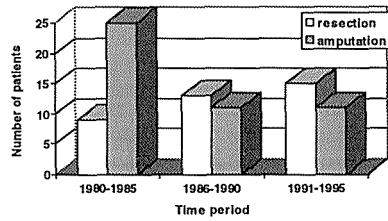


Figure 3. Proportion of amputations Vs resections in three 5-year periods from 1980 to 1995.

References

1. Glasser DB, Lane JM, Huvos AG, Marcove RC, Rosen G. Survival, prognosis, and therapeutic response in osteogenic sarcoma. *Cancer* 1992; **69**: 698-708.
2. UICC - International Union Against Cancer. TNM classification of malignant tumours, Fourth Edition, 2nd Revision. Berlin: Springer, 1992.
3. Delepine N, Delepine G, Alkallaf S et al. Prognostic factors for local relapses following sparing surgery for osteosarcoma. In: 2nd Osteosarcoma research conference. Bologna, 1996: 140.
4. Bacci G, Ferrari S, Mercuri M et al. Local relapse in primary high grade osteosarcoma of the extremities treated with neoadjuvant chemotherapy: risk factors and prognosis in the Rizzoli experience. In: 2nd Osteosarcoma research conference. Bologna, 1996: 142.

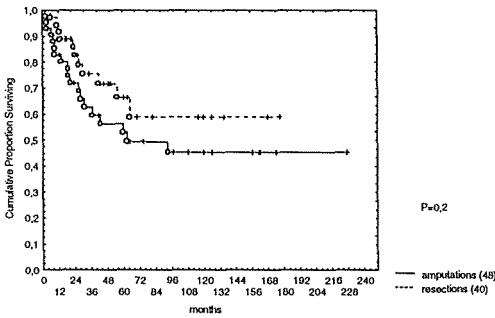


Figure 1. Overall survival of resected and amputated patients for bone sarcomas of the extremities.

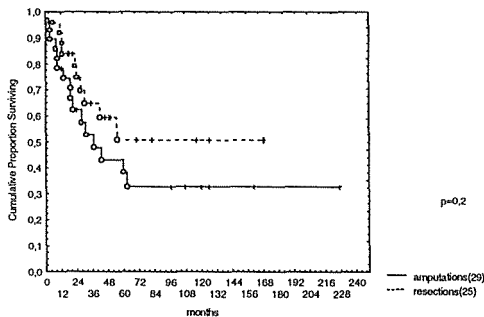


Figure 2. Overall survival of resected and amputated osteosarcoma patients.