

Eosinophilic fasciitis

A. Dugonik, M. Belič and J. Miljković

S U M M A R Y

A 58-year-old woman was evaluated for disseminated scleroderma-like skin lesion which started on lateral aspects of the upper extremities and progressed rapidly, involving trunk and lower extremities. They first skin lesions appeared one month after she had started simvastatin therapy for hypercholesterolemia. Clinical and histopathological findings corresponded to the diagnosis eosinophilic fasciitis. Methylprednisolone 60 mg per day was started; simvastatin was discontinued. After two weeks of therapy the patient became afebrile, arthralgic pains and edema of legs subsided, and skin lesions softened. The percentage of eosinophils dropped to normal. The eosinophilic fasciitis was possibly induced by the 3-hydroxy-3-methylglutaryl coenzyme A reductase inhibitor, simvastatin, an association that has been previously described.

Introduction

Eosinophilic fasciitis (EF), first described by Shulman 1974, is a rare inflammatory scleroderma-like disorder of unknown etiology characterized by symmetric painful swelling and induration involving arms and legs in association with peripheral eosinophilia (1). Rapid onset, progression and good response to the systemic corticosteroid therapy are also characteristics of the disease. A causal relationship with physical exertion has been suggested in almost half of the reported cases. The occasional presence of antinuclear antibodies and rheumatoid factor and the coexistence with autoimmune hematologic diseases suggest an autoimmune pathogenesis (2). Numerous studies have described EF in association with ingestion or exposure to environmen-

tal agents, particularly L-tryptophan. Most recently, a possible role of *Borrelia burgdorferi* infection was described (3). In addition some drug exposures have been implicated. Cutaneous side effects following simvastatin treatment, including the development EF have been well described, (4-6). Litt (7) lists 29 references mentioning side effects involving skin after simvastatin treatment.

Case report

A 58-year-old woman had a history of disseminated scleroderma-like skin changes beginning on lateral aspects of the upper extremities and progressed rapidly, involving also trunk and lower extremities (Figures 1).

K E Y W O R D S

eosinophilic fasciitis, simvastatin, adverse drug effects, scleroderma

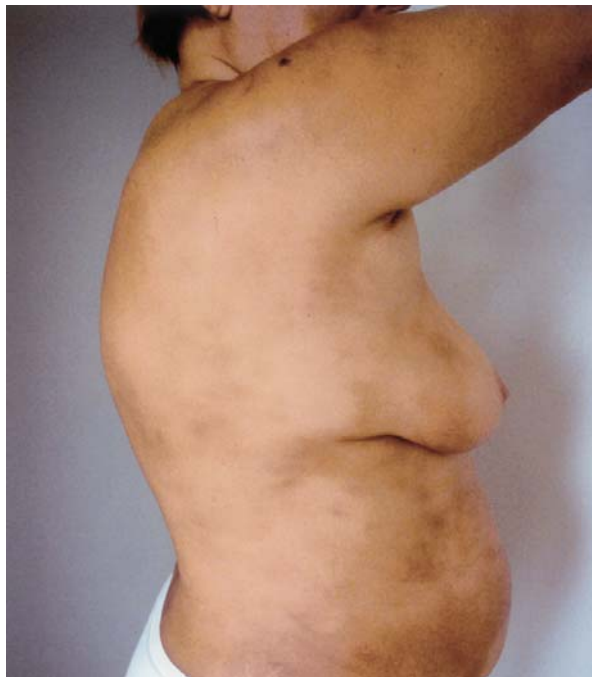

Figure 1. Eosinophilic fasciitis: disseminated scleroderma-like skin changes on the trunk and the upper extremities.

A few days later weakness and swollen extremities with arthralgia suddenly appeared. The temperature was slightly elevated. The first skin lesions appeared one month after initiation of simvastatin therapy for hypercholesterolemia. She had no history of atopy and could not remember a tick bite. Since 1997 idiopathic ventricular tachycardia had been diagnosed, for which therapy with verapamil was initiated.

Laboratory tests showed an elevated erythrocyte sedimentation rate of 40 mm/h, and a total peripheral blood leukocyte count $10.9 \times 10^9/L$ with 28% eosinophils. Antinuclear antibodies were positive (1:320 homogenous pattern), tests for antibodies to extractable nuclear antigen and Scl 70 as well as tests for syphilis were negative. Protein and immunoelectrophoresis, liver function tests, as well as serum levels of creatininkinase, lactic acid dehydrogenase and aldolase remained within the normal range. PCR on *Borrelia burgdorferi* was negative. Bacterial, viral and parasite serologic tests were all negative. Routine tests of urine and feces were negative; the same were urine, feces and blood cultures. Tumor markers were within normal limits. The chest x-ray, mammography, abdominal and cardiac ultrasound, electrocardiography, spirometry and testing by barium swallowing were normal.

The skin biopsy specimen revealed a typical pattern of scleroderma. Epidermis was normal; an inflammatory perivascular, superficial and deep infiltrate with eosinophils, lymphocytes, plasma cells and histiocytes was present in the dermis. Collagen bands in the der-

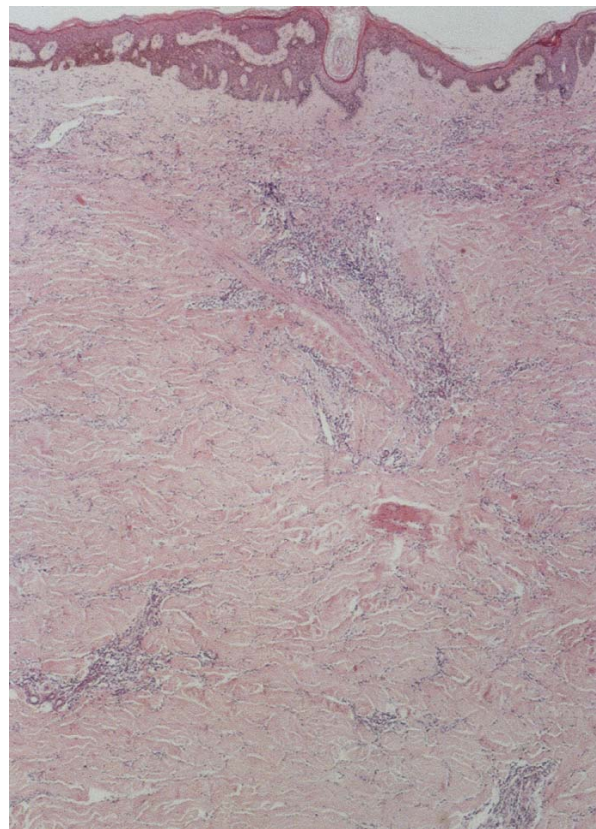


Figure 2. Eosinophilic fasciitis: Scanning magnification revealed typical pattern of scleroderma (hematoxylin-eosin, 40 x).

mis were hyalinized and sclerotic. Subcutaneous septa and muscular fascia were thickened, infiltrated by many eosinophils, some lymphocytes and plasma cells (Figures 2-4).

Methylprednisolone 60 mg per day was started; simvastatin was discontinued. After two weeks of therapy the patient became afebrile, arthralgic pains and edema of legs subsided, skin lesions softened. The percentage of eosinophils dropped to the normal.

Discussion

EF is an uncommon inflammatory disorder of unknown etiology. The patient usually first experiences pain, swelling and tenderness of proximal aspects of the limbs, chest or neck, with subsequent induration of the skin and subcutaneous tissues, in association with peripheral eosinophilia. Visceral involvement is rare. Although clinically resembling progressive systemic sclerosis, eosinophilic fasciitis bears many unique features and is now considered by most authors to be a separate disease (8).

The absence of Raynaud's phenomenon and scler-

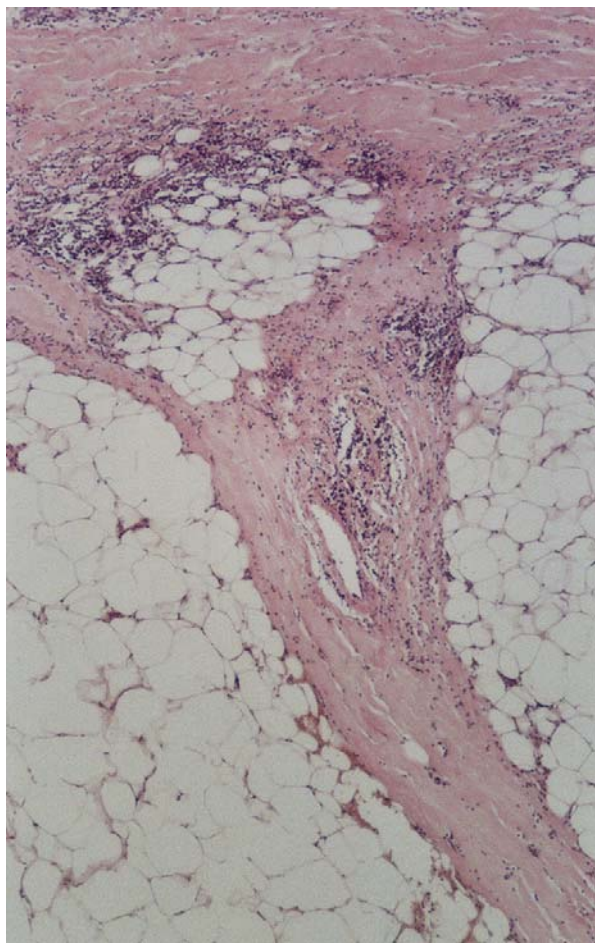


Figure 3. Eosinophilic fasciitis: Superficial and deep infiltrate with lymphocytes, plasma cells and eosinophils was present in the dermis; collagen bands were hyalinized and sclerotic (hematoxylin-eosin, 100 x).

rodactly are useful distinguishing features from scleroderma.

Laboratory examinations in early active disease show eosinophilia, an elevated ESR, and polyclonal IgG hypergammaglobulinemia. Antinuclear antibodies and rheumatoid factor are usually absent. Nonspecific electromyographic changes may be seen.

Biopsy is the most important diagnostic procedure for EF. Histopathological examination reveals a normal epidermis and an inflammatory infiltrate with lymphocytes, plasma cells, histiocytes and eosinophils in the dermis, subcutaneous tissue, septa, fascia and muscles. Subsequently fibrosis and sclerosis of septa in the subcutaneous fat develop.

The etiology of EF remains unknown. A causal relationship with physical exertion has been suggested in almost half of the reported cases. In addition, the occasional presence of antinuclear antibodies and rheumatoid factor and the coexistence with autoimmune he-

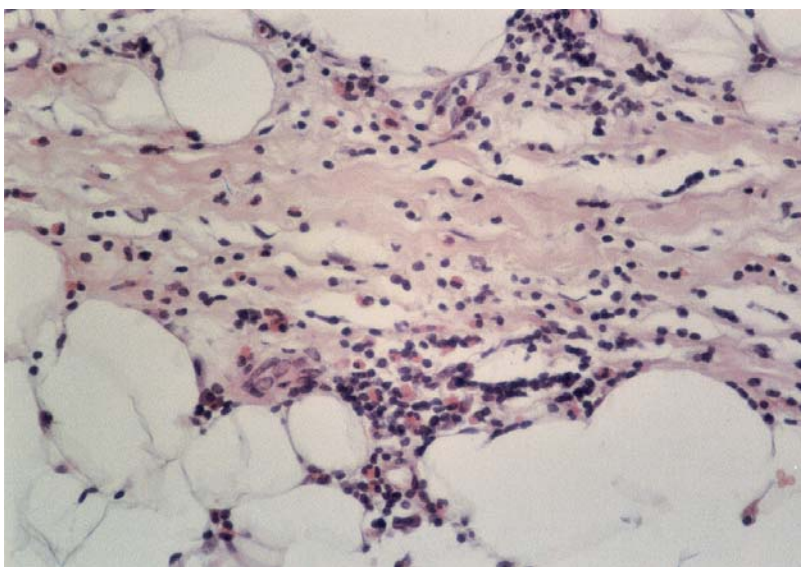
matologic diseases, suggest an autoimmune pathogenesis. Numerous studies have described an association with the ingestion or exposure to environmental agents, particularly L-tryptophan. Most recently, a role of *Borrelia burgdorferi* infection was described. (9). Recent reports showed that in vitro fibroblasts from involved fascia produce increased levels of mRNA for collagen types I, II and IV compared to adjacent dermal fibroblasts. The facial fibroblasts express transforming growth factor (TGF) beta I and connective tissue growth factor (CTGF) mRNA, which may account for the clinical fibrosis. Eosinophilic degranulation may lead to fibroblast activation (10).

Specifically, EF is clinically characterized by rapid onset and progression and often responds favorably to systemic corticosteroid therapy. Most patients respond rapidly to high doses of prednisolone 0.5-1.0 mg/kg/day followed by rapid reduction to 5 to 10mg/day. Continued low doses may be required for 2-5 years. Adjuvantive medications include hydroxychloroquine, cyclosporine, azathioprine and methotrexate (11,12).

Clinical and histopathological findings in this case correspond to the diagnosis EF. There was no suspicion of relevant environmental or toxic exposure. Paraneoplastic disease, progressive systemic sclerosis and Lyme borreliosis were excluded. The absence of any other etiological factor suggests that simvastatin might be the causative factor in this case. Verapamil could be also incriminated, but this is less probable.

Simvastatin is a lipid regulating drug and is a competitive inhibitor of 3-hydroxy-3-methylglutaryl coenzyme A reductase (HMG-CoA reductase), the rate-de-

Figure 4. Eosinophilic fasciitis: Subcutaneous septa and muscular fascia, infiltrated by lymphocytes, plasma cells and many eosinophils (hematoxylin-eosin E 400 x).



termining enzyme for cholesterol synthesis. HMG-CoA reductase inhibitors reduce total cholesterol, low-density lipoprotein (LDL)-cholesterol, and very-low-density lipoprotein (VLDL)-cholesterol concentrations in plasma. They also tend to reduce triglycerides and to increase high-density lipoprotein (HDL)-cholesterol concentrations.

Simvastatin is used to reduce LDL-cholesterol, apolipoprotein B, and triglycerides, and to increase HDL-cholesterol in the treatment of hyperlipidemias, including hypercholesterolemias and mixed hyperlipidemia. Simvastatin is also given prophylactically to hypercholesterolemic patients with ischemic heart disease (14,15).

The commonest adverse effects of therapy with

simvastatin are gastrointestinal disturbances, headache, skin rashes, dizziness, angioedema, proteinuria, purpura, depression and insomnia.

Hepatitis and pancreatitis also have been reported. Myopathy characterized by myalgia and muscle weakness and associated with increased creatine phosphokinase concentrations, has been reported (16).

The history and the course of the disease, histopathology, and very good response to the prednisolone therapy confirm the diagnosis of EF in this case. Our experience and a review of other cases described, suggest that simvastatin is the most likely the causative factor in the etiology of the EF.

REFERENCES

1. Shulman LE. Diffuse fasciitis with hypergammaglobulinemia and eosinophilia: a new syndrome? *J Rheumatol* 1974; 2: 569-70.
2. Kent LT, Cramer SF, Moskowitz RW. Eosinophilic fasciitis; clinical laboratory, and microscopic considerations. *Arthritis Rheum* 1981; 24: 677-83.
3. Maddison PJ. Eosinophilic fasciitis. *Br J Rheumatol* 1990; 29: 81-2.
4. Choquet-Kastylevsky G, Kanitakis J, Dumas V, et al. Eosinophilic fasciitis and simvastatin. *Arch Intern Med* 2001; 161: 1456-7.
5. Silver RM, Heyes MP, Maize JC et al. Scleroderma, fasciitis and eosinophilia associated with the ingestion of tryptophan. *N Engl J Med* 1990; 322: 874-81
6. Hibbs Jr, Mittelman B, Hill P, Medsger T.A.L-tryptophan associated eosinophilic fasciitis prior to the 1989 eosinophilia-myalgia outbreak. *Arthritis Rheum* 1992; 35: 299-303.
7. Litt JZ. *Drug Eruption Reference Manual*. 8th ed, Parthenon Publishing Group, Boca Raton, 2002: 377-8.
8. Varga J, Griffin R, Newman JH, Jimenez SA. Eosinophilic fasciitis is clinically distinguishable from the eosinophilic syndrome and is not associated with L-tryptophan use. *J Rheumatol* 1991; 18: 259-63.
9. Varga J, Kahari VM. Eosinophilia-myalgia syndrome, eosinophilic fasciitis and related fibrosing disorders. *Curr Opin Rheumatol* 1997; 9: 562-70.
10. Kahari V-M, Heino J, Niskanen L et al. Eosinophilic fasciitis. Increased collagen production and type I procollagen messenger RNA levels in fibroblasts cultured from involved skin. *Arch Dermatol* 1990; 126: 613-17.
11. Lakhnani S, Ginsburg WW, Michet CJ et al. Eosinophilic fasciitis: clinical spectrum and therapeutic response in 52 cases. *Semin Arthritis Rheum* 1988; 17: 221-31.
12. Valencia I, Chang A, Kirsner R, Kerdel F A. Eosinophilic fasciitis responsive to treatment with pulsed steroids and cyclosporine. *Int J Dermatol* 1999; 38: 367-72.
13. Farrel AM, Ross JS, Bunker CB. Eosinophilic fasciitis associated with autoimmune thyroid disease and myelodysplasia treated with pulsed methylprednisolone and antihistamines. *Br J Dermatol* 1999; 140: 1185-7.
14. Mauro VF. Clinical pharmacokinetics and practical applications of simvastatin. *Clin Pharmacokinet* 1993; 24: 195-202.
15. Lennernas H, Fager G. Pharmacodynamics and pharmacokinetics of the HMG-CoA reductase inhibitors. *Clin Pharmacokinet* 1997; 32: 403-25.
16. Adverse Drug Reactions Advisory Committee (ADRAC). Fluvastatin and muscle disorders, a class effect. *Aust Adverse React Bull* 1997; 16:3.

AUTHORS' ADDRESSES

Aleksandra Dugonik, MD, Department of Dermatology, General Hospital Maribor, Ljubljanska 5, 2000 Maribor, Slovenia
Mirjam Belič, MD, same address
Jovan Miljković, MD, M.Sc, Head of the Department, same address.