

# *Otitis externa and myringitis due to demodicidosis*

E. Klemm, G. Haroske, and U. Wollina

---

## S U M M A R Y

We report on an 84-year-old woman with chronic pruritic otitis externa and myringitis. Microbiological and mycological investigations failed to establish the cause, but histology revealed a large amount of *Demodex* mites. Topical treatment for this ectoparasite resulted in a complete remission. The myringitis was eventually treated successfully with myringoplasty. To the best of our knowledge this is the first case report on *Demodex*-induced otitis externa and myringitis.

---

## *Introduction*

*Demodex folliculorum* and *Demodex brevis* are saprophytic mites of the human pilosebaceous unit. Demodicidosis is the most common ectoparasitosis in humans. The mites are 0.3 to 0.4 mm long with four pairs of short, clawed legs. Infestation occurs by direct contact. *D. folliculorum* remain in the glandular ducts. *D. brevis* are found within the sebaceous glands themselves. Adult mites develop from eggs, passing through a larval stage and reaching maturity within 15 days. The preferred localization is facial skin, including the eyelids, because of the numerous sebaceous glands in this area.

*Demodex* mites are more commonly seen in rosacea skin, where they can rarely be involved in

granuloma formation (1).

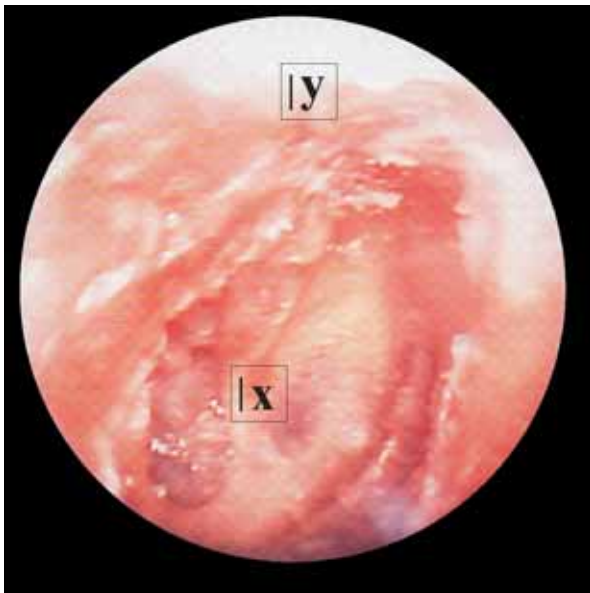
*Demodex* mites rarely cause cutaneous symptoms, but in immunocompromised patients of all ages these ectoparasites are involved in rosacea-like demodicidosis, blepharitis, follicular pityriasis, pustular folliculitis, and granulomatous rosacea (2–5). Rare manifestations include favus-like demodicidosis and nipple demodicidosis (6, 7).

## *Case report*

We report on an 84-year-old woman that presented in 2003 with otitis externa, myringitis of the right ear,

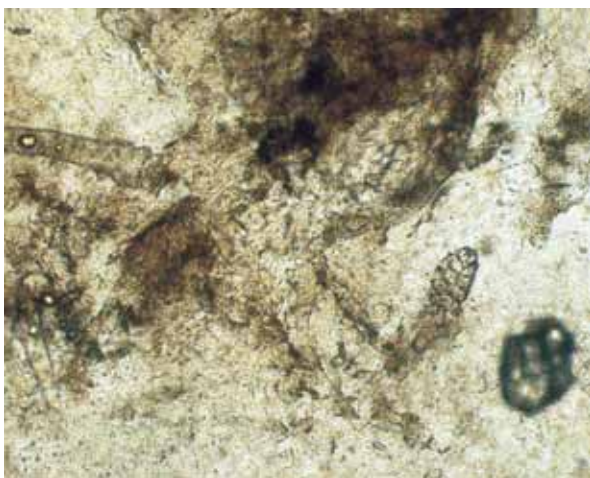
## **K E Y W O R D S**

**myringitis,  
otitis externa,  
otitis media,  
*Demodex* mite**



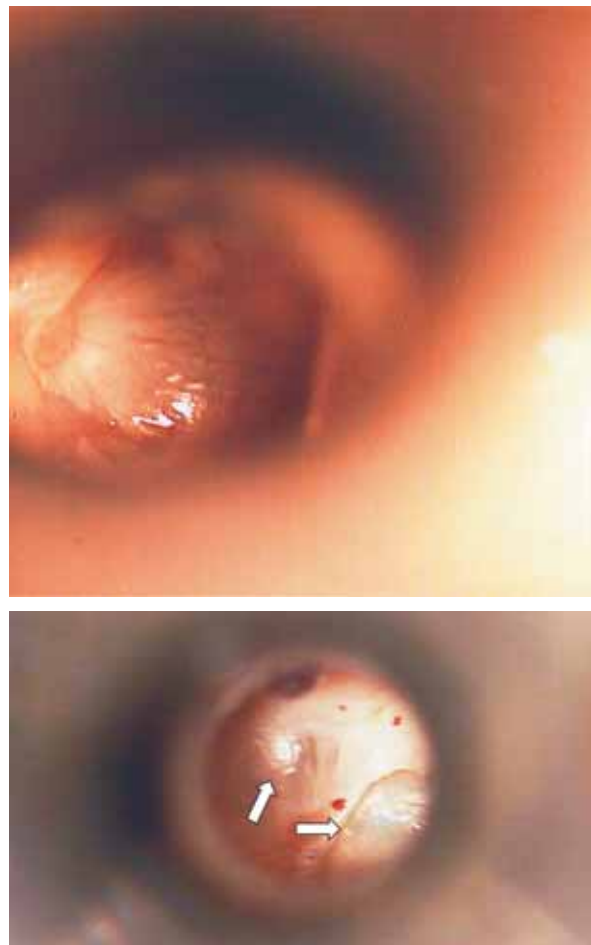
**Fig. 1: Myringitis, presentation before treatment. (x) Perforation of the ear-drum. (y) Biopsy area.**

and a chronic cholesteatoma. She had undergone a mastectomy many years ago. On the tympanic membrane calcium streak-like lesions were visible, with an increase in epithelial desquamation and erythema (Fig. 1). Bacteriological and mycological investigations were negative. Histology of the external auditory meatus and the tympanic membrane demonstrated numerous *Demodex* mites with an ongoing non-specific inflammatory response (Fig. 2).



**Fig. 2: Multiple *Demodex* mites in a biopsy of the tympanum epithelium (original magnification x 4).**

Treatment was performed with topical hexachlorocyclohexane (Jacutin®, Hermal, Reinbeck, Germany) once a day for 10 days. Subsequent testing showed a complete eradication of the mites. Thereafter the patient underwent a myringoplasty to reconstruct the ear-drum and the stapedius (Fig. 3). Follow-up investigations showed a remission of all symptoms and a normal clinical situation of the right ear 1 year later. To date, she has not experienced a relapse.



**Fig. 3: Ear-drum perforation. (a) After topical treatment but before surgical intervention; (b) Closed ear drum defect after myringoplasty (Arrows show the light reflexes of the flash gun).**

*Discussion*

The external auditory meatus is rich in ceruminous glands. These modified apocrine glands, together with sebaceous glands, produce cerumen (8). Cerumen

plays an important role in the innate immunity of the ear canal to physical damage and microbial invasion. Among other factors, antimicrobial peptides such as beta-defensin-1 and beta-defensin-2, cathelicidin, lysozyme, lactoferrin, and the secretory component of IgA have been indentified (9, 10). Cerumen inhibits the growth of bacteria such as *Staphylococcus aureus* and *Pseudomonas aeruginosa*, as well as yeasts such as *Candida albicans* (11). These factors might also be responsible for the prevention of demodicidosis.

Chronic cholesteatoma and the subsequent pathologies may severely impair the local innate defense system. Demodicidosis of the ear and the tympanum has not gained attention in the dermatological literature. In a recent survey of 613 students in China, *Demodex* mites were found in 11.6%. Two-thirds of these cases were accompanied by scratching and pruritus (12).

Here we describe a case of demodicidosis presenting as otitis externa and myringitis. Chronic myringitis is

defined as the loss of tympanic membrane epithelium for more than 1 month without disease in the tympanic cavity. The prevalence of myringitis is about 1% in ENT departments (13). In myringitis and otitis externa, epithelial renewal and migration is delayed (14). In this case, demodicidosis was the only pathologic finding.

We could not identify a single other case of myringitis caused by *Demodex* mites in the international literature. Scratching and pruritus was a symptom in our patient, but impaired hearing was the leading symptom that brought the patient to the ENT department. Topical therapy caused a remission and the tympanic membrane defect was able to be closed by myringoplasty (15).

Although topical hexachlorocyclohexane is no longer on the German market, this case illustrates that a topical treatment (today probably with permethrin) is sufficient to eradicate the infestation and lead to a complete resolution of symptoms.

## REFERENCES

1. Salfelder K, de Liscano TR, Sauersteig E. Atlas of Parasitic Pathology. London: Springer; 1992. 192 p.
2. Cockerell CJ. Parasitic infections and ectoparasitic infestations. J Int Assoc Physicians AIDS Care. 1995;1:20–2.
3. Baima B, Sticherling M. Demodicidosis revisited. Acta Derm Venereol. 2002;82:3–6.
4. Morrás PG, Santos SP, Imedio IL, Echeverría ML, Hermosa JM. Rosacea-like demodicidosis in an immunocompromised child. Pediatr Dermatol. 2003;20:28–30.
5. Karıncaoglu Y, Bayram N, Aycan O, Esrefoglu M. The clinical importance of Demodex folliculorum presenting with non-specific facial signs and symptoms. J Dermatol. 2004;31:618–26.
6. García-Vargas A, Mayorga-Rodríguez JA, Sandoval-Tress C. Scalp demodicidosis mimicking favus in a 6-year-old boy. J Am Acad Dermatol. 2007;57 Suppl 2C:S19–S22.
7. Jansen T, Becjara FG, Stücker M, Altmeyer P. Demodicidosis of the nipple. Acta Derm Venereol. 2005;85:186–7.
8. Testa-Riva F, Puxeddu P. Secretory mechanisms of human ceruminous glands: a transmission and scanning electron microscopic study. Anat Rec. 1980;196:363–72.
9. Stoeckelhuber M, Matthias C, Andratschke M, Stoeckelhuber BM, Koehler C, Herzmann S, Sulz A, Welsch U. Human ceruminous gland: ultrastructure and histochemical analysis of antimicrobial and cytoskeletal components. Anat Rec A Discov Mol Cell Evol Biol. 2006;288:877–84.
10. Yoon YJ, Jin Woo Park JW, Lee EJ. Presence of hBD-1 and hBD-2 in human cerumen and external auditory canal skin. Acta Otolaryngol. 2008;128:871–5.
11. Lum CL, Jeyanthi S, Prepageran N, Vadivelu J, Raman R. Antibacterial and antifungal properties of human cerumen. J Laryngol Otol. 2008;11:1–4.
12. Ding Y, Huang X. Investigation of external auditory meatus secretion. *Demodex folliculorum* and *Demodex brevis* infection in college students [Chinese]. Lin Chuang Er Bi Yan Hou Ke Za Zhi. 2005;19:176–7.

13. Blevins NH, Karmody CS. Chronic myringitis: prevalence, presentation, and natural history. *Otol Neurotol.* 2001;22:3–10.
14. Saad EF. The epidermis of the drumhead in some otological conditions. *Arch Otolaryngol.* 1977;103:387–8.
15. Gersdorff M, Garin P, Decat M, Juantegui M. Myringoplasty: long-term results in adults and children. *Am J Otol.* 1995;16:532–5.

**A U T H O R S ' A D D R E S S E S** *Eckart Klemm, Department of Head and Neck Surgery, Dresden-Friedrichstadt Hospital, Academic Teaching Hospital of the Technical University of Dresden, Friedrichstrasse 41, 01067 Dresden, Germany, E-mail: klemm-ec@khdf.de*  
*Gunter Haroske, Georg Schmorl Institute of Pathology, Dresden-Friedrichstadt Hospital, Academic Teaching Hospital of the Technical University of Dresden, same address, E-mail: haroske-gu@khdf.de*  
*Uwe Wollina, MD, Department of Dermatology and Allergology, Dresden-Friedrichstadt Hospital, Academic Teaching Hospital of the Technical University of Dresden, same address, corresponding author, E-mail: wollina-uw@khdf.de*