

case report

Doppler ultrasound in the diagnosis and follow-up of the muscle rupture and an arteriovenous fistula of the thigh in 12 year boy

Zlatko Pavčec¹, Ivan Žokalj¹, Hussein Saghir¹, Andrej Pal¹, Goran Roic²

¹Department of Radiology and Ultrasound, Čakovec County Hospital, Čakovec

²Department of Pediatric Radiology, Children's Hospital, Zagreb, Croatia

Background. With this case report the authors wish to present the accuracy of non-invasive vascular imaging methods, especially Doppler ultrasound, in the evaluation of the muscular trauma and periskeletal soft tissue vascular anomalies.

Case report. Twelve year-old boy has been admitted with the right femoral quadriceps muscle traumatic rupture. Postoperative B-mod sonography (US) visualised recidivuous haematoma and Power Doppler depicted hypervascularized area, suspected vascular malformation (angioma). Doppler findings obtained on the right thigh vasculature gave us reasons to think about posttraumatic arteriovenous fistula. Doppler has been repeated in the specialized paediatric institution with the same results. Digital subtraction angiography, 8 months after trauma, did not confirm suspicions reported in US findings. Spiral computed tomographic angiography (CTA) performed 11 months after trauma clearly depicted a lesion which had been repeatedly described in US findings. Fourteen months after trauma the vascular surgeon performed the deep femoral artery muscular branches ligation, but in the official report only arteriovenous fistula was mentioned. After the surgery the patient was clinically better. The aetiology of the right femoral arteriovenous fistula and hypervascularized structure remains unclear.

Conclusions. Every inadequately behaving, recidivuous posttraumatic haematoma should be evaluated with Doppler ultrasound. CTA can be performed if it is needed to clarify US findings.

Key words: hematoma – ultrasonography; arteriovenous fistula; muscle, skeletal - injuries

Introduction

Soft tissue injury and its complications can be accurately evaluated with ultrasonography (US) because this method has possibilities of multiplanar approach, the dynamic examination of muscle during the contraction and rest and assessment of the potential concomitant vascular injury with Doppler modalities.¹⁻⁴ US doesn't carry

Received 24 November 2006

Accepted 2 December 2006

Correspondence to: Ivan Žokalj, MD, Department of Radiology and Ultrasound, Čakovec County Hospital, Ivana Gorana Kovačića 1e, 40 000 Čakovec, Croatia; Phone: + 385 40 375 297; Fax: + 385 40 313 325; E-mail: ivan.zokalj@ck.t-com.hr

danger of ionizing radiation and it is widely available; these facts make US the imaging method of choice for the diagnostic evaluation of muscular injuries and first method for vascular injury diagnosing.

A muscle rupture of the lower limbs with consequent haematomas is often related with a sports injury. Haematoma is the most important sign of a muscle rupture, it is usually depicted as a hypo- or anechoic circumscribed lesion¹⁻³ an arteriovenous (AV) fistula is an abnormal communication between the arterial and venous systems. AV fistulas of the extremities are the consequence of trauma or medical procedures in most of the cases. Post-traumatic AV fistula is usually the consequence of penetrating trauma, very rarely after blunt trauma.⁵⁻⁷

Non-invasive imaging diagnostic methods, such as US, computed tomography (CT) and magnetic resonance imaging (MRI) have big potentials for the safe and even quick assessment of vascular anomalies and traumatic vascular lesions.⁸ Doppler ultrasound methods can give the majority of necessary information about traumatic vascular lesions and vascular anomalies, especially if US is combined with another vascular imaging method, such as computed tomographic angiography (CTA) and magnetic resonance angiography (MRA).^{3,4,9-12}

Case report

Twelve year-old boy was admitted with signs of the right femoral quadriceps muscle traumatic rupture caused by sudden extension during the football match, six months after trauma actually happened. B-mod US, performed before the surgical intervention showed the right femoral quadriceps muscle rupture with haematoma. First postoperative US included B-mod and Doppler modalities (colour and power

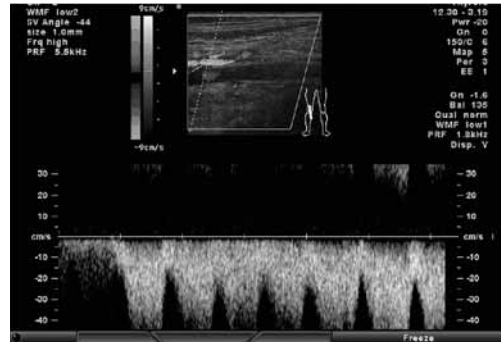


Figure 1. First Doppler ultrasound registered high flow and high systolic peak values in the popliteal, superficial and deep femoral vein (horizontal orientation).

Doppler). B-mod US depicted recidivous haematoma. With Doppler methods high flow and high systolic peak values were revealed in the popliteal, superficial and deep femoral vein, the AV communication was suspected (Figure 1)

Hypervascularized area with sonographic characteristics of vascular malformation (haemangioma) was depicted near the haematoma, ventrolaterally in the proximal third of the thigh (Figure 2). Recidivous

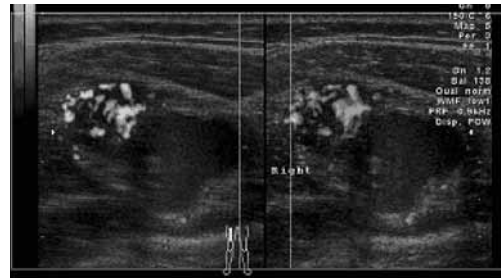

Figure 2. Hypervascularized area with sonographic characteristics of vascular malformation (hemangioma) positioned closely to the hematoma ventrolaterally in the proximal third of the thigh (horizontal orientation).

haematoma was evacuated by puncture after the US control. Clinically, the patient had bigger diameter of all parts of the right leg and oedema ventrolaterally in the right femoral region, but without a thrill and bruit over the site of the muscle injury.

The patient has been sent into the paediatric hospital to clarify the suspicion of the post-traumatic AV communication (fistula) and the right thigh vascular malformation. Control US and axial CT scan showed again recidivous haematoma and right femoral hypervascularized structure. The digital subtraction angiography (DSA) indicated by the paediatric surgeon and performed 8 months after trauma, also depicted neither AV fistula nor vascular malformation.

The repeated Doppler US, performed 10 and 11 months after trauma, showed a higher flow with high peak systolic values only in the deep femoral vein and the reduction of the right femoral hypervascularized structure size. The spiral CT scan, performed 11 months after trauma, depicted a hypervascularized lesion supplied from the deep femoral artery muscular branches positioned ventrolaterally in the right thigh proximal third. The hypervascularized lesion was equally good opacified with contrast material in the arterial and venous phase, with one avascular zone ventromedially (Figures 3, 4). The patient still had swollen right leg but there was no palpable mass in the area of vascular malformation described in the CT report with thrill and bruit over them.

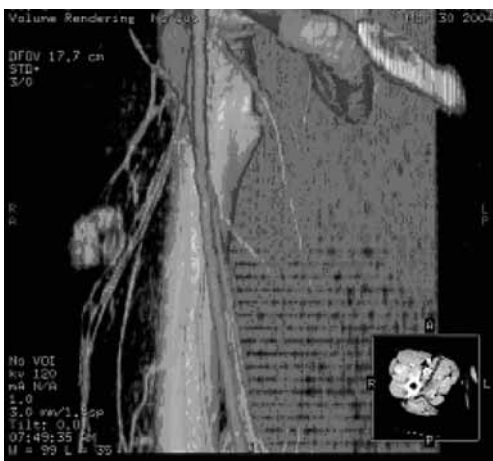

Figure 3a. Volume-rendering VR reformation – right femoral region-coronal plane (vertical orientation).

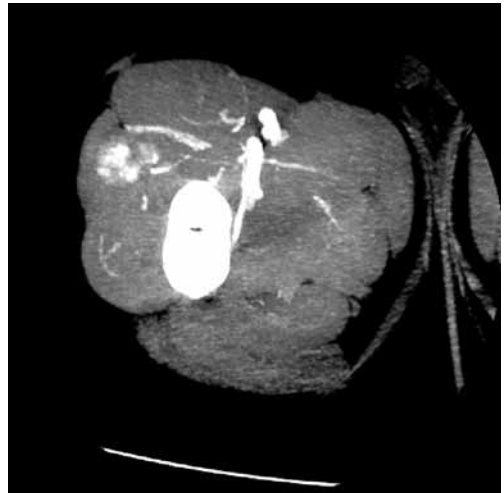


Figure 3b. Multiple intensity projection reformation MIP- right femoral region –axial plane (horizontal orientation).

Hypervascularized lesion located ventrolaterally in right thigh proximal third, equally good opacified with contrast material in the arterial and venous phase, with one avascular zone ventromedially. A lesion receives arterial supply from the deep femoral artery muscular branches.

The vascular surgeon performed the deep femoral artery muscular branches ligation, 14 months after trauma. In the surgery report only AV fistula was mentioned. After the surgery clinical manifestations and AV fistula ultrasonographic signs disappeared. This was an indirect confirmation of posttraumatic AV communication, which had not been supported with the digital subtraction angiography. The control US, performed two years after the surgical intervention showed neither haematoma nor AV communications, and the patient was clinically better without right leg oedema.

Discussion

Ultrasonography is a standard diagnostic method for the evaluation of soft-tissue structures trauma. Doppler ultrasound vas-

cular imaging is routinely included in the assessment of suspected vascular trauma. Duplex ultrasonography has sensitivity 95%, the specificity 99% and 98% accuracy in the assessment of peripheral vascular injuries, even 100% sensitivity and specificity compared with the conventional arteriography and operative exploration by Fry and colleagues 1994.⁴ Doppler vascular imaging can help to detect the origin and pattern of vascular supply and the degree of blood flow in periskeletal soft tissue masses.^{3,4} The combination of B-mod and Doppler sonography has 90% sensitivity and 91% specificity and 91% accuracy in the evaluation of musculoskeletal masses.⁹ Soft tissue vascular masses can be distinguished with these characteristics: morphostructural features, the presence of colour or power signals, the site of vascular branches, their calibre and course, the number of afferent vascular poles, resistance index, vessel density and peak flow velocities.^{10,11} Haemangioma and AV malformation have higher vessel density than other vascular malformations. There is no statistically significant difference between haemangioma and vascular malformation in vessel density and mean peak velocity. Solid-tissue mass is the factor for differentiation between haemangioma and vascular malformation.^{11,12}

AV fistula clinical manifestations in the extremities usually are swelling of the injured limb, a thrill and bruit over the site of injury, but if the thrombus has occluded the AV communication the appearance of these signs will be delayed. The severity of AV fistula clinical manifestation can vary from local changes, as it was in this case, till the venous hypertension and congestive heart failure.^{5,6}

In the case reported in this article the patient had unrecognised AV fistula. The penetrating injury of the right thigh was denied by the patient. There were no characteristic clinical signs like bruit and thrill over the

region where the AV fistula was situated, although the right leg was swollen. The aetiology of the AV fistula and hypervascularized structure near the femoral quadriceps muscle rupture remained unclear. Working hypothesis about vascular malformation injured by trauma was not confirmed with DSA and operative findings. To the authors' knowledge the differential diagnosis of posttraumatic bleeding of a congenital AV-malformation has not yet been reported.

In this case of inadequately behaving posttraumatic haematoma, the correct diagnosis of an abnormal AV communication, an AV fistula, was made on the non-invasive vascular imaging methods findings (Doppler and CT angiography) ground. DSA didn't depict a right thigh AV fistula the existence of which was indirectly confirmed with the disappearance of clinical signs after the deep femoral artery muscular branche ligation, an AV fistula feeding artery. The point is that every inadequately behaving, recidivous posttraumatic haematoma should raise the suspicion of vascular injury, and must be evaluated with the vascular imaging methods. The facts presented in this case report support opinion that non-invasive vascular imaging methods like Doppler ultrasound and CT angiography can give enough information for diagnostic and therapeutic decisions and a follow-up after the treatment.

References

1. Krolo I, Babić N, Marotti M, Klarić-Čustović R, Matejčić A, Hat J. Ultrasound in the evaluation of sports muscular injury. *Acta Clin Croat* 2000; **39**: 15-9.
2. Peetrans P. Ultrasound of muscles. *Eur Radiol* 2002; **12**: 35-43.
3. Bynoe RP, Miles WS, Bell RM, Greenwold DR, Sessions G, Haynes JL, et al. Noninvasive diagnosis of vascular trauma by duplex ultrasonography. *J Vasc Surg* 1991; **14**: 346-52.
4. Fry WR, Smith RS, Sayers DV, Henderson VJ, Morabito DJ, Tsoi EK, et al. The success of duplex ultrasonography scanning in diagnosis of extremity vascular proximity trauma. *Arch Surg* 1994; **129**: 669-70.
5. Khougeer G, Bayoumi Okda AH. Difficult femoral arteriovenous fistula in a child. *Ann Saudi Med* 2000; **20**: 150-1.
6. Tayama K, Akashi H, Hiromatsu S, Okazaki T, Yokokura Y, Aoyagi S. Acquired arteriovenous fistula of the right forearm caused by repeated blunt trauma: a report of rare case. *Ann Thorac Cardiovasc Surg* 2005; **11**: 59-62.
7. Bail HJ, Melcher I, Raschke MJ, Schroeder RJ, Schaser KD. Unknown AV-fistula as reason for post-traumatic hematoma of the thigh. *Vasa* 2003; **32**: 108-10.
8. Bohndorf K, Kilcoyne RF. Traumatic injuries: imaging of peripheral musculoskeletal injuries. *Eur Radiol* 2002; **12**: 1605-16.
9. Belli P, Costantini M, Mirk P, Maresca G, Priolo F, Marano P. Role of color Doppler sonography in the assesment of musculoskeletal soft tissue masses. *J Ultrasound Med* 2001; **20**: 587-95.
10. Taylor GA, Perlman EJ, Scherer LR, Gearhart JP, Leventhal BG, Wiley J. Vascularity of tumor sin children: evaluation with color Doppler imaging. *AJR Am J Roentgenol* 1991; **157**: 1267-71.
11. Paltiel HJ, Burrows PE, Kozakewich HPW, Zurakowski D, Mulliken JB. Soft-Tissue Vascular Anomalies: Utility of US for Diagnosis. *Radiology* 2000; **214**: 747-54.
12. Latifi HR, Siegel MJ. Color Doppler flow imaging of pediatric soft tissues masses. *J Ultrasound Med* 1994; **13**: 165-9.

Uporaba Dopplerskega ultrazvoka pri ugotavljanju in sledenju mišične rupture in arteriovenozne fistule na stegnu 12-letnega dečka

Pavčec Z, Žokalj I, Saghir H, Pal A, Roić G

Izhodišča. V članku avtorji na kliničnem primeru prikazujejo natančnost neinvazivnih slikovnih metod, zlasti Dopplerskega ultrazvoka pri ocenjevanju mišične poškodbe in obselektne žilne nepravilnosti v mehkih tkivih.

Prikaz primera. Obravnavali so 12-letnega dečka s poškodbo desne štiriglave stegenjske mišice, kjer je nastala mišična ruptura. Po operaciji so z običajnim 2-dimenzionalnim ultrazvokom videli ponavljajoči hematomi. Z ultrazvočno preiskavo so pravtako ugotovili hipervaskularizirano področje in posumili na žilno nepravilnost (angiom). Ko so prekrvavljenost bolnikovega stegna pregledali z Dopplerskim ultrazvokom, so menili, da ima lahko bolnik arteriovenozno fistulo, ki je nastala po poškodbi. Podobnega mnenja so bili preiskovalci v pediatrični bolnici, kjer so dečka ponovno pregledali z Dopplerskim ultrazvokom. Vendar digitalna subtraksijska angiografija, ki so jo naredili 8 mesecev po poškodbi, ni potrdila izvidov ultrazvočnih preiskav. Zato so 11 mesecev po poškodbi naredili računalniško tomografsko angiografijo, ki je jasno pokazala spremembe, ki so bile že večkrat opisane ob predhodnih ultrazvočnih preiskavah. 14 mesecev po poškodbi je bolnika operiral žilni kirurg in klinično stanje se je znatno popravilo. Kljub preiskavam in kirurškemu posegu vzrok nastanka fistule pri dečku ni popolnoma pojasnjen.

Zaključki. Ob neobičajnih ponavljajočih hematomih, ki nastanejo po poškodbi, je indicirana Dopplerska ultrazvočna preiskava. Z računalniško tomografsko angiografijo lahko natančneje opredelimo ultrazvočno vidne spremembe.