

Preoperative intraarterial chemotherapy with cisplatin for locally advanced high grade soft tissues sarcomas of the extremities

Jožica Červek,¹ J. Novak,¹ B. Zakotnik,¹ R. Golouh,¹ M. Šurlan²

¹Institute of Oncology, ²Institute for Rentgenology, Ljubljana, Slovenia

The aim of our study was to determine the activity and feasibility of CDP IA given preoperatively at higher dose intensity in locally advanced high grade non-metastatic soft tissue sarcomas of the extremities in adults. From 1986 to 1996 we treated 16 patients with locally advanced high grade STS of the extremities, with a diameter of 10 cm or more. Clinical remission of tumor after IA CDP was observed in 9 out of 16 patients. After IA CDP, 90 % or more necrosis of the tumor was achieved in 5 patients, between 75% and 90% in 4, and less than 75% in 7 patients. The disease-free survival at a median follow up of 52 months (range 5-122) was 62 % (95% CI 37 to 87%) and the overall survival 64 % (95% CI 37 to 91%). The functionality of the limb after treatment was excellent in 4, good in 7, fair in 4, and poor in 1 patient. We can conclude that limb sparing treatment with excellent or good limb functionality is possible in patients with locally advanced STS, without causing major local toxicity and without jeopardizing the patients' survival

Key words: soft tissue sarcomas; preoperative chemotherapy; cisplatin; extremities; treatment outcome

Introduction

Soft tissue sarcomas (STS) present about 1% of all malignant tumors, and in Slovenia about 60 new cases are diagnosed each year.¹ The treatment of choice for these types of tumors is surgery, which must be properly planned and the tumor must be removed in one block with an adequate margin of healthy tissue.² Local recurrence and lung metastases are the usual sites of relapse in these patients. The main factors that predict relapse are stage and grade of tumor and, extent of surgery performed (radical vs. non-radical). In the case of locally advanced tumors the radicality of surgery can often be ensured only by a mutilating procedure. Some trials have already tried to clarify whether it is possible to downstage these tumors by preoperative intraarterial (IA) chemotherapy, mainly adriamycin³ without jeopardizing the patient's survival. The

main drawback of adriamycin, although this being the most effective drug in soft tissue sarcomas, is its local toxicity to healthy tissues. On the other hand, experience with IA cisplatin (CDP) in osteosarcoma^{4,5} and few reports in STS⁶ show very low local toxicity and a promising activity. Low activity of CDP in the treatment of STS, when used as a systemic treatment in standard doses, renders the use of cisplatin in these tumors questionable. However, some reports indicate that this relative inactivity of cisplatin in STS could be overcome with a greater dose intensity and greater exposure of the tumor to higher concentrations of the drug, which is the case when the drug is given IA.⁷

The aim of our study was to determine the activity and feasibility of CDP IA given preoperatively at a higher dose intensity in locally advanced high-grade non-metastatic soft tissue sarcomas of the extremities in adults. The endpoints were: local recurrence rate after limb sparing surgery, tumor remission rate after CDP IA, necrosis (%) found by the pathologist, toxicity of the IA CDP, functionality of the limb after surgery, and survival.

Correspondence to: Jožica Červek, MD, Institute of Oncology, Zaloška 2, SI-1105 Ljubljana, Slovenia.

UDC: 616.747/748-006.3.04-085

Patients and methods

From April 1986 to April 1996, we treated 16 patients with locally advanced non-metastatic high grade STS of the extremities, with a diameter of 10 cm or more; there were 10 males and 6 females, 18 to 73 years old (median 48 yrs). According to their histological type, STS were distributed as follows: 9 malignant fibrous histiocytomas, 3 synovial sarcomas and 1 liposarcoma, leiomyosarcoma, rhabdomyosarcoma and neuroepithelioma. All were grade 3 tumors, except for the leiomyosarcoma, which was grade 1. The sites were as follows: 12 thighs, 3 shank and 1 in the popliteal region. Pre-operative evaluation consisted of clinical evaluation, measurement of the tumor, fine needle aspiration biopsy, chest X-ray and skeletal X-ray, CT-scan when feasible, followed by arteriography where a catheter was placed in one or two main arteries vascularizing the tumor. The chemotherapy schedule consisted of CDP 120 mg/m² IA in 6 hour intraarterial infusion given with a pump. The cycle was repeated every 14 days. Eight patients received 3, and other eight patients 2 consecutive cycles of IA CDP. The median interval between cycles was 15 days (range 13-17 days) and the median calculated dose intensity delivered was 47 mg/m²/week (range 37 to 56) of CDP IA. After IA CDP the patients were submitted to surgery. After surgery, the oriented resected specimen was analyzed by the pathologist. Tumor margins and the percentage of tumor necrosis were reported. All patients with G3 tumors received additional postoperative anthracycline-based chemotherapy. When the surgical resection was not wide or radical they were also irradiated.

The criteria for clinical response evaluation were as follows: size, consistency, mobility, definition of margins, and reduction of possible direct or indirect symptoms such as pain, edema, malfunction.³ Disease-free survival and overall survival curves with 95% confidence intervals (CI) were calculated using the Kaplan-Meier method.

Results

The median follow-up of our patients is 52 months (range 5-122). The following remission rates were achieved after IA CDP: complete remission in 2 patients, partial in 7, no change in 5 and progression in 2 patients. After IA CDP, 90% or more

tumor necrosis was observed in 5 patients, between 75% and 90% in 4, and less than 75% in 7 patients. As to the type of surgery performed, 3 patients had marginal resection, 10 wide resection, while 3/16 patients had radical resection. There were no local recurrences. The site of recurrence was always in the lung (one patient who has not been included in this study because of lung metastases at the beginning of treatment was also treated with the same regimen and achieved a complete remission of lung metastases after IA CDP; later he relapsed in the lung and died without local recurrence), which was also the cause of death in 5/16 patients that died within the follow-up period. The disease-free survival at the median follow up is 62% (95% CI 37 to 87%) (Figure 1) and the overall survival 64% (95% CI 37 to 91%) (Figure 2). The functionality of the limb after treatment was excellent in 4, good in 7, fair in 4 and poor in 1 patient.

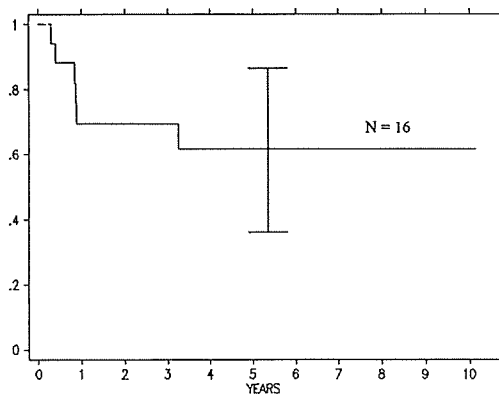


Figure 1. Disease free survival and 95% confidence intervals.

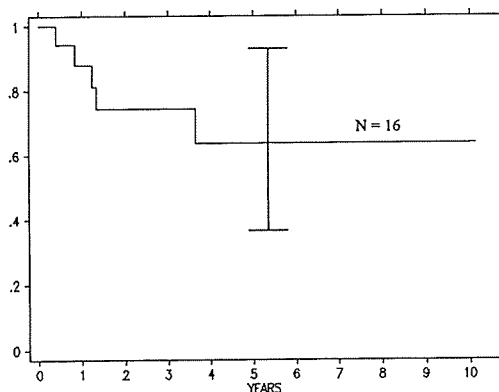


Figure 2. Overall survival and 95% confidence intervals.

Discussion

Although STS are a highly curable disease if the patient presents at an early stage, frequently - at least in our country - we see tumors in very advanced stages when the only possible local treatment is a mutilating procedure. Even after an amputation the prognosis of these patients is dismal, with survival rates at five years around 30%.^{8,9}

The question that all clinicians who have to convince patients to undergo an amputation ask themselves is whether it is possible to spare a patient's limb with the same or even better chances of survival, using a different treatment approach. In our study we selected IA CDP preoperatively instead of adriamycin which has been used by other authors with reported high local toxicity.¹⁰ Another possible solution is preoperative radiotherapy with considerable radiation sequelae,¹¹ or maybe even a combination of both.

In view of the results of our study, we are most surprised by the fact that in all 16 patients we have had not a single case of local recurrence, even though the effect of IA CDP (either clinical or % of tumor necrosis) was not always present. It is presumed that some other mechanisms may play a role in the process, e.g. the effect of IA CDP on microscopic satellite nests of tumor cells in the surrounding tissue, or an effect on neoangiogenesis (tumors on surgery appear more demarcated, and there is usually less bleeding than in patients who have not received IA CDP).

All the patients who failed to survive died due to distant metastases with the evidence of lung involvement. Obviously, CDP given IA has a systemic effect (as it was seen in the patient with lung metastases, who was not included in the study), and maybe the surprisingly high survival rate seen in our patients could be attributed to the systemic effect of IA CDP given at a higher dose intensity. Of course, due to the small number of patients included in our study, these results should be confirmed on a larger number of patients.

We can conclude that limb sparing treatment with excellent or good limb functionality is possible in selected patients with locally advanced high grade

STS without causing major local toxicity and without jeopardising the patients' survival (this may even be improved).

References

1. Pompe-Kirn V, Zakotnik B, Volk N, Benulič T, Škrk J. *Preživetje bolnikov z rakom v Sloveniji 1963-1990*. Ljubljana: Onkološki inštitut, 1995.
2. Brennan MF, Casper ES, Harrison LB. Soft tissue sarcoma. In: DeVita VT Jr, Hellman S, Rosenberg SA, editors. *Cancer principles and practice of oncology*. Philadelphia: Lippincott, 1997: 1738-88.
3. Azzarelli A, Casali P, Colella G et al. Intraarterial adriamycin and systemic ifosfamide for operable soft tissue sarcoma: pilot experience and prospective polycentric trial. *Reg Cancer Treat* 1989; **2**:184-6.
4. Červek J, Cerar O, Novak J et al. Management of osteogenic sarcoma: results and experience with 60 cases treated during the period from 1974 to 1984. In: Abstracts of lectures of 14th international cancer congress, Budapest 1986. Budapest: Akademiai Kiado, 1986:426.
5. Benjamin RS, Chawla SP, Carrasco CH et al. Preoperative chemotherapy for osteosarcoma with intravenous adriamycin and intra-arterial cis-platinum. *Ann Oncol* 1992; **3 Suppl 2**: S3-S6.
6. Samson MK, Baker LH, Benjamin RS, Lane M, Plager C. Cis-dichlorodiammineplatinum (II) in advanced soft tissue and bony sarcomas: a Southwest Oncology Group study. *Cancer Treat Rep* 1979; **63**: 2027-9.
7. Gershenson DM, Kavanagh JJ, Copeland JJ, Edwards CL, Stringer CA, Wharton JT. Cisplatin therapy for disseminated mixed mesodermal sarcoma of the uterus. *J Clin Oncol* 1987; **5**: 618-21.
8. Gerlinzoni F, Bacci G, Picci P et al. A randomized trial for the treatment of high-grade soft-tissue sarcomas of the extremities: preliminary observations. *J Clin Oncol* 1986; **4**: 552-8.
9. Bauer HCF, Möller T, Alvegard TA et al. The Sarcoma Central Registry - a joint Scandinavian Sarcoma Group project. *Acta Orthop Scand* 1996; (in press).
10. Rossi CR, Vecchiato A, Foletto M et al. Phase II study on neoadjuvant hyperthermic-antiblastic perfusion with doxorubicin in patients with intermediate or high grade limb sarcomas. *Cancer* 1994; **73**: 2140-6.
11. Rydholm A, Gustafson P, Rösser P et al. Limb-salvage surgery without radiotherapy based on anatomic location of soft tissue sarcoma. *J Clin Oncol* 1991; **9**: 1757-65.