

# Ultrasound in diagnosis and treatment of anal fistulas

Pavle Košorok

IATROS Medical Centre, Ljubljana, Slovenia

---

**Background.** Endoanal ultrasound (EUS) is helpful in the diagnosis of anorectal fistulas and abscesses due to its high resolution image quality and anatomical orientation using a radial scanning echoprobe. This type of information is essential in monitoring the response to treatment. Initial EUS examination prior to treatment, is mandatory in order to compare the results before and after treatment. Intraoperative EUS may also be helpful if the lesion is deep beyond the pelvic floor muscle which may not be seen during surgery. Better results in EUS imaging of perianorectal fistulas can be obtained using hydrogen peroxide as a contrast medium.

Concomitant advantage of hydrogen peroxide ultrasound was the detection of suspected or unsuspected sphincter defects.

However, interobserver reliability has to be taken into account together with the learning curve of a particular observer.

**Conclusions.** Endoanal US is a safe, economic, and reliable procedure for the assessment of fistula-in-ano, and is superior to physical examination.

*Key words:* rectal fistula - ultrasonography; rectal diseases - ultrasonography; abscess

---

## Introduction

The history of ultrasound in medicine started immediately after the end of World War II on the basis of experiences in marine warfare with the detection of submarines. In early 50's, a breakthrough was accomplished with the introduction of transrectal ultrasound by Wild.<sup>1</sup> But it took more than two decades for the technology to be refined and introduced into clinical practice. Thereafter, investigators

from major centres in Europe, Japan, and the United States reported that transcolorectal endosonography could provide accurate diagnosis and staging of gastrointestinal diseases.<sup>2,3</sup>

## Anal endosonography - basic principles

Ultrasound scanner is used with a rotating rectal probe providing a 360° image. All images are oriented in the way that the anterior is on the right and recorded.

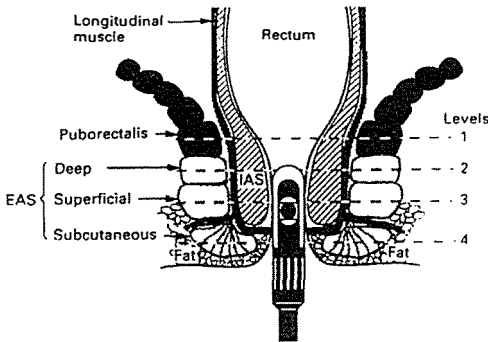
As the probe is withdrawn down the anal canal, the images of the puborectalis muscle, external anal sphincter, internal anal sphincter, longitudinal muscle, superficial transverse

Received 12 October 1999

Accepted 21 October 1999

Correspondence to: Assist. Prof. Pavle Košorok, M.D., Ph.D., IATROS Medical Centre, Parmova 51B, 1000 Ljubljana, Slovenia. Phone: +386 61 13 66 190; Fax: +386 61 13 66 194.

perineal muscle and ischiocavernosus muscles are recorded. The presence of other structures, such as the central point of the perineum and the anococcygeal ligament are also documented. Prints of the images are made at four levels (Figure 1) and the thickness of the puborectalis, longitudinal muscle, internal and external anal sphincter is measured in the midcoronal plane on both sides. The external sphincter measurements are made from the outer border of the internal sphincter to the outer edge of the external sphincter and include the longitudinal muscle, as in many females these structures could not be separated sonographically. The longitudinal muscle is also measured only when identified separately.



**Figure 1.** Schematic representation of the anal canal with a probe in situ illustrating the various levels at which measurements of muscle thicknesses are taken. Level 1, Puborectalis muscle; level 2, deep (proximal) external anal sphincter (EAS; level 3, superficial (mid) EAS; level 4, subcutaneous (distal) EAS.

The subepithelial tissues and internal sphincter are clearly defined in all patients. The longitudinal muscle is hyperechoic relative to the external sphincter in males and, so, identifiable as a separate structure. The same applied to 40% of females, but in the remainder, the longitudinal muscle and external sphincter were of similar echogenicity and, therefore, indistinguishable.

The morphology of the anal structures at the four levels is described in the study of Sultan et al.<sup>1</sup>

### (I) Puborectalis muscle

The puborectalis muscle is seen consistently as a hyperechoic diverging "U"-shaped muscle in all patients.

### (II) External anal sphincter (EAS)

The deep aspect of the EAS is in continuity with the puborectalis posteriorly in both sexes. The anterior part differed between males and females. In females, the postero-lateral muscle bundles sloped infero-medially to unite anteriorly into an intact anterior ring lower down in the anal canal. Imaging just above this level showed an apparent anterior defect in all but one female. By contrast, the EAS is symmetric at all levels in males.

In general, the deep EAS is usually annular in both sexes, otherwise it is conical, tapered posteriorly to insert into the anococcygeal ligament.

### (III) Longitudinal muscle

Where the EAS is hypoechoic, the longitudinal muscle layer is clearly distinguishable as a hyperechoic layer. This pattern of echogenicity is present in all males but only in 40% of the females. The longitudinal muscle is thicker postero-laterally and less prominent anteriorly.

### (IV) Internal anal sphincter

This layer appears homogeneously hypoechoic and is identified in all subjects.

### (V) Mucosa and subepithelial tissues

The hyperechoic submucosa (subepithelium) is seen in all subjects. The mucosa is not distinguishable as a separate sonographic structure.

### (VI) Anococcygeal ligament

This structure is inferred from the presence of a triangular hypoechoic structure, the apex of

which merges into a posterior conical deformity of the EAS. It is more prominent and also more often in males (76%) than in females (49%).

#### (VII) Perineal body

The perineal body is not a clearly defined sonographic structure. However, the central point of the perineum, where the superficial transverse perineal, deep external sphincter and bulbospongiosus (bulbocavernosus) muscles appear to meet, is seen in some subjects, particularly in males.

#### (VIII) Ischiocavernosus muscle

The ischiocavernosus muscle is not identified in females but is seen in 43% of males as a hypoechoic structure parallel to the pubic rami.

#### (IX) Muscle thicknesses

The puborectalis and deep superficial external sphincter is significantly thicker in males. A similar trend is seen in the subcutaneous external sphincter, but is not statistically significant. The males, however, are significantly heavier than the females, with a significant positive correlation between their body weight and the mean thickness of the combined components of the external sphincter, as well as the mean thickness of the puborectalis muscle.

The mean internal sphincter and longitudinal muscle thicknesses are not significantly different between males and females.<sup>1,3</sup>

A better understanding of the normal sonographic anatomy of the anal sphincter should lead to more precise diagnosis.

### Ultrasound in diagnosis and treatment of anorectal disorders

Perianorectal fistulas and abscesses are often found in patients with inflammatory bowel

disease. Rectal digital examination, rectosigmoidoscopy, CT and MRI are the standard procedures in diagnosis of fistulas and abscesses. The results, however, are often unsatisfactory. Recently, magnetic resonance imaging (MRI) has been reported to be accurate in the diagnosis of fistulas and of the sinus tract especially in patients with Crohn's disease.<sup>4,5</sup>

Different studies select the use of transcolorectal EUS as the most practical tool in clinicians' hands for the diagnosis and staging of perianorectal fistulas and abscesses.

A concomitant advantage of EUS and specially hydrogen peroxide US was the detection of suspected or unsuspected sphincter defects (recurrent fistulas; parous women), which have been shown to be present in a significant number of patients.<sup>6</sup>

#### Investigative technique

The investigative technique is similar to that in rectosigmoidoscopy, with the patient lying in a left lateral decubitus position after a phosphate enema. Rectal digital examination is necessary to palpate the probable pain area, which may be related to the site of the lesion. Careful visual inspection of the perianal skin is helpful in detecting the opening of an abscess or fistula. After this, the echoprobe, which is routinely covered with a water-filled balloon, is carefully inserted as deeply as possible. Introducing an echoendoscope, the insertion has to be endoscopically controlled to avoid any perforation. The instrument is withdrawn gradually under sonographic image control. Symmetric imaging of the left and right quadrants should be obtained to compare the anatomical structure. In this way, abnormalities can readily be found. Intravenous sedation may be indicated if the patient experiences any discomfort.

### Indications for EUS examinations

1. Suspicious finding of fistula or abscess by rectal digital examination, endoscopy, barium enema, or CT.
2. Recurrent fever and anal pain suspicious for inflammatory bowel disease.
3. Ileoanal pouch for ulcerative colitis to find out pouch related complications.
4. Follow-up after the surgery for fistulas or abscesses, or both.

### EUS criteria

A *fistula* is visualised as a hypoechoic ductlike structure adjacent to the colorectal lumen, with or without destruction of the pelvic floor musculature.

An *abscess* is visualised as an anechoic or hypoechoic cavity in the perirectal tissue, protruding into the colorectal lumen. Communication between an abscess and a fistulous tract, or between an abscess or a fistulous tract and the surrounding structures such as the skin, vagina, bladder, scrotal, or labial region, can be seen.

EUS is helpful in the diagnosis of perianorectal fistulas and abscesses due to its high-resolution image quality and easy anatomical orientation by using a radial scanning echoprobe. This type of information is essential in monitoring the response to treatment. Initial EUS examination prior to treatment, however, is mandatory in order to compare the results before and after treatment. In general, it can be stated that a reduction in the number or size of lesions found initially can be considered as partial remission. Disappearance of initial lesions is indicative of complete remission. Intraoperative EUS may also be helpful if the lesion is deep beyond the pelvic floor muscle which may not be seen during surgery. Perianorectal fistulas and abscesses, however, may often relapse. Interestingly, the comparisons between EUS and electromyogra-

phy have been carried out to evaluate external sphincter muscle defects.<sup>6</sup> The three-dimensional imaging capabilities, high soft-tissue contrast, and lack of ionizing irradiation provided by MRI have been reported as advantageous features over CT in showing the exact extension of fistulas and sinus tract in patients with Crohn's disease.<sup>4,5</sup> EUS is superior to CT and MRI for the reasons mentioned above. Studies comparing EUS, CT and MRI should be carried out to determine the accuracy and limitations of various modalities.

Gastroenterologists and surgeons are using EUS in designing treatment strategies to manage these difficult diseases. The examination is less complicated than upper gastrointestinal endosonography, and is well tolerated by patients.

The conventional surgical treatment of a fistula-in-ano is to lay open the fistulous tract and to heal by secondary intention (fistulotomy). Fecal incontinence is a feared complication, and even division of a low fistula has been associated with continence disorders in up to 34% of patients.<sup>7-9</sup>

Surgical techniques that preserve the anal sphincters, such as the mucosal advancement flap, seem promising in preserving continence and might be of use, especially in fistulas with an increased risk for continence disorders, e.g., anterior fistulas in women, high fistulas (supra, extra, and high transsphincteric), and recurrent fistulas.<sup>10</sup> Preoperative radiologic assessment of fistulous tract anatomy may be of assistance in planing surgical strategy (fistulography, CT, MRI). Transanal ultrasound (US) is an excellent modality for imaging internal and external anal sphincters,<sup>11</sup> but the results of localising fistulas varied significantly.<sup>12</sup>

### *Imaging of fistulous tract*

Different substances can be used to visualise fistulous tract (indigo blue, milk, hydrogen peroxide).

Hydrogen peroxide (HP) as a contrast medium might improve the reliability of ultrasonographic imaging of fistula-in-ano. Accuracy of hydrogen peroxide-enhanced transanal ultrasound (HPUS) in assessing a fistulous tract anatomy and the additive value obtained with this technique in comparison with physical examination and conventional US was evaluated in a special study described by Poen et al., considering the operative findings as the criterion standard.<sup>13</sup>

Twenty-one patients underwent surgery for fistula-in-ano. Patients without an external fistulous opening were excluded from the study. All fistulas, except one, were of cryptoglandular origin. Eight patients had a recurrent fistula. Evaluation consisted of physical examination, conventional US, and HPUS. With all investigations, the fistulous tract was classified according to Parks et al.<sup>14</sup> as intersphincteric, transsphincteric, extrasphincteric or suprasphincteric. Furthermore, the site of the internal opening (if present) was noted, and secondary extensions were described (intersphincteric, ischioanal supralevator, and horseshoe).

#### *Physical examination*

After the visualisation of the external opening, the palpation of the subcutaneous induration, followed by rectal examination and careful probing of the fistula, was performed. During rectal examination, the presence of the internal opening (induration) and palpation of the tip of the passing probe was noted. Proctoscopy was performed to exclude proctitis and any malignancy of the anus.

#### **Hydrogen peroxide ultrasound**

Ultrasound is using a diagnostic ultrasound system with a rotating endoprobe covered by a water-filled hard sonolucent cone producing a 360° view. The endoprobe is introduced

into the rectum, and serial radial images and video recordings of the distal part of the rectum, the puborectal muscle, and the anal canal are taken. A fistulous tract could be seen as a tube-like hypoechoic lesion. A sphincter defect is seen as a hypoechoic interruption in the sphincter complex. After conventional US is performed, HP (3%) is introduced into the fistulous tract with a flexible intravenous cannula (Venflon). Hereafter, US is repeated as described above. By infusion of HP, which generated formation of small hyperechoic air bubbles, the fistulous tract turned from hypoechoic to bright hyperechoic. The comparison of the images with and without HP identifies the course of the fistula and its extensions and allows a distinction between active fistulas and fibrotic tissue in patients who had previously been operated on. The site of the internal opening, secondary extensions of the fistula, and the presence of defects in one or both sphincters are also carefully recorded. Evidence that the internal opening is present is defined as a hypoechoic (conventional US) or a echogenic (HPUS) breach at the level of the submucosa.

#### *Surgery*

The surgeon has to be familiar with ultrasonographic findings. Under anaesthesia, careful digital examination with a probe is performed. The fistula is classified according to Parks et al.<sup>14</sup>, by assessing of the amount of sphincter tissue to be divided and the direction of the probe, relative to the longitudinal axis of the anal canal. In the case of a low fistula, the probe will meet the axis of the anal canal close to a right angle, whereas with a high fistula the angle is more oblique. The presence of an internal opening is evaluated. Based on preoperative classification and operative findings, the appropriate surgical treatment is chosen (Fistulotomy, mucosal advancement flap and excision of the sinus).

### *Primary tract*

In the Poen's study, 8 intersphincteric, 11 transsphincteric and 2 sinus tracts (without internal opening) were found on surgery. The classification was not possible in 13 of 21 patients by physical examination, because of pain or mechanical resistance during probing, whereas 8 patients (38%) were adequately classified as having a low (intersphincteric or transsphincteric) fistula. With US, fistulas appeared as hypoechoic lesions. A correct classification of the fistula in relation to the sphincters was possible in 12 patients (57%). In nine patients, classification was impossible, the main reason being the inability to distinguish active fistulas from fibrotic tissue in previously operated on patients. After the infusion of hydrogen peroxide, which was easily tolerated in all patients, active fistulas became visible by turning from hypoechoic to bright hyperechoic. Subsequently, with HPUS, the fistula was classified correctly in 20 patients, the overall concordance with surgery being 95% , representing very good agreement.

### *Internal opening*

During surgery, 19 internal openings were found in 21 patients. Most of the internal openings could also be found by physical examination, by probing, or by digital palpation (a small induration in the dentate line). Proctoscopy was not helpful in identifying the internal openings. Moreover, it was difficult to identify internal openings with US and HPUS. The number of internal openings found on physical examination did not differ significantly from the number found on surgery.

### *Secondary extensions*

With HPUS, one or more secondary extensions were found in seven patient. Although there was reasonable concordance between HPUS and surgery (71%), two secondary extensions shown with HPUS in two patients

were not found during surgery. Both patients developed a recurrent fistula.

### *Sphincter defects*

Sphincter defects were seen by US and HPUS in eight patients (in 6 patients with a recurrent fistula and in 2 patients after obstetric trauma). In four cases, the sphincter defect was not suspected during digital palpation.

### *Additive value of HPUS*

HPUS added important information in ten patients (48%). This information was helpful in facilitating correct classification of the fistula and revealing unsuspected secondary tracts or unsuspected sphincter defects. In patients with a recurrent fistula, HPUS added significant information. Based on a combination of clinical and endosonographic findings, in five of these patients, an endorectal advancement flap repair was performed instead of routine fistulotomy. In two patients, both having an extrasphincteric sinus, the excision of the sinus could be performed without damaging the sphincter complex. In the remaining three patients, the type of surgery was not altered by additional information from HPUS and a routine fistulotomy was performed.

## **Discussion**

Surgical treatment for fistula-in-ano is based on healing of the fistula and preserving continence. Therefore, it is important to know the anatomy of the primary tract, the site of the internal opening, and secondary extensions. Personal experience and skills are of great importance in the treatment of fistula-in-ano. Fistulography and CT have very limited value in the assessment of perianal fistulas.<sup>15</sup> There are several articles on the use of US in the assessment of fistulous tracts.<sup>16</sup> Deen et al.<sup>10</sup>

found US and surgery to correlate in 17 of 18 patients (94%). In contrast, Choen et al.,<sup>17</sup> demonstrated no additional value of US compared with digital examination and probing under anaesthesia. Also, US could not reveal any primary superficial tracts and high fistulous extensions (supraleatory) and could not differentiate between the scar tissue and an active fistula. In none of these studies, HP was used. Because of these disappointing results, most centers have been focusing on the use of magnetic resonance imaging (MRI).<sup>4,5</sup> This modality, with either external or enteroanal coils, has been proven to detect perianal fistulas accurately, the concordance rates with surgery of the primary tract varying from 64 to 86 percent.<sup>13</sup> Both Lunniss et al.<sup>11</sup> and Hussain et al.<sup>12</sup> found MRI significantly more accurate in the detection of fistulous tracts than US, although no HP was used. However, MRI is expensive and the special software required to obtain clear images of the anal canal is not widely available, which justifies any attempt to search for alternative diagnostic tools.

HPUS and its potential benefits were originally described by Cheong et al.<sup>13</sup> in case report. In two patients with recurrent complex perianal fistula, HPUS demonstrated accurately the fistulous tract anatomy, which was confirmed during surgery. The same group presented very recently a larger retrospective study of HPUS in 65 patients with perianal fistulas. Thirty-eight patients had surgery, the concordance of HPUS with intraoperative findings being 92 percent regarding the primary fistula tract. Besides the high accuracy in classifying primary fistulous tracks, HPUS was a sensitive method to demonstrate secondary extensions. Identification of the internal opening, however, was difficult. In Poen's study, on HPUS, the number of correctly identified internal openings rose to 48 percent, which was considered still insufficient. However, together with HPUS, proctologic examination was

always performed, the number of internal openings found was 71%, which is not significantly different from the amount found on surgery.

A concomitant advantage of HPUS was the detection of suspected or unsuspected sphincter defects (recurrent fistulas, parous women), which have been shown to be present in a significant number of patients.<sup>6</sup>

In view of these results, HPUS is supposed to be a safe, economic, and reliable technique in the assessment of fistula-in-ano. It helps the surgeon in delineating the fistula tract anatomy and provides information about the presence of anal sphincter defects. In this way, HPUS may be of value in planning the therapeutic strategy and may consequently reduce the risk of fecal incontinence and recurrence. In case of a complex or "at risk" fistula, e.g., fistulas that tend to develop post-operative fecal incontinence (recurrent fistulas, (anterior) fistulas in women, high fistulas, and all fistulas in patients with chronic diarrhoea or impaired sphincters),<sup>16</sup> a mucosal advancement flap instead of fistulotomy should be chosen. Moreover, HPUS enables the surgeon to inform patients in advance about the type of surgery that will be performed and its possible complications.

During the operation, the surgeon classifies the fistula by localising the internal opening, directing the probe during rectal examination, and by assessing the sphincter mass to be divided. Considering the approximate value of classification of fistulas during the operation, the question arises as to which of the two methods, surgery or HPUS, will become the criterion standard for classification of fistulas in the future.

## Conclusions

Endoanal US is a safe, economic, and reliable procedure for the assessment of fistula-in-ano, being superior to physical examination.

HPUS, particularly, assists in delineating the anatomic course of perianal fistulas and may, therefore, be of value in planning surgical strategy.

A concomitant advantage of HPUS is detection of suspected or unsuspected sphincter defects which have been shown to be present in a significant number of patients.

However, personal experience, together with the learning curve of particular observer, and interobserver reliability, has to be taken into account.

### References

1. Sultan AH, Kamm MA, Hudson CN, Nicholls JR, Bartram CI. Endosonography of the anal sphincters: normal anatomy and comparison with manometry. *Clin Radiol* 1994; **49**: 368-74.
2. Bartram CI. Anal endosonography. *Ann Gastroenterol Hepatol* 1992; **28**: 185-9.
3. Solomon MJ, Mcleod RS, Cohen EK, Simons ME, Wilson S. Reliability and validity studies of endoluminal ultrasonography for anorectal disorders. *Dis Colon Rectum* 1994; **37**: 546-51.
4. Koelbel G, Schmiedl U, Majer MC, Weber P, Jense H, Kueper K, et al. Diagnosis of fistulae and sinus tracts in patients with Crohn disease: value of MR imaging. *Am J R Roentgenol* 1989; **152**: 999-1003.
5. Jense H, Starlinger M, Skaleij M. Magnetic resonance imaging in perianal Crohn's disease [letter]. *Lancet* 1992; **340**: 8830.
6. Felt-Bersma RJ, van Baren R, Koorevaar M, Strijers RL, Cuesta MA. Unsuspected sphincter defects shown by anal endosonography after anorectal surgery: a prospective study. *Dis Colon Rectum* 1995; **38**: 249-53.
7. Cotte L, Pujol B, Valette PJ, Grandjean JP, Sonquet JC. Complicated perianorectal fistula: contribution of endosonography. *Gastroenterol Clin Biol* 1990; **14**: 510-1.
8. Law PJ, Talbot RW, Bartram CI, Northover J. Anal endosonography in the evaluation of perianal sepsis and fistula in ano. *Br J Surg* 1989; **76**: 752-5.
9. Eckart VF, Jung B, Fischer B, Lierse W. Anal endosonography in healthy subject and patients with idiopathic fecal incontinence. *Dis Colon Rectum* 1994; **37**: 235-42.
10. Deen KI, Williams JG, Hutchinson R, Keighley M, Kumar D. Fistulas in ano: endoanal ultrasonographic assessment assists decision making for surgery. *Gut* 1994; **35**: 391-4.
11. Lunniss PJ, Barker PG, Sultan AH, Armstrong P, Reznek RH, Bartram CI, et al. magnetic resonance imaging of fistula-in-ano. *Dis Colon Rectum* 1994; **37**: 708-18.
12. Hussain S, Stoker J, Schouten W, Hop W, Lameris J. Fistula in ano: endoanal sonography versus endoanal MR imaging in classification. *Radiology* 1996; **200**: 475-81.
13. Poen AC, Felt-Bersma RJF, Eijbsbouts QAJ, Cuesta MA, Meuwissen SGM. Hydrogen peroxide-enhanced ultrasound in the assessment of fistula-in-ano. *Dis Colon Rectum* 1998; **41**: 147-152.
14. Parks A, Gordon P, Hardcastle J. A classification of fistula-in-ano. *Br J Surg* 1976; **63**: 1-12.
15. Iroatulam AJN, Noguera JJ, Chen HH, Weiss EG, Potenti FM, Alabaz O, et al. Accuracy of endoanal ultrasonography in evaluating anal fistula. *Gastroenterology* 1997; **112(Suppl)**: A1450.
16. Tio TL, Kallimanis GE. Endoscopic Ultrasonography of Perianorectal Fistulas. *Endoscopy* 1994; **26**: 813-5.
17. Choen S, Burnett S, Bartram CI, Nicholls Rj. Comparison between anal endosonography and digital examination in the evaluation of anal fistulae. *Br J Surg* 1991; **78**: 445-7.