

How reliable is classic chest radiography in the diagnosis of small pleural effusions

Igor Kocijančič¹, Ksenija Vidmar²

¹Department of Radiology, Institute of Oncology Ljubljana, Slovenia

²Institute of Radiology, Clinical Centre, Ljubljana, Slovenia

Purpose. To evaluate the usefulness of expirium lateral decubitus views in the radiological diagnosis of small pleural effusions.

Materials and methods. Patients referred to abdominal sonography for different reasons were routinely checked for possible pleural effusion. From November 1994 till May 1996, 36 such patients were found to have pleural effusion not exceeding 15 mm and were included in the study. Patients were examined radiologically in erect PA and lateral projections and, after 5 min. in decubitus position, in inspiratory - expiratory lateral decubitus projections with 10° hip elevation and central beam on the lateral chest wall.

Results. In 22 out of 36 patients (61%), the pleural fluid was not visible on erect PA and lateral chest radiogram. However, the fluid was visible in 35/36 patients (97%) in expirium from lateral decubitus view. The average thickness of fluid from lateral decubitus views in inspirium and expirium was 4.3 and 7.9 mm, respectively. In 31 out of 36 patients (86%), the thickness of the fluid layer as measured in expirium and inspirium was different. In 16%, the fluid was not visible on inspirium lateral decubitus projections.

Conclusions. Radiography turned out to be almost as sensitive as sonography in detection of small pleural effusions. Lateral decubitus views taken in expirium contributed essentially to the diagnostic sensitivity in our study.

Key words: pleural effusion-radiology; thoracic radiography-methods; diagnosis

Introduction

A small pleural effusion may be an important finding, sometimes leading, via thoraco-

Received 19 October 1999

Accepted 18 November 1999

Correspondence to: Igor Kocijančič, MD, MSc, Department of Radiology, Institute of Oncology, Zaloška 2, SI - 1000 Ljubljana, Slovenia. Phone: + 386 61 13 21 195, Fax: + 386 61 13 14 180, E-mail: rgt@onko-i.si

centesis, to a definitive diagnosis of pleural carcinomatosis, infection or transudate. The data on the smallest detectable amount of pleural fluid vary considerably, but they are essentially within the same range whether CT, sonography or X-ray examination are used.¹⁻¹³

Rigler¹⁴ was the first to use lateral decubitus views for radiological diagnosis of small pleural effusions. Others^{1,3,15}, who further

developed the technique, detected, working on cadavers,¹ as small amounts as 5 ml of pleural fluid.

No valid comparison has been made between the thickness of the pleural effusion, as seen on X-ray or sonography, and the amount of aspirated fluid. A small amount of fluid (5-10 ml) is often present in the pleural space of a healthy person.² There is probably some residual fluid after thoracentesis. These two circumstances would, in our view, severely limit the reliability of „exact“ quantitative studies of small pleural effusions. We have therefore tried to assess the clinical usefulness of the method.

The aim of our study was to assess:

- whether lateral decubitus views are really more effective in detecting small pleural effusions than erect PA and lateral projections only;
- and, more important, whether the use of inspiratory-expiratory views can further improve the results.

Patients and methods

Patients, referred to abdominal sonography for different reasons, were routinely checked for possible unsuspected pleural effusion.

From November 1994 till May 1996 thirty-six such patients, in whom the thickness of the pleural effusion in sonography did not exceed 15 mm, were included into the study. Of these 36 patients, 27 were males and 9 females, their age ranging between 28 - 80 years, with a mean age of 54.8 years.

Their condition was clinically diagnosed as:

Lung cancer	14
Metastasis to the lung	6
Pulmonary TB	5
Cardiac failure	4
Systemic connective tissue disease	4
Liver cirrhosis	2
Chest trauma	1

Abdominal sonography was performed first. The patient was then put for 5 minutes into lateral decubitus position. Then the sonography of the lower pleural space, followed, first, with the patient leaning on his/her elbow, and second, in a sitting position. It was performed by a Toshiba SAL 38-B ultrasound unit with a 5 MHz large radius convex transducer. The findings were recorded on Polaroid films.

Radiological examination was performed only if sonography had shown any small pleural effusion. Erect PA and lateral projections were obtained for other indications. Written consent was obtained from the patients for additional, simultaneous lateral decubitus views.

A 140 kV Siemens unit was used, with 2 m F-F distance for the erect views of the chest, and 1.5 m F-F distance for lateral decubitus views. For these, the patient was put into lateral decubitus position for 5 minutes, with 10 deg. hip elevation. Exposures were taken in both, inspirium and expirium, with the central beam aimed at the lateral chest wall and the patient slightly rotated onto his/her back. An experienced radiologist was always present at the examination. The films were evaluated independently by two experienced radiologists with no previous knowledge of findings.

The criteria for determining the presence of pleural fluid were:

Sonography^{8,16-18}

- a non-echogenic zone between the parietal and the visceral pleura, changing between expirium and inspirium as well as changing with different positions of the patient,
 - fluttering of the pulmonary edge during respiration,
 - moving hyperechogenic particles within the fluid.
- X ray^{3,19}
- from a lateral decubitus view, the minimum thickness of the horizontal fluid layer should be 3 mm,

- costophrenic angle density with meniscus sign on erect views.

Matching pairs T-test was used for the analysis of differences in measurements on the same individual.

Results

In 22 out of 36 patients (61%) the pleural fluid was not visible on erect PA and lateral chest radiogram.

The average thickness of the visible fluid on lateral decubitus views was 4.3 mm in inspirium and 7.9 mm in expirium, the difference of 3.6 mm being statistically significant ($p < 0,005$).

In 6 out of 36 patients (16%), the fluid was not visible from lateral decubitus views in inspirium. In 5 of these, the fluid level was visible in expirium, its thickness being 4 - 8 mm (Table 1). In one patient, the fluid was only visible on sonography, proved by thoracocentesis.

In 31 out of 36 patients (86%), there was a difference in the thickness of the fluid layer as measured in expirium and inspirium from lateral decubitus views.

In 5 patients (14%), the layer was unchanged in inspirium and expirium.

Discussion and conclusions

Rigler¹⁴ was the first to use lateral decubitus views for the demonstration of pleural fluid. He did not use exposure in expirium, nor did he aim the central beam at the lateral chest wall, parallel to the expected fluid level. The latter technical improvement was introduced by Hessen³ together with the elevation of the patient's hip, while the exposure in expirium is mentioned in the work of Müller and Löfstedt¹⁵ but apparently without gaining wider acceptance.

Table 1. Thickness of pleural fluid layer on lateral decubitus views

Thickness of fluid	Number of patients in	
	inspirium	expirium
0 mm	6 (16%)	1 (3%)
3-5 mm	17 (48%)	8 (22%)
6-10 mm	12 (33%)	18 (50%)
11-15 mm	1 (3%)	9 (25%)

The amounts of pleural fluid detectable this way were assessed in cadaver experiments¹ and were as little as 5 ml in experimental conditions. This is probably less reliable in practice due to the unaccurate results of thoracocentesis.

With the advent of sonography it was shown that very small amounts of pleural fluid can be demonstrated this way.⁴⁻⁸

In the literature, we couldn't find any exact quantitative definition of small pleural effusions. So, our term of small pleural effusions includes clinically silent effusions which are usually unexpected findings on X-ray and/or sonography examinations for different reasons.

In the course of our study we have achieved comparable results using sonography and radiography. Interestingly, the main sign, allowing the demonstration of the smallest effusions, was similar in both modalities: the changing of the fluid layer during inspirium - expirium.

Obviously, a thicker fluid level, as is more often seen in expiratory views, would tend to facilitate the diagnosis (Figure 1, 2). Another advantage of using this criterion was our increased ability to recognise artefacts such as skin folds, sheets, subcutaneous fat and the like.

Since both sonography and „classical“ radiography seem to be sensitive methods for demonstrating small pleural effusions, there should not be any overwhelming reason to use CT as the first choice for this purpose, especially since the results of CT do not seem superior in this respect.^{9,13,20}

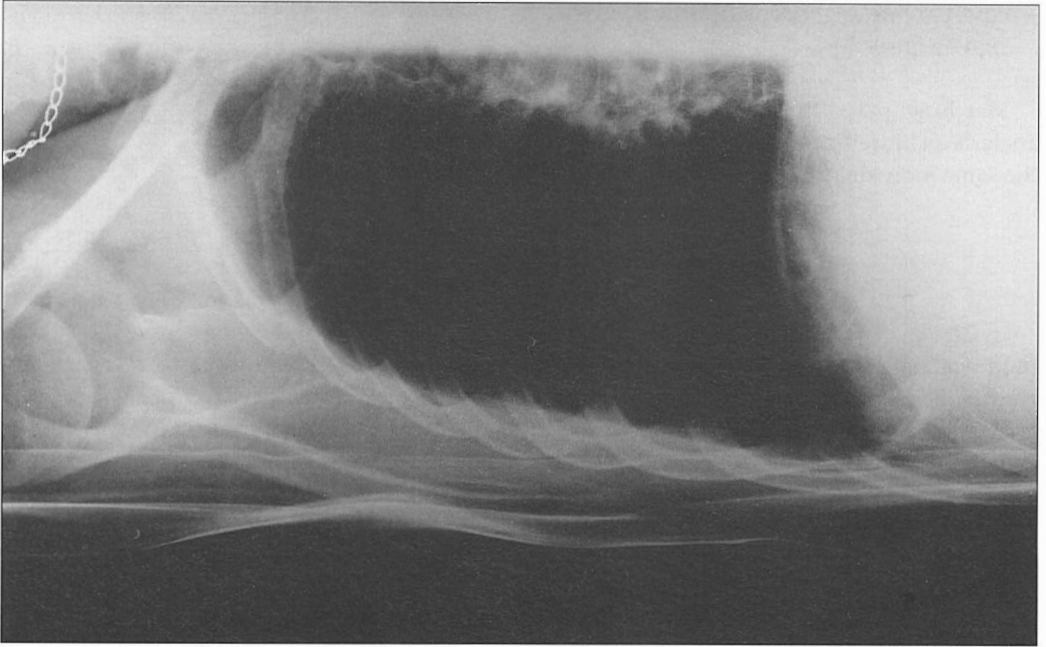


Figure 1. Inspiratory lateral decubitus projection showing about 5 mm wide layer of pleural fluid in 30 years old male patient with TBC pleuritis.

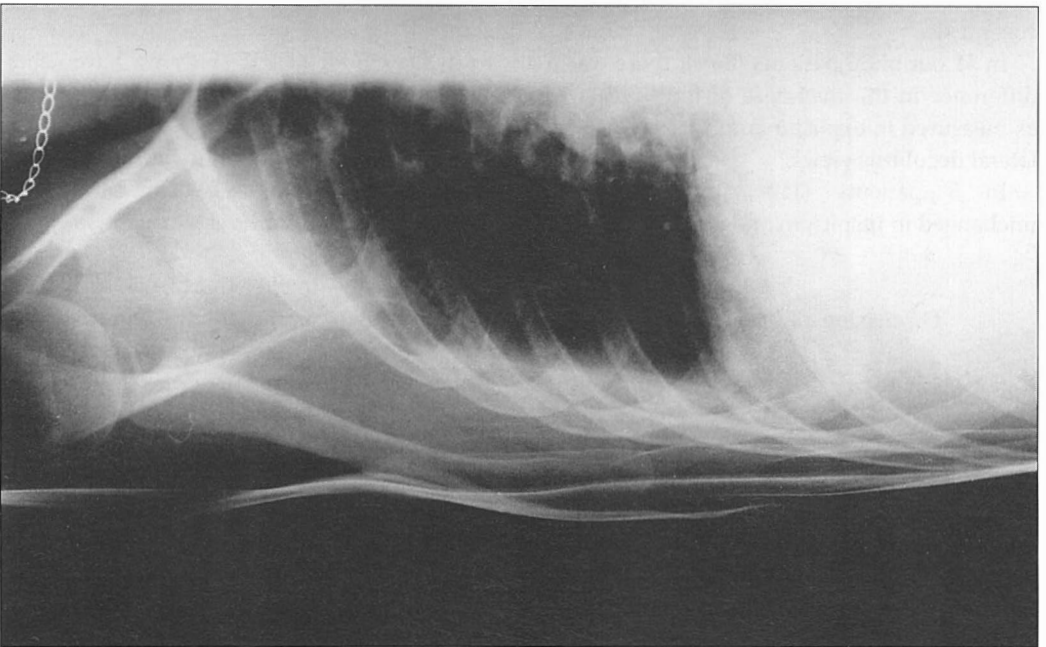


Figure 2. Expiratory lateral decubitus projection in the same patient showing much thicker fluid level (about one cm), which tends to facilitate the diagnosis.

For satisfactory results, meticulous adherence to the technique described may be an advantage. Lateral decubitus views taken in expirium contributed essentially to the diagnostic sensitivity of radiological examination in our study.

Reference

1. Moskowitz H, Platt RT, Schachar R, Mellus H. Roentgen visualization of minute pleural effusion. *Radiology* 1973; **109**: 33-5.
2. Felson B. *Chest rentgenology*. Philadelphia: W.B. Saunders; 1973. p. 352.
3. Hessen I. Roentgen examination of pleural fluid. A study of the localisation of free effusions, the potentialities of diagnosing minimal quantities of fluid and its existence under physiological conditions. *Acta Radiol* 1951; **86 Suppl 1**: 1-80.
4. Gryminski J, Krakowa P, Lypacewicz G. The diagnosis of pleural effusion by ultrasonic and radiologic techniques. *Chest* 1976; **70**: 33-7.
5. Lipscomb DJ, Flower CDR. Ultrasound in the diagnosis and management of pleural disease. *Br J Dis Chest* 1980; **74**: 353-61.
6. Von Eibenberger K, Dock W, Metz V, Weinstabl C, Haslinger B, Grabenwöger F. Wertigkeit der thorax bettaufnahmen zur diagnostik und quantifizierung von pleuraergüssen - überprüfung mittels sonographie. *RöFo* 1991; **155**: 323-6.
7. Lorenz J, Börner N, Nikolaus HP. Sonographische volumetrie von pleuraergüssen. *Ultraschall* 1988; **9**: 212-5.
8. Mathis G. *Lungen und pleurasonographie*. Berlin: Springer - Verlag; 1992. p. 11.
9. Mc Loud TC, Flower CDR. Imaging of the pleura: Sonography, CT and MR imaging. *AJR* 1991; **156**: 1145-53.
10. Mikloweit P, Zachgo W, Lörcher U, Meier-Sydow J. Pleuranage lungenprozesse: diagnostische wertigkeit sonographie versus CT. *Bildgebung* 1991; **58**: 127-31.
11. Leung AN, Muller NL, Miller RR. CT in the differential diagnosis of pleural disease. *AJR* 1990; **154**: 487-92.
12. Maffesanti M, Tommasi M, Pellegrini P. Computed tomography of free pleural effusions. *Eur J Radiol* 1987; **7**: 87-90.
13. Flower CDR. CT and ultrasound in the management of pleural disease. In: The Fleischner Society, editor. 21st annual symposium on chest disease, 1991 May 23-25; Interlaken, Switzerland, 1991. p. 445-8.
14. Rigler LG. Roentgen diagnosis of small pleural effusions. *JAMA* 1931; **96**: 104-8.
15. Müller R, Löfstedt S. Reaction of pleura in primary tuberculosis of the lungs. *Acta Med Scand* 1945; **122**: 105-33.
16. Targhetta R, Bourgeois JM, Marty-Double C, et al. Vers une autre approche du diagnostic des masses pulmonaires périphériques. *J Radiol* 1992; **73**: 159-64.
17. Marks WM, Filly RA, Callen PW. Real-time evaluation of pleural lesions: New observations regarding the probability of obtaining free fluid. *Radiology* 1982; **142**: 163-4.
18. Brant WE. US of the thorax. In: Rumack CM, Wilson SR, Charboneau JW, editors. *Diagnostic ultrasound*. St. Louis: Mosby-Year Book; 1991. p. 413-28.
19. Raasch BN, Carsky EW, Lane EJ, O'Callaghan JP, Heitzman ER. Pleural effusion: Explanation of some typical appearances. *AJR* 1982; **139**: 889-904.
20. Stark P. The pleura. In: Taveras JM, Ferrucci JT, editors. *Radiology, diagnosis, imaging, intervention*. Philadelphia: J.B. Lippincott comp.; 1995. Chapter 80. p. 3.