

Minimally invasive therapy in carcinomas of the head and neck - an updated overview

H. Iro,¹ F. Waldfahrer,¹ M. Weidenbecher,² R. Fietkau,³ M. Gramatzki⁴

¹ Department of Otorhinolaryngology, Head and Neck Surgery, Saarland University, ² Department of Otorhinolaryngology, Head and Neck Surgery, University Erlangen-Nürnberg, ³ Department of Radiation Oncology, University Hospital Erlangen, ⁴ Division of Oncology and Hematology, Department of Internal Medicine III, University Hospital Erlangen, Germany

In this up-to-date review the current role of minimally invasive procedures in head and neck oncology is defined. Endoscopic laser surgery in comparison with commando procedures is discussed as well as other non-operative treatment modalities, such as simultaneous chemo-radiotherapy. Special reference is given to the question if functional or radical neck dissection are of the same oncological value.

Key words: head and neck neoplasms-therapy

Treatment of carcinomas of the oral cavity and the oropharynx

In the surgical treatment of tumors of the oral cavity and oropharynx, the removal of carcinomas by radical surgery - implying a monobloc resection of primary tumor in continuity with radical neck dissection and splitting or resection of the mandible - has been in the foreground of discussion since the end of the last century. These radical surgical strategies, advocated mainly by Martin and Sugarbaker¹ and Conley and von Fraenkel² require extensive use of flaps to reconstruct the defects and are frequently associated with mutilation of the patient, prominent dysphagia and impaired speech. A theoretical basis for these extensive operations is provided by the investigations of Ward and Robben³ and Larsson *et al.*⁴, who demonstrated a lateral drainage from the floor of the mouth towards the periosteal lymph vessels of the mandible and from there into the deep cervical lymph nodes. There is concern that malignant cells will remain in the region of the

lymphatic drainage system and, above all, in the lymph vessels of the periosteum of the mandible if the primary tumor and the neck receive discontinuous treatment and if mandibular resection is neglected.

In 1971, Marchetta⁵ used histological analysis to show that even with extensive carcinomas in the oral cavity associated with regional lymph node metastases involvement of the periosteum occurred only via a direct infiltration. Whenever macroscopically visible healthy tissue was found between the tumor and the mandible, no metastatic involvement of the periosteum was detectable in the course of these investigations. Weidenbecher and Pesch⁶ were unable to identify either tumor cells in lymphatic vessels of the periosteum or tumor extension into the Haversian channels, or intraosseous formation of metastases. In a recent study, no difference in disease free survival of patients with oral cancer between "radical" and "functional" regimens could be found.⁷

On the basis of the various studies, one can conclude that, even if infiltration of the mandibular periosteum has occurred, a partial resection which does not disrupt the continuity of the mandible could be sufficient for the cure of the tumor. In terms of disappointing treatment results, the demand for gen-

Correspondence to: Prof. Dr. H. Iro, Head, Department of Otorhinolaryngology, Head and Neck Surgery, Saarland University, D-66421 Homburg (Saar), Germany.

UDC: 617.52/.53-006.6-08

eral monobloc resections of the primary tumor in continuity with the region of the lymphatic drainage system appears out of date. Within the last two decades, various research groups have published reports on transoral resections which were performed in cases of advanced malignancies in regions of the oral cavity and oropharynx.^{8,9} The treatment results reported are comparable to those achieved by en bloc resection and reconstruction of defects by pedicled or microvascular anastomosed flaps. Panje *et al.*¹⁰ as well as Steiner¹¹, in particular, have emphasized the substantially lower degree of impairment of important functions and disfiguring of the patient caused by transoral resections, thus rendering measures to reconstruct defects unnecessary. By spontaneous epithelization of the operated sites, good preservation of the function and little cosmetic impairment can be obtained. Nonetheless, the principles of curative therapy of the tumor in both, enoral and transoral, minimally invasive and function-conserving operative techniques must be strictly observed.

Treatment of laryngeal carcinomas

After the introduction of microlaryngoscopy, the transoral endolaryngeal resections of carcinomas of the vocal cord were soon widely accepted. In 1972, Strong and Jako¹² introduced the carbon dioxide laser - coupled to the microscope - into clinical practice. In the years to follow, various research groups reported on a successful therapy of small vocal cord cancer.⁸ The laser, however, also allows the transoral endolaryngeal resection of larger glottic tumors as well as supraglottic carcinoma. Notably, Steiner *et al.*¹³ pointed out that the application of CO₂ lasers has substantially expanded the range of indications for minimally invasive, organ-sparing and function-maintaining endolaryngeal surgery also on advanced laryngeal carcinomas.

Endolaryngeal laser surgery seems to be especially suitable for the treatment of superficially spreading T2 carcinomas which are not easily accessible to conventional external partial resections. The treatment results after endolaryngeal laser resections of T2 laryngeal carcinomas - which had been partly achieved by additional postoperative radiation therapy - are comparable to the results of conventional surgical methods (Figure 1). Endolaryngeal surgery also allows the larynx to be pre-

served with a lower degree of functional impairment and tracheotomy to be avoided.

Deep infiltration of the anterior commissure is considered to be a contraindication to endolaryngeal surgery. While Steiner *et al.*¹³ also treat T3 laryngeal cancer by means of endolaryngeal laser surgery, Eckel and Thumfart¹⁴ among others reject an endolaryngeal therapeutic approach for these advanced types of laryngeal carcinomas.

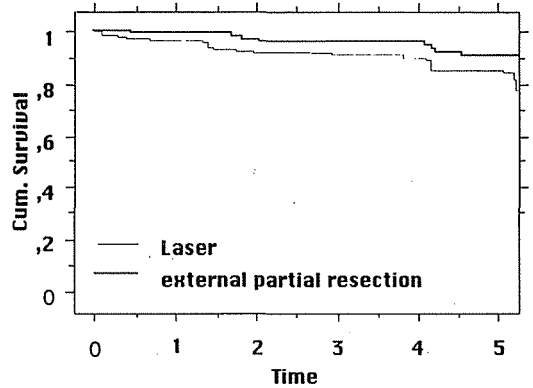


Figure 1. Comparison in survival (years) of endolaryngeal laser surgery and conventional external partial resection of T2 glottic carcinoma (N=128, Department of Otorhinlarygology, Head & Neck Surgery, Erlangen, Germany).

Treatment of the neck in cancer of the upper respiratory tract

Whereas in 1906, Crile¹⁵ described radical neck dissection as the treatment of choice for lymph node metastases in the neck, only 16 years later Truffert¹⁶ laid the anatomical-pathological foundations for functional lymph node surgery of the neck. In 1963, Suarez¹⁷ and in 1967 Bocca and Pignatoro¹⁸ developed the fundamental concepts of "conservative" neck dissection with the preservation of sternocleidomastoid muscle, accessory nerve and internal jugular vein. Conservative or "functional" neck dissection proved itself to reduce distinctly the morbidity rate while maintaining a comparable degree of treatment effectiveness. In Figure 2, a comparison of disease free survival rates is drawn between functional and radical neck dissections in an unselected group of patients with head and neck squamous cell carcinoma (unreleased data, Department of Otorhinlaryngology, Head and Neck Surgery, University Erlangen, 1970-1990). The distribution of stages was approximately equal in both groups.

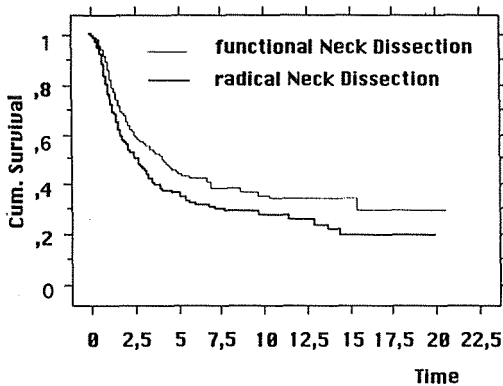


Figure 2. Comparison of disease free survival (years) in cancer of the oral cavity, pharynx and larynx in accordance to neck dissection mode (N = 840, Department of Otorhinlaryngology, Head & Neck Surgery, Erlangen, Germany).

Non-surgical therapy of head and neck cancer

Nowadays, simultaneous chemo-radiotherapy must be - in accordance to several publications (overview at ¹⁹ considered as the treatment of choice in primary unresectable cancer of the upper respiratory tract with “unresectable” also meaning “unresectable” from a functional point of view). CDDP and 5-fluorouracil are the most often used chemotherapeutic agents for this purpose. In addition, hyperfractionated radiotherapy seems to be superior to conventional radiation. Simultaneous chemoradiotherapy has become feasible by application of supportive measures such as nutrition via percutaneous endoscopically guided gastrostomy, hemopoietic growth factors and adequate pain management.

Acknowledgment

This work was supported by the Johannes und Frieda Marohn Stiftung, Erlangen, Germany.

References

1. Martin H, Sugerbaker EL. Cancer of the tonsil. *Am J Surg* 1941; **52**: 158-96.

2. Conley JJ, von Fraenkel T. Historical aspect of head and neck surgery. *Ann Otol* 1956; **65**: 643-55.
3. Ward GE, Robben JO. A composite operation for radical neck dissection and removal of cancer of the mouth. *Cancer* 1951; **4**: 98-109.
4. Larsson DL, Lewis SR, Rapperport AS, Coers CR, Blocker TG. Lymphatics of the mouth and neck. *J Surg* 1965; **110**: 625-30.
5. Marchetta RC. The periosteum of the mandible and intraoral carcinoma. *Am J Surg* 1971; **122**: 711-3.
6. Weidenbecher M, Pesch HJ. Zur Frage der generellen Unterkieferresection bei knochenah gelegenen Karzinomen der Mundh'hle und des Oropharynx. *HNO* 1982; **30**: 453-6.
7. Iro H, Waldfahrer F, Gewalt K, Zenk J, Altendorf-Hofmann A. Enoral/transoral surgery of malignancies of the oral cavity and the oropharynx. *Adv Otorhinolaryngol* 1995; **49**: 191-5.
8. Iro H, Hosemann W. Minimally invasive surgery in otorhinolaryngology. *Eur Arch Otorhinolaryngol* 1993; **250**: 1-10.
9. Iro H, Waldfahrer F. Postoperative Staging und Chirurgische Therapie von Kopf-Hals-Tumoren. *Onkologe* 1996; **2**: 339-45.
10. Panje WR, Scher N, Karnell M. Transoral carbon dioxide laser ablation for cancer, tumors, and other diseases. *Arch Otolaryngol Head Neck Surg* 1989; **115**: 681-8.
11. Steiner W. Laserchirurgie im HNO-Bereich. *Arch Otorhinolaryngol* 1987; **244 Suppl II**: 8-18.
12. Strong MS, Jako GJ. Laser-surgery in the larynx: early clinical experiences with continuous CO₂ laser. *Ann Otol Rhinol Laryngol* 1972; **81**: 791-8.
13. Steiner W, Iro H, Petsch S, Sauer S, Sauerbrei W. Laserchirurgische Behandlung von Larynxkarzinomen (pT2-4). In: D'Yhmke E, Steiner W, Reck R, eds. *Funktionserhaltende Therapie des fortgeschrittenen Larynxkarzinoms*. Stuttgart: Thieme, 80-91.
14. Eckel HE, Thumfart WF. Vorläufige Ergebnisse der endolaryngealen Laserresection von Kehlkopfkarzinomen. *HNO* 1990; **38**: 179-93.
15. Crile G. Excision of the cancer of the head and neck with special reference to the plan of dissection based on 132 operations. *JAMA* 1996; **47**: 1780-6.
16. Truffert P. *Le cou: les aponeuroses - les loges*. Paris: Librairie L. Arnette, 1922.
17. Suarez O. El problema de las metastasis linfaticas alejadas del cancer de laringe e hipofaringe. *Rev Otorinolaryngol* 1963; **23**: 83-99.
18. Bocca E, Pignataro O. A conservation technique in radical neck dissection. *Ann Otol* 1967; **76**: 975-87.
19. Fietkau R, Steiner W. Moderne Aspekte der Strahlen- und Chemotherapie im Hals-Nasen-Ohren-Bereich. *Eur Arch Otorhinolaryngol* 1997; Suppl (in print)