

## Endosonographic appearance of the anal sphincters in patients following colostomy

Iwona Sudół-Szopińska<sup>1</sup>, Marek Szczepkowski<sup>2</sup>, Anna Panorska<sup>3</sup>,  
Wiesław Jakubowski<sup>1</sup>

<sup>1</sup>Department of Diagnostic Imaging, Second Faculty of Medicine, Warsaw, Poland

<sup>2</sup>Second Surgical Department, Bielany Hospital, Warsaw, Poland

<sup>3</sup>Desert Research Institute-DHS, Reno, NV, USA

---

**Background.** The aim of the study was to visualize, by anal ultrasound (AUS), the suspected defects of the anal sphincters in the patients after colostomy and to analyze possible factors that could have led to such defects.

**Patients and methods.** AUS, using a 7.0 MHz endorectal probe, was performed in a group of 25 patients with colostomy. The internal anal sphincter (IAS), external anal sphincter (EAS) and puborectalis muscle (PR) were visualized and the defects within them were qualified and quantified. For statistical analysis, the analysis of variance (ANOVA) was used.

**Results.** The IAS was thin in all but three patients (22 patients; 88 %) with the mean thickness of 1.62 mm. A circular reduction of the thickness along the entire length of the IAS was seen in 20 patients (90.9 %). The echogenicity of the IAS was increased in 15 patients (60 %), and in 10 of them (66.6 %), this defect embraced the whole length and circumference of the IAS. The margins of the IAS were not well-defined in 10 patients (40 %). A significant correlation was found between the length of the patient's life with the stoma and the IAS echogenicity defect ( $p$ -value = 0.0001). No significant correlation was found between the dynamic examination, the IAS thickness and the IAS borders definition.

**Conclusion.** The reduced thickness, increased echogenicity and borders definition defect of the IAS are seen in the patients after colostomy. The only significant correlation was confirmed between the length of the patient's life with the stoma and the IAS echogenicity defect.

*Key words:* colostomy; anus – ultrasonography

---

Received 11 November 2001

Accepted 26 November 2001

Correspondence to: Iwona Sudół-Szopińska, MD, PhD, Zakład Diagnostyki Ultrasonograficznej, Wojewódzki Szpital Bródnowski, ul. Kondratowicza 8, 03-285 Warszawa; Phone/Fax +48 22 811 95 91; Mobile 0 501 716 407; E-mail: mdyvonne@wp.pl

## Introduction

Anal ultrasonography (AUS) is well established as a method of the visualization of normal and damaged sphincters. The defects of the internal anal sphincter (IAS) and external anal sphincter (EAS) are well represented. The structural abnormalities of either muscle as well as more subtle abnormalities of the internal sphincter smooth-muscle texture and composition can be identified.<sup>1</sup> AUS has now replaced electromyographic mapping in the demonstration of the defects of the sphincters.<sup>2</sup> This examination is safe, easy to perform and causes little patient discomfort.

Endosonographic assessment of the anal sphincters is very important before deciding whether or not to perform decolostomy or close a loop colostomy.

In order to recognize the suspected defects of the anal sphincters in patients after colostomy, we evaluated a group of patients with colostomy, assessed the IAS, EAS and puborectal muscle (PR), and analyzed possible factors that could have led to such defects.

## Patients and methods

### Patients

Twenty-five consecutive patients with colostomy were investigated by AUS between March 3, 2000 and June 30, 2000. The group comprised 17 women and 8 men with a median age of 71 (47 to 82 years old). No perianal operation was performed before and after colostomy. Two women had forceps deliveries (one gave birth to four children, with the largest baby weighing 3000 g and the second delivered twice with the babies weighing 3500 g each), two others had the second-degree tear of the peritoneum and four gave birth to babies with the birth weight exceeding 4000 g. Additional six with no complications at the delivery gave birth to one or two children with the birth weights below

4000 g and the last three women had not given birth.

The patients were inquired about defecation problems before operation: constipation and anal incontinence for gas and feces. Six patients (all women) complained about constipation present longer than ten years. All but one patient incontinent for gas were subjectively satisfied with the level of continence.

In our analyzed group of patients with colostomies, there were six patients with loop-colostomies; the remaining nineteen had end-colostomies in the course of Hartmann's operation. The most frequent indication for performing colostomy was adenocarcinoma of the sigma (fifteen patients). Others were as follows: rectal carcinoma (one patient), adenocarcinoma of the colon descendens (one), adenocarcinoma of the rectosigmoid (one), diverticulitis (two), complicated diverticulitis (one), colon ischemia (one), dehiscence anastomosis (two), tumor inflammatorious sigmoidae and urinary bladder (one).

The length of life with stoma ranged from eight weeks to sixteen years (median 38.17 months).

### Methods

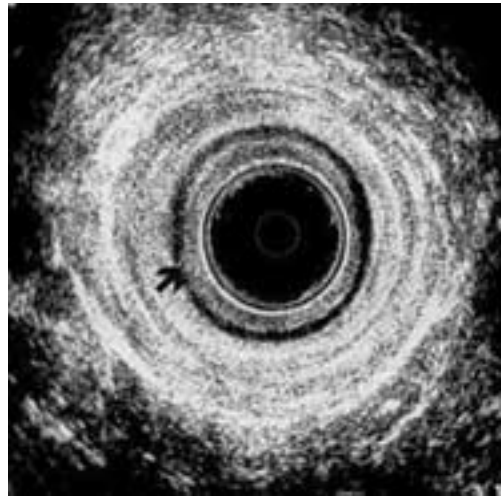
AUS was performed with the ultrasound scanner Bruel & Kjaer type 1846, Naerum, Denmark using a rotating 7.0 MHz transducer (type 1850). The transducer was covered by a plastic cone with an external diameter of seventeen mm and filled with degassed water. All the examinations were performed and read by one independent radiologist who was blind to the length of the patients life with the stoma and to clinical information. No bowel preparation was indicated. The examinations were performed in the left lateral position. Serial images were assessed along the length of the anal canal.

### Image analysis

The thickness of the IAS was measured from the screen of the machine using electronic calipers in the distal and proximal part of the anal canal in each quadrant of the IAS. The echogenicity and margins of the IAS were assessed as increased or normal and not well-defined or well-defined, respectively. The EAS and the PR echogenicity were assessed as normal or not-homogenous/decreased. The dynamic activity of the EAS and PR was observed during rest and maximal contraction of these muscles and diagnosed subjectively by examining physician as: normal, poor or lack of contraction.

### Results

In all but 3 patients (88%), the IAS was thin with the mean thickness of 1.62 mm. Twenty patients had a circular reduction of the thickness (90.90%) and remaining 2 (9.09%) partial, i.e. restricted to one or two walls of the anal canal. In 12 patients, the entire length of the IAS was equally thin over the complete circumference, in 5, a circular reduction was seen only in the proximal part, and in 3 patients, only in the distal part of the anal canal (Figure 1). In one patient, the thinning of the IAS was not circular, but occurred on the posterior wall in a deep part, and in one patient, only on the posterior wall in a proximal part and on the lateral walls in the distal part of the anal canal. Three patients (12%) had normal thickness of the IAS – at least 3.0 mm. Their length of life with stoma was 1.5, 14 and 18 months (mean 11.17 months). For the remaining patients with thin IAS, the thickness of the IAS was the smallest (less than 1 mm in nine cases) in patients with the colostomy from 8 weeks to 10 years (mean 24.94 months); the thickness of at least one but below 2 mm was seen in 7 patients living with the stoma from 3 months to 16 years (mean 43.57 months). The thickest IAS (at least 2



**Figure 1.** Endosonographic transverse image of the anal sphincters thinning in patient following colostomy: the thickness of the IAS in the distal part of the anal canal is less than 1 mm (arrow). Note that the echogenicity is normal (hypoechoic) and borders of the sphincter are well defined.

but less than 3 mm, six cases) was observed in the patients who had the stoma from 5 months to 10 years (mean 42.67 months).

Echogenicity of the IAS was increased in 15 patients (60%) who lived with the stoma between 1.2 and 16 years (mean 7.71 years). Six of them (40%) had colostomy for less than one year and remaining 9 (60%) for a longer time. Ten patients out of 15 (66.6%) had a circular increase of echogenicity seen within the entire length of the IAS (71.42%) and their length of life with the stoma was from 6 months to 10 years, (mean 34.35 months). In 4 cases, it was seen only in the proximal part and the length of life with the stoma ranged from 1.5 months to 10 years (mean 56 months). One patient with the increased echogenicity had colostomy for 16 years in the distal part of the IAS.

The borders of the IAS were not well defined in 10 patients (40%), including 7 who had the stoma from 1.5 to 11 months (mean 5.28 months) and 3 with the length of life with the

stoma of 4, 5 and 10 years (mean 6.33 years; i.e. 75.96 months). In 6 of these 10 patients, the margins of the IAS were not well defined only within a proximal part of the anal canal. All but one had stoma for less than one year. In 4 cases, the increased echogenicity was observed on the whole sphincter. These patients mostly had colostomy for a longer time.

The dynamic assessment of the EAS and PR in AUS was good in 18 patients (72%), poor in 3 (12%) and no contraction was seen in 4 patients (16%). The length of life with the stoma in the patients with good contraction ranged from 1.5 months to 16 years (mean 40.72 months), in the patients with poor contraction from 5 to 18 months (mean 8.17 months), and in the patients without contraction of the muscles from 3 months to 3.5 years (mean 15.38 months).

Scars inside the EAS were seen in 4 patients and in one patient in both, the EAS and the PR.

We have performed standard statistical analysis to assess if any significant correlation exists between the length of the patient's life with the stoma and the IAS thickness, echogenicity, border and the results of the dynamic exam.

Detailed results are given below. All significance tests were performed on 0.05 significance level and the results were reported accordingly, unless otherwise noted.<sup>3</sup>

### Statistical analysis of results

The length of the patient's life with the stoma versus IAS thickness

We have started by computing the Pearson correlation coefficient between the length of the patient's life with the stoma and the IAS thickness. It amounted to 0.025, which is not statistically significant, considering the 0.05 levels. The next step was to divide the observations into the following 4 categories with respect to IAS thickness: IAS thickness less than 1 mm, IAS thickness at least 1 but less than 2 mm (between 1 and 2), IAS thickness at least 2 but less than 3 mm (between 2 and 3), and IAS thickness at least 3 mm. The statistics for the length of the patient's life with the stoma for each IAS thickness category are summarized in Table 1.

With IAS thickness as a categorical variable we performed analysis of variance (ANOVA) to detect any significant relation between the IAS thickness and the length of the patient's life with the stoma. ANOVA yielded no significant results. Therefore we believe that we do not have enough evidence to draw any significant conclusion regarding the length of the patient's life with the stoma and IAS thickness.

The length of the patient's life with the stoma versus IAS echogenicity

The IAS echogenicity was recorded as a categorical variable with three categories: "0" –

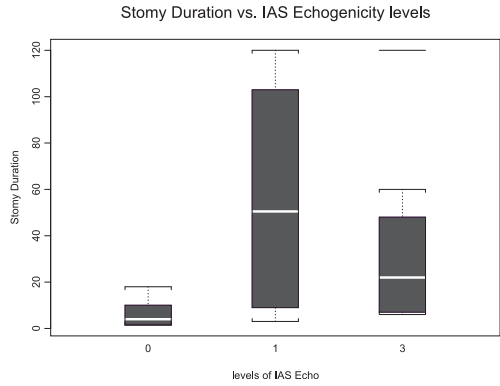
**Table 1.** Summary statistics for the length of the patient's life with the stoma versus IAS thickness category

IAS thickness (in mm)	Mean length of life with stoma (in months)	95 % Confidence Interval* for mean length of life with stoma (in months)	Number of patients
Below 1	24.94	(0, 55.6)	9
Between 1 and 2	43.57	(0, 110.3)	7
Between 2 and 3	42.67	(0, 86.17)	6
At least 3	11.17	NA (only 3 observations)	3
Overall	32.76	(12.8, 52.7)	25

\*The confidence intervals were truncated from below at zero

normal, not changed, "1" – increased echogenicity in the deep part of the anal canal, "2" – increased echogenicity in the superficial part of the anal canal, "3" increased echogenicity of the entire muscle. ANOVA confirmed a significant effect (p value = 0.0001) of the length of the patient's life with the stoma on echogenicity. That means that not all the mean lengths in different echogenicity categories were the same. Further analysis (pairwise comparisons) showed that the mean length of the patients' life with the stoma in normal ("0") echogenicity category was significantly shorter (p value = 0.01) than that of the patients with an increased echogenicity (categories "1", "2" and "3" combined). Moreover, the mean length of the patients life with the stoma in the "0" echogenicity category was significantly shorter (p value = 0.0059) than that of the patients in the "1" echogenicity category. All other pairwise comparisons of the mean lengths of the patients' life with the stoma in different IAS echogenicity categories were not significant. The statistics for the length of the patient's life with the stoma for each IAS echogenicity category are summarized in Table 2.

The "box-and-whiskers" Figure 2 shows different distributions of the lengths of the patient's life with the stoma (in months) for the three main echogenicity categories. The solid horizontal line in each box is located at the median of the length of the patient's life with the stoma. The ends of the box show the lower and upper quartiles and "whiskers" ex-



Levels of IAS echogenicity: 0-normal IAS echogenicity; 1-increased echogenicity of the IAS in a deep part of the anal canal; 3-increased echogenicity of the whole sphincter.

**Figure 2.** The length of life with the stoma versus IAS echogenicity levels.

tend to the maximum and minimum values of the length of the patient's life with the stoma for each IAS echogenicity category. Note the visible increase of the average length of life with the stoma of the patients with increased echogenicity.

The length of the patient's life with the stoma versus IAS borders definition

The IAS border/margin definition was recorded as a categorical variable with three categories: "0" – normal, not changed, "1" – decreased border definition in the deep part of the anal canal only, and "2" – decreased bor-

**Table 2.** Summary statistics for the length of the patient's life with the stoma versus IAS echogenicity

IAS echogenicity category	Mean length of life with stoma (in months)	95 % Confidence Interval* for length of life with stoma (in months)	Number of patients
0	5.95	(2.02, 9.88)	10
1	56	(0, 145.48)	4
2	NA (only one observation)	NA	1
3	34.35	(8.68, 60.02)	10

\*The confidence intervals were truncated below at zero

**Table 3.** Summary statistics for stoma duration versus IAS border definition category

IAS border definition	Mean length of life with stoma (in months)	95 % Confidence Interval* for mean length of life with stoma (in months)	Number of patients
0	31.93	(2.41, 61.45)	15
1	17.67	(0, 52.86)	6
2	58.5	(0, 133.42)	4

\*The confidence intervals were truncated below at zero

**Table 4.** Summary statistics for the mean length of life with stoma versus the results of the dynamic exam

Dynamic exam result	Mean length of life with stoma (in months)	95 % Confidence Interval* for mean length of life with stoma (in months)	Number of patients
1	15.38	(0, 43.98)	4
2	8.17	(0, 29.76)	3
3	40.72	(13.54, 67.91)	18

\*The confidence intervals were truncated below at zero

der definition in the entire muscle. ANOVA detected no significant effect of the border definition on the mean length of the patient's life with the stoma. The statistics of the length of the patient's life with the stoma for each IAS border definition category are summarized in Table 3.

The length of the patient's life with the stoma versus the results of dynamic examination

Dynamic exam results were recorded as a categorical variable with three categories: "1" – low, "2" – poor, and "3" – good contraction capabilities. ANOVA showed no significant effect of the mean length of the patient's life with the stoma on the dynamic exam results. The statistics for the length of the patient's life with the stoma for each exam result category are summarized in Table 4.

## Discussion

Endosonographic assessment of the anal sphincters is very important before deciding

for decolostomy after Hartmann's operations or closing a loop colostomy.

We did not find any information on the anatomy of the anal sphincters after colostomy with defunctioning ileostomy in the literature. There is very little information about the anatomy of these muscles after IPAA where the thickness of the IAS is significantly smaller compared with normal subjects.<sup>4,5</sup> This finding was also the most striking abnormality we found in the majority of the patients after colostomy. Twenty two patients (88%) had a thin IAS with the mean thickness 1.62 mm. Twenty of them (90.90%) had a circular reduction of the IAS thickness and the remaining two (9.09%) partial, i.e. restricted to one or two walls. Within the group with a circular thinning of the IAS, twelve (60%) had the entire muscle equally thin, in the remaining eight (40%), the thinning was seen only within the posterior or lateral walls and in the distal or proximal part of the anal canal.

The IAS thickness and proportion of fibrous tissue increases with age.<sup>1</sup> Several hypothetical reasons for the thinning of IAS are being proposed, such as denervation, ische-

mia or changes caused by direct trauma to the IAS as in patients after the ileal pouch anal anastomosis (IPAA) due to transanal mucosectomy.<sup>4-6</sup> This thinning, however, was visible in the patients with mucosectomy as well as after handsewn anastomosis. During the IPAA, the brunt of the injury is due to the dissection and mobilization of the anorectum, which may damage the extrinsic autonomic nerve supply that is crucial for the IAS function.<sup>7</sup> The transection of the rectal wall at the level of the levator ani muscles may cut through the layer of specialized circular muscle that forms the IAS. The damage so inflicted involves the intramural nerve plexus, blood supply and the muscle itself. Such direct damage to the IAS at this level is presumably inevitable.<sup>6</sup> The transection at a higher level, as in the case of our patients, is unlikely to produce such defect. In a study which used anal manometry and endosonography, a strong correlation between the endosonographic thickness of the IAS and the resting pressure was found.<sup>1,8</sup> There are, of course, several reasons leading to abnormal image of the IAS in AUS, including the thinning of this muscle. Passive fecal incontinence is related to the degeneration of the IAS smooth muscle, where the muscle atrophies and is replaced by fibrous tissue.<sup>9</sup> AUS reveals thin, hyperechoic sphincter with poor defined margins, without the usual increase in the thickness of the IAS with age. This condition affects predominantly older men and women. Mean age of our population with colostomy was 76 years and we cannot exclude this fact as accountable for the abnormalities in the IAS detected by the anal ultrasound, especially since very few patients had evidence of structural defects of IAS or EAS and of an EAS weakness. Likewise, in neurogenic, idiopathic incontinence, the denervation of the EAS and pelvic floor muscles is associated with the damage to the IAS.<sup>10</sup> The muscle damage is probably the result of autonomic denervation. In our material, the scars of the

EAS were seen in 4 patients: in 3 women, of whom 2 were without risk factors for the sphincter damage and one having a typical episiotomy scar, and a man who was incontinent for gas. He was the only patient suffering from fecal incontinence before colostomy was performed. He was 76 years old with a colostomy for 16 years. Anal ultrasound detected a thinning only in the proximal part of the IAS, the increased echogenicity only in the distal part of the anal canal, and the scars in the EAS not affecting its contraction in the dynamic examination.

Thirty-eight per cent of women with forceps deliveries experience symptoms of incontinence and up to 2% of women delivering vaginally have a third-degree obstetric tear involving one or both of the anal sphincters.<sup>1</sup> Although women constitute the main group suffering from fecal incontinence, none of our patients did have it. However, there were a few with the risk factors, including two with obstetric tears, two others after forceps deliveries, and four having delivered babies with the birth weight exceeding 4000 g. In AUS, the thinning of the IAS was seen in all of them, the increased echogenicity of the whole muscle in six; and in the proximal part of the anal canal in the remaining two. In one case, a scar after episiotomy was seen. The dynamic examination was normal. In this group, two women who had babies with the birth weight exceeding 4000 g and two with the second-degree tears of the peritoneum suffered from constipation for more than 10 years.

AUS may be considered to be used also in the patients with obstructed defecation in order to identify those patients with internal sphincter hypertrophy or its degeneration after permanent constipation with straining. In our group, 6 patients suffered from constipation for more than 10 years before colostomy was done.<sup>11</sup> AUS revealed thinning, increased echogenicity and not well-defined margins of the IAS in 4 of them; in another 2 only the thinning of the IAS was seen.

We regarded the length of the patient's life with the stoma as the main factor accountable for an abnormal image of the sphincters in AUS. Three patients had the normal thickness of the IAS (at least 3 mm) and their mean time of life with the colostomy was 11.17 months. Nine patients with the IAS thickness below 1 mm (which was the smallest) had the colostomy for mean 24.94 months. Seven patients with the IAS thickness at least one but below 2 mm had colostomy for 40.57 months on average. The thickest but still thin (at least 2 but below 3 mm) IAS was seen in 6 patients with colostomy for a mean time of 42.67 months. It is interesting that patients with the shortest life with the stoma (mean 11.17 months) had normal thickness of the IAS, whereas in the rest of the patients with longer life with the stoma the IAS was thinned. The results of the statistical analysis however didn't show any significant difference between the IAS thickness and the length of life with stoma. The IAS was the thinnest in the patients with the average life with the stoma of 24.94 months and it was the thickest in the patients with a longer period of colostomy.

The analyses of the IAS echogenicity showed that it was increased in 15 of the patients (60%). Nine patients (60%) had the colostomy for more than a year (mean 7.71 years) and 6 (40%) less than a year. The length of time with the stoma appeared to correlate well with the echogenicity disturbances within the IAS. The most typical was the circular increase of echogenicity seen within the whole length of the IAS (10 patients – 66.62%); however, there was no correlation, if not reverse, between the length of the patient's life with the stoma and the range of abnormal echogenicity. A circular defect was seen in the patients with the mean colostomy of 34.35 months. A partially increased IAS was seen in the deep part of the anal canal after an average of 56 months of life with colostomy and in the distal part of the anal canal in the patient with the longest life with the

stoma (16 years). Our statistical analysis showed that the mean life with the stoma in the patients with normal echogenicity of the IAS was significantly shorter than that in the patients with increased echogenicity ( $p=0.01$ ). However we could not find any significant correlation between the subgroups of patients with the abnormal echogenicity of the IAS and their length of life with colostomy.

The margins of the IAS were not well defined in 10 patients (40%) and in most of them (seven cases – 70%) already after a mean colostomy of 5.28 months. Although this abnormality was seen in less than half of the patients, it appeared to have inflicted the IAS very early. Also, interestingly, 6 out of these 10 patients did not have well defined margins of the IAS only inside a deep part of the anal canal and all but one of them had the stomas for less than one year (mean 17.67 months). In 4 remaining cases, the whole sphincter had abnormal margins and these were all cases except one with a long life with the stoma (mean 58.5 months). ANOVA however, showed no significant correlation between the length of the patient's life with the stoma and the border definition defects.

We have not performed manometry or electromyography (EMG); so, the only way we could assess the function of the striated muscle was the anal ultrasound during contraction of the anal sphincter. This imaging technique applied during contraction of the anal sphincter is a useful adjunct to the standard study at rest. It gives better definition of the EAS and PR and is helpful in defining whether or not a defect is present.<sup>2</sup> The ultrasound image of a defect correlates well with absent electromyographic activity, and the former is more accurate at picking up lesions.<sup>1</sup> Eventually, anal endosonography reduced the need for EMG to identify EAS defects. In our group of patients with no contraction (4 cases), AUS depicted scars inside the EAS in one case only. There was no



history of obstetric trauma, operations or any factors that could lead to such a defect. Poor contraction was seen in 3 patients, 2 of them women (one delivered a large baby with the birth weight exceeding 4000 g, the second had forceps delivery) and one man with no risk factors. The impaired contraction of the EAS and PR was also not related to the length of life with the colostomy. The mean length of life with the stoma in the majority of the patients with good contraction (18 patients- 72%) was 40.66 months. In the patients with poor contraction (3 patients- 12%), that mean length was 8.16 months and in patients without contraction (4 patients; 16%), the mean life with the stoma was 15.37 months. No significant effect of the length of the patient's life with the stoma on the dynamic exam result was found.

This study confirmed the suspicion that the patients after colostomy have anal sphincters, especially IAS defects. In an attempt to identify other factors predictive of the anal sphincter complications, we took into account the age, gender, obstetric history, history of constipations, fecal incontinency and the length of the patient's life with the stoma. It appeared that only a few of analyzed factors had an effect on the sphincters defect. These findings were unexpected to us because we thought that constipation, obstetric trauma, as well as the length of the patient's life with the stoma would have a significant effect on the sphincter outcome. In our study, we found a correlation only between the length of the patient's life with the stoma and the changes in echogenicity of the IAS. However, there was no correlation between the length of life with colostomy and the range of those defects. The thickness of the IAS was preserved in patients with the short life with the stoma, but there was no correlation between the patient's length of life with the stoma and thinning of the IAS. Although our findings could implicate the dysfunction of the IAS, we would like to emphasize that their value is

limited because manometry, electromyography or pudental nerve terminal motor latency (PNTML) were not performed in order to obtain a better assessment of the function deterioration of the IAS. The obstetric history, tears, forceps and birth weight exceeding 4000 g showed surprisingly little correlation with the IAS defects. All 8 women with the above risk factors had thin IAS, but only in 2 of them, the whole muscle was thin. In majority of cases, the increased echogenicity of the IAS was noted; in most of them, it involved the whole muscle, but 4 of them also experienced coexisting constipations. We have a few explanations for these findings. First, our population of patients was older (mean age 76 years) and presumably many other comorbid illnesses had influenced the image of the IAS, including degeneration mentioned above. Second, constipations lasting for a long time with accompanying straining can lead to the degeneration manifested in AUS as thinning, increased echogenicity and poorly defined borders of the IAS. Six our patients with colostomy suffered from constipation and all of them had thin IAS, whereas increased echogenicity and not poorly defined margins were seen in four of them. Third, presumably the most crucial defect of the presented group of patients is the degeneration of the anal sphincters as the result of a lack of the intestinal passage in the rectum and of abnormal activity of the sphincter muscles during the defecation.

Endosonographic assessment of the anal sphincters is very important before deciding for decolostomy after Hartmann's operations or closing a loop colostomy. A reduction of thickness of the IAS and as circular reduction inside the whole muscle is the most typical disorder for this condition due to the stoma. No correlations were found between the extent of the thinning and the length of the patient's life with the stoma, although the thickness was well preserved through the first year after colostomy was done. A discrepancy

was also noticed among the length of life with the stoma and the range of increased echogenicity of the IAS. This defect occurred late after colostomy. Although echogenicity was normal in patients with the shortest colostomy in comparison to those with a longer ones, between those with a longer colostomy with different range of the echogenicity defects no correlation was found. Our statistical analysis showed that the only characteristic of the IAS and EAS significantly associated with the length of the patient's life with the stoma was the IAS echogenicity and that this variable was preserved only in the patients with the shortest colostomy.

The margins defect occurred early after the colostomy had been performed and, with time, the range of this defect increased. However, the results of the statistical analysis showed no significant correlation between those two: the length of life with colostomy and the borders defect.

### References

1. Kamm MA. Obstetric damage and faecal incontinence. *Lancet* 1994; **10**: 730-3.
2. Rieger NA, Downey PR, Wattchow DA. Short communication: endoanal ultrasound during contraction of the anal sphincter-improved definition and diagnostic accuracy. *Br J Radiol* 1996; **69**: 665-7.
3. Johnson RA, Wichern DW. *Applied multivariate statistical analysis*. London: Prentice Hall; 1992.
4. Silvis R, Eekelen JW, Delemarre JBVM, Gooszen HG. Endosonography of the anal sphincter after ileal pouch-anal anastomosis. *Dis Colon Rectum* 1995; **38**: 383-8.
5. Tuckson W, Lavery I, Oakley J, Church J, Milsom J. Manometric and functional comparison of ileal pouch anal anastomosis with and without anal manipulation. *Am J Surg* 1991; **161**: 90-6.
6. Lavery IC, Tuckson WB, Easley KA. Internal anal sphincter function after total abdominal colectomy and stapled ileal pouch-anal anastomosis without mucosal proctectomy. *Dis Colon Rectum* 1989; **32**: 950-3.
7. Williams NS, Marzouk DEMM, Hallan RI, Waldron DJ. Function after ileal pouch and stapled pouch-anal anastomosis for ulcerative colitis. *Br J Surg* 1989; **76**: 1168-71.
8. Speakman CTM, Kamm MA. The internal anal sphincter-new insights into faecal incontinence. *Gut* 1991; **32**: 345-6.
9. Vaizey CJ, Kamm MA, Bartram CI. Primary degeneration of the internal anal sphincter as a cause of passive faecal incontinence. *Lancet* 1997; **349**: 612-5.
10. Lubowski DZ, Nicholls RJ, Burleigh DE, Swash M. Internal anal sphincter in neurogenic fecal incontinence. *Gastroenterology* 1988; **95**: 997-1002.
11. Nielsen MB, Rasmussen OO, Pedersen JF, Christensen J. Anal endosonographic findings in patients with obstructed defecation. *Acta Radiol* 1993; **34**: 35-8.