

# Localized Darier's disease

D. Milobratović, J. Vukićević

## KEY WORDS

localized Darier's disease, ATP2A2, mosaicism, mutation

## Introduction

Darier's disease (DD) is an autosomal dominant dermatosis characterized by warty, hyperkeratotic papules that are particularly dense in the seborrheic areas and flexures, palmar pits, and nail dystrophy. Associated findings include "cobblestoning" of oral mucous membranes and various neuropsychiatric abnormalities.

It was reported that mutations in the gene *ATP2A2*, located on chromosome 12q23-24.1, cause DD (1). *ATP2A2* encodes the sarcoplasmic/endoplasmic reticulum  $\text{Ca}^{2+}$  ATPase isoform 2 protein (SERCA2), which is a calcium pump. It seems likely that the mutation interferes with the normal internal calcium "signaling" that regulates processes such as cell proliferation, differentiation, and adhesion between keratinocytes (2). Family members with confirmed identical *ATP2A2* mutations can exhibit differences in the clinical severity of the disease, suggesting that other genes or environmental factors affect the expression of DD (3).

The localized (zosteriform, segmental) form of DD was first reported by Kreibich in 1906 (4). It is characterized by the keratotic papules being unilaterally distributed in streaks or whorls following Blasch-

ko's lines (2). The average age of the onset of the disease is during childhood or adolescence, with no sex predilection. Skin lesions are aggravated by sunlight, heat, or sweating (5). It is thought that the localized form of Darier's disease reflects genetic mosaicism arising from a mutation in early embryogenesis.

We present a patient with linear Darier's disease successfully treated with tretinoin 0.05% cream.

## Case Report

A 83-year-old man presented with a pruritic eruption on the right side of his trunk persisting for 20 years, which tended to worsen during summer. There was no family history of a similar skin disease. Examination revealed hyperkeratotic, brownish papules extending in a linear pattern from the back to the right side of the abdomen (Fig. 1). There were no palmar pits or mucous membrane or nail involvement. A biopsy specimen revealed acantholytic dyskeratotic cells in the upper epidermis, suprabasal clefts with focal hyperkeratosis, and parakeratosis (Fig. 2), which were consistent with the clinical diagnosis of the localized form of Darier's disease. Routine laboratory tests were within normal levels.

Treatment with tretinoin 0.05% cream for two months led to significant resolution of the lesions.

## Discussion

Darier's disease (DD), a dominantly inherited skin condition, is characterized by hyperkeratotic papules coalescing to warty patches on symmetrical areas of the face, trunk, and flexures of the extremities. Mutations in the ATP2A2 gene encoding SERCA2, which has an important role in Ca<sup>2+</sup> signal transduction, have been identified as the molecular basis of DD (1). Although it is not clear how the loss of SERCA2 function causes DD, selective inhibition of SERCA pumps has been shown to interfere with the formation of intercellular junctions and cell-cell adhesion (2, 6).

It has long been known that autosomal dominant skin disorders, which usually present diffuse and symmetrical involvement, may also show a segmental arrangement that most likely reflects mosaicism. The localized form of DD is rare. It has been estimated that in 10% of cases of DD the lesions are distributed unilaterally, in a linear pattern following the lines of Blaschko. These patients have no family history of Darier's disease or similar skin conditions (5). It has been postulated that localized DD is caused by genetic mosaicism.

According to Happle et al., two types of segmental manifestation can be distinguished in autosomal dominant skin diseases (7). Type 1 reflects heterozygosity for a *de novo* postzygotic mutation occurring in early embryogenesis and shows a degree of severity similar to that encountered in the non-segmental phenotype. Outside the segmental areas, the skin is perfectly normal (7). Type 1 may also herald gonadal

mosaicism, which may lead to transmission of the diffuse, non-segmental form to the next generation.

Type 2 manifestation tends to occur in heterozygous embryos which later develop a nonsegmental, diffuse distribution of skin lesions. A postzygotic mutation occurring at an early developmental stage would result in loss of heterozygosity and give rise, in a segmental area, to a homozygous or hemizygous state of the underlying mutation. Clinically, type 2 shows markedly more severe involvement with pronounced segmental lesions being superimposed on the ordinary nonsegmental phenotype (7). Accordingly, the linear lesions presented in our case would represent type 1 segmental DD.

Epidermal nevi with acantholytic dyskeratotic histology show clinical and histological similarities to DD (1). Like DD, many of these epidermal nevi may be exacerbated by heat, sweating, and sunburn. The histological characteristic of both Darier's disease and this form of epidermal nevus is acantholytic dyskeratosis (1). On the basis of those clinical and histologic similarities, linear acantholytic dyskeratotic nevus has been often classified as localized DD (1, 5). In 2000, Sakuntabhai et al. provided evidence that acantholytic dyskeratotic nevi can arise from a somatic mutation in ATP2A2, the gene that is also defective in generalized DD, and that the term "acantholytic dyskeratotic nevus" might be replaced in the future by "segmental DD induced by postzygotic mosaicism" (1).

The differential diagnoses of localized DD include herpes zoster, lichen striatus, Grover disease, lichen planus, and linear nevoid disorder (8).

There are no reports of patients with localized DD transmitting generalized disease. The risk of transmis-

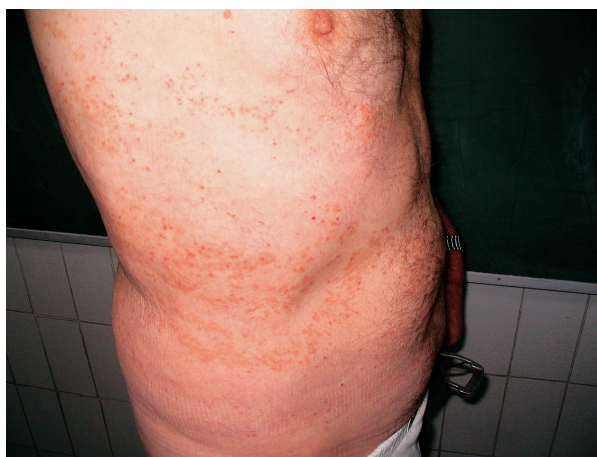

Figure 1. Multiple, crusted, keratotic, erythematous papules with a Blaschko-linear distribution on the right side of the trunk.

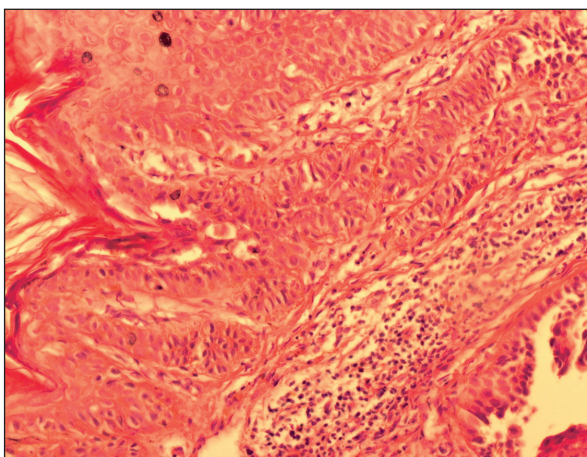


Figure 2. Hyperkeratosis, acantholysis, dyskeratotic keratinocytes, corps ronds, and corps grains in the epidermis (hematoxylin and eosin; original magnification  $\times 100$ ).

sion of generalized disease will depend on whether the germline is affected. With regard to genetic counseling of patients with DD restricted to cutaneous areas following Blaschko's lines, this possibility must be taken into account. One must be cautious about using the extent of the disease alone as the basis for counseling patients because the limited cutaneous manifestation may not reflect the true extent of mosaicism.

## REFERENCES

1. Sakuntabhai A, Ruiz-Perez V, Carter S, et al. Mutations in ATP2A2, encoding a Ca<sup>2+</sup> pump, cause Darier's disease. *Nat Genet.* 1999;21:271-7.
2. Gilaberte M, Puig L, Vidal D, Alomar A. Acantholytic dyskeratotic naevi following Blaschko's lines: a mosaic form of Darier's disease. *J Eur Acad Dermatol.* 2003;17:196-9.
3. Onozuka T, Sawamura D, Yokota K, Shimizu H. Mutational analysis of the ATP2A2 gene in two Darier disease families with intrafamilial variability. *Br J Dermatol.* 2004;150:652-7.
4. Kreibich K. [Essentials regarding Darier's disease (psorospermosis)]. *Arch Dermatol Syph.* 1906;80: 367. German.
5. O'Malley MP, Haake A, Goldsmith L, Berg D. Localized Darier disease. *Arch Dermatol.* 1997;133:1134-8.
6. Muller EJ, Caldelari R, Kolly C, et al. Consequences of Depleted SERCA2-Gated Calcium Stores in the Skin. *J Invest Dermatol.* 2006;126:721-31.
7. Happle R. A rule concerning the segmental manifestation of autosomal dominant skin disorders: review of clinical examples providing evidence for dichotomous types of severity. *Arch Dermatol.* 1997;133:1505-9.
8. Brazzelli V, Prestinari F, Barbagallo T, et al. Linear Darier's disease successfully treated with 0.1% tazarotene gel "short-contact" therapy. *Eur J Dermatol.* 2006;16:59-61.

**A U T H O R S ' A D D R E S S E S** *Danica Milobratović, MD, Department of Dermatovenereology, Military Medical Center, New Belgrade, Bulevar Arsenija Carnojevića 48, 11070 Belgrade, Serbia, Tel.: +381 63 86 74 938, +381 11 2137 175, E-mail: drdanicamilo@gmail.com*  
*Jelica Vukićević, PhD, Clinic of Dermatovenereology, Faculty of Medicine, Clinical Center of Serbia, Belgrade, Serbia*