

Combined local and systemic bleomycin administration in electrochemotherapy to reduce the number of treatment sessions

Felipe Maglietti^{1,2}, Matias Tellado^{1,3}, Nahuel Olaiz^{1,2}, Sebastian Michinski^{1,2}, Guillermo Marshall^{1,2}

¹ Laboratorio de Sistemas Complejos, Departamento de Computación e Instituto de Física del Plasma, Facultad de Ciencias Exactas y Naturales, Universidad de Buenos Aires, Buenos Aires, Argentina

² Consejo Nacional de Investigaciones Científicas y Técnicas, Buenos Aires, Argentina

³ Facultad de Ciencias Veterinarias, Universidad de Buenos Aires, Buenos Aires, Argentina

Radiol Oncol 2016; 50(1): 58-63.

Received: 20 October 2015

Accepted: 18 January 2016

Correspondence to: Felipe Maglietti, Laboratorio de Sistemas Complejos, Departamento de Computación e Instituto de Física del Plasma, Facultad de Ciencias Exactas y Naturales, Universidad de Buenos Aires, Intendente Güiraldes 2160, Buenos Aires, Argentina.
E-mail: felipemaglietti@gmail.com

Disclosure: No potential conflicts of interest were disclosed.

Background. Electrochemotherapy (ECT), a medical treatment widely used in human patients for tumor treatment, increases bleomycin toxicity by 1000 fold in the treated area with an objective response rate of around 80%. Despite its high response rate, there are still 20% of cases in which the patients are not responding. This could be ascribed to the fact that bleomycin, when administered systemically, is not reaching the whole tumor mass properly because of the characteristics of tumor vascularization, in which case local administration could cover areas that are unreachable by systemic administration.

Patients and methods. We propose combined bleomycin administration, both systemic and local, using companion animals as models. We selected 22 canine patients which failed to achieve a complete response after an ECT treatment session. Eleven underwent another standard ECT session (control group), while 11 received a combined local and systemic administration of bleomycin in the second treatment session.

Results. According to the WHO criteria, the response rates in the combined administration group were: complete response (CR) 54% (6), partial response (PR) 36% (4), stable disease (SD) 10% (1). In the control group, these were: CR 0% (0), PR 19% (2), SD 63% (7), progressive disease (PD) 18% (2). In the combined group 91% objective responses (CR+PR) were obtained. In the control group 19% objective responses were obtained. The difference in the response rate between the treatment groups was significant ($p < 0.01$).

Conclusions. Combined local and systemic bleomycin administration was effective in previously to ECT non responding canine patients. The results indicate that this approach could be useful and effective in specific population of patients and reduce the number of treatment sessions needed to obtain an objective response.

Key words: electrochemotherapy; combined treatment; systemic and local; bleomycin; resistant

Introduction

Electrochemotherapy (ECT) is an ablative approach that is rapidly growing, both in human and veterinary medicine. ECT is based on administration of bleomycin followed by application of an electric field on the tumor that enhances cell permeability to the drug. This technique can increase bleomy-

cin cytotoxicity by 1000 fold. The effectiveness of ECT is approximately 80% objective response (OR) rate.^{1,2}

A meta-analysis of ECT clinical studies in human oncology showed that the overall OR rates vary from 62.6% and 82.2% OR rate depending also on the route of the drug administration, being either intravenous or intratumoral.³ Despite its

success related to its low cost and minimum side effects, ECT still has room for improvement. Even with such a high response rate there are 20% of cases on which attention must be focused in order to improve the outcome of the treatment.

The application of ECT in companion animals showed the same pattern of success as in humans, with many studies demonstrating its high efficiency, with a very similar response rate to that of human patients.^{4,5}

The use of companion animals with spontaneous tumors as models for tumor treatment therapy became a generalized practice due to its many advantages. The most important is that these tumors behave similarly to human ones and are thus better preclinical models for testing new therapies. As these animals were exposed to environmental carcinogens, they developed the tumors in the context of an intact immune system that has the same tumor-host interactions.^{6,7}

A study on melanomas in dogs conducted by Spugnini *et al.* reported 80% effectiveness.⁸ Another study by Tamzali *et al.* on spontaneously occurring tumors showed very high effectiveness when treating sarcoid tumors in equines using ECT with local cisplatin in up to 6 sessions of ECT.⁹ A ganglioneuroblastoma case was published in which a cat with a very small tumor was treated with up to 3 sessions of ECT in order to obtain an OR.¹⁰ In large tumors, however, it is often the case that no OR is possible with a single treatment session.^{11,12}

Systemic bleomycin administration consists of injecting the drug into a vein, thus allowing the drug to reach the tumor through the bloodstream and diffuse from the vessels into the tumor.¹³ On the other hand, local bleomycin administration consists of directly injecting the drug into the tumor tissue, thus allowing it to diffuse from the injecting point to the target. Multiple injections into the tumor can provide an adequate coverage in small tumors¹³, but the case of large tumors is different where it is very difficult to homogeneously cover them. Tumor vasculature is structurally and functionally abnormal; blood vessels leak and are tortuous, dilated, and saccular and have a random pattern of interconnection.¹⁴ In solid tumors, these aberrant vessels determine an increase in the liquid outlet out of these, together with the contribution of the compression caused by the proliferation of cancer cells, leading to an increase in interstitial hydrostatic pressure.¹⁵ The heterogeneous flow of blood and interstitial hypertension pose a serious obstacle to the antineoplastic agents, especially in the case of large tumors with a broader vascular system that

are more likely to have areas of tumor that cannot be reached by the systemic route.^{16,17} This characteristic of tumor vessels could lead to an insufficient bleomycin distribution when administered systemically. Repeated ECT sessions could lead to modifications in the characteristics of the tumors, such as its size reduction and changes in its vasculature that improve treatment response after each session. For these reasons, performing many treatment sessions can improve the results obtained in the first session, increasing, however, the cost of the treatment and its risks related to multiple anesthetic procedures. To address this problem, here, we propose combined bleomycin administration, both systemic and local, using companion animals as models for ECT tumor treating.

The aim of this study was to determine whether it is possible to reduce the number of treatment sessions using a combined administration of bleomycin (both systemic and local) *vs.* systemic bleomycin administration alone in ECT. Accordingly, for the purpose of this work, we selected companion animals with spontaneous tumors.

Patients and methods

Patients

Consent was obtained from the dog's owner to use the dog's image in this scientific work and for the treatment of the other patients. In all cases, all recommendations from the Consejo Profesional de Medicos Veterinarios de Buenos Aires (Buenos Aires Veterinary Council) were observed, as well as the relevant local legislation in Argentina, Act No. 14072 which governs veterinary medicine practice.

Twenty-two patients from the oncology service from the Centro de Especialidades Medicas Veterinarias (CEMV), Buenos Aires, Argentina, were selected. These patients had tumors of a varied histology and had failed to achieve a complete response after an ECT treatment session. We divided them into two groups: eleven received combined bleomycin administration in a second treatment session, and 11 underwent another standard ECT session (control group). The first ECT session in both groups and the second ECT session in the control group were performed in accordance with the Standard Operating Procedure for Electrochemotherapy.¹³ The patients were allocated on a 'first come, first served' basis to the control group first, and from the eleventh patient onwards, they were allocated to the combined administration group. The size of their tumors was

calculated by multiplying their two diameters and their height.

The patients underwent a full clinical examination, blood samples were taken, and a biopsy for histological confirmation of the tumor was performed. The histological analysis of the biopsies was performed with hematoxylin-eosin staining. Most patients treated in the first session were expected to require further ECT sessions in order to obtain an objective response because of their tumor size.

Treatment procedure

General anesthesia procedure consisted of premedication with 0.5 mg/kg of xylazine (Xilacina 100[®], Richmond, Buenos Aires, Argentina), 2 mg/kg of tramadol (Tramadol[®], John Martin, Buenos Aires, Argentina) and induction with 3 mg/kg of propofol (Propofol Gemepe[®], Gemepe, Buenos Aires, Argentina). Then maintenance was assured with 2–3% of isoflurane (Zuflax[®], Richmond, Buenos Aires, Argentina) and 2 mcg/kg of fentanyl (Fentanilo Gemepe[®], Gemepe, Buenos Aires, Argentina). Meloxicam (Meloxicam Denver Farma[®], Denver Farma, Munro, Argentina) 0.2 mg/kg was administered for analgesia after the treatment. This scheme of anesthesia provided adequate comfort during the treatment. Prophylactic antibiotic amoxicillin/clavulanic acid (Clavamox[®] Zoetis[®], San Isidro, Argentina) 12.5mg/kg/bid was administered.

ECT with systemic bleomycin administration alone was performed as follows: the patient was anesthetized using general anesthesia, after an intravenous bolus of bleomycin (Blocamicina[®], Gador, Buenos Aires, Argentina) at a dose of 15 000 IU/m² BSA in 30–45 seconds was administered. Eight minutes after the intravenous injection, to allow drug distribution, the pulses were delivered covering the whole tumor surface.

ECT with systemic and local bleomycin administration was performed as follows: the patient was anesthetized using general anesthesia. An intravenous bolus of bleomycin (Blocamicina[®]) at a dose of 15 000 IU/m² BSA in 30–45 seconds was administered, after a local injection of bleomycin (Blocamicina[®]) at a dose of 125 IU/cm³ of tumor was administered.¹³ The drug was injected into the tumor using a 27G 2.5 cm needle (Terumo, Tokyo, Japan) in a 3 ml syringe (Darling, Korea), and for an even distribution of the drug, the injections were placed 5 mm apart in one plane and 2 or 3 planes of injections were placed 1 cm apart according to the size of the tumor. The injections started

at the center of the tumor and continued at its periphery.⁹ Healthy margins were not injected with bleomycin since they are covered by the systemic administration of the drug; there are no vascular abnormalities in healthy tissue to justify the additional administration.

The pulses were administered using a six needle electrode, consisting of three rows of two needles 2 cm long and 1 mm diameter, each row separated by 4 mm and each column separated by 8 mm. The pulse generator used was a BTX ECM 830 (Harvard Apparatus, Holliston, MA, USA). A train of 8 electric pulses (1000 V/cm, 100 microseconds, 10 Hz) was applied, covering the whole tumor¹³, beginning at the periphery of the tumor in a circular fashion in order to have maximum drug concentration at the margins and prevent the spreading of tumor cells. The superposition of electric fields was avoided in order to prevent overtreatment of the lesions.

The response to each treatment was evaluated according to the WHO criteria for tumor response¹⁸, 30 days after the treatment. A complete response (CR) is obtained when there is a complete disappearance of all known disease, a partial response (PR) when there is a 50% reduction of the tumor or more, a stable disease (SD) when PR or PD criteria are not met, and a progressive disease (PD) when there is a 25% or more increase in the size of the tumor, and no CR, PR or SD is documented before the increase of the disease or new lesions appear. All of this must be confirmed within 4 weeks after the treatment.

After the treatment, the patients returned to the veterinary clinic within 7, 15, 21, 30 and 60 days in order to evaluate response, toxicity and side effects by means of a full clinical examination and questions to their owners.

Results were compared and statistical significance was evaluated using the chi square test.

Results

The total dose of bleomycin in combined treatment was slightly higher than that of systemic administration alone; in both cases, no toxicity or side effects were reported. Table 1 shows the response of the patients in which combined treatment was performed in the second session. Table 2 shows the control group, for which patients the second session was a repetition of the first procedure.

The responses obtained with combined bleomycin administration were significantly different

TABLE 1. List of group 1 patients treated using combined systemic and local bleomycin administration in the second treatment session

Patient	Breed	Location of the tumor	Weight (kg)	Histology	Stage	Size (cm ³)	Response 1 (ECT)	Response 2 (S+L)
1	Labrador retriever	Oral	32	Mastocytoma	II	10.6	PR	CR
2	Cross-breed	Oral	21	Squamous cell carcinoma	II	36.2	SD	PR
3	Labrador retriever	Nasal	32	Squamous cell carcinoma	II	43.5	PR	CR
4	Yorkshire	Perianal	5	Solid differentiated carcinoma	IV	173.8	SD	SD
5	Cross-breed	Elbow	12	Schwannoma	I	67.6	SD	PR
6	Rottweiler	Oral	37	Fibrosarcoma	I	109.5	SD	CR
7	Labrador retriever	Nasal	38	Squamous cell carcinoma	III	42.4	SD	PR
8	Boxer	Oral	37	Fibrosarcoma	III	112.2	SD	PR
9	Cocker spaniel	Oral	15	Melanoma	II	8.7	PR	CR
10	Beagle	Oral	16	Melanoma	III	12.4	PR	CR
11	Cocker spaniel	Oral	16	Melanoma	III	26.64	PR	CR

CR = complete response; ECT = electrochemotherapy; PR = partial response; SD = stable disease; S+L = systemic + local

from those of systemic administration alone in selected cases ($p < 0.01$). In the combined administration group the following response were obtained: CR 54% (6), PR 36% (4), SD 10% (1). In the control group the obtained response were: CR 0% (0), PR 19% (2), SD 63% (7), PD 18% (2). Figure 1 shows a case treated using combined intravenous and intratumoral bleomycin administration in which a CR was obtained.

The OR rates obtained were significantly better when using combined treatment compared with the standard ECT treatment ($p < 0.01$). As seen in Figure 2, in the combined group, 91% (10) of OR (CR+PR) were obtained, and 19% (2) were obtained in the control group.

It is worth noting that no complete responses were obtained in the control group with two sessions of ECT, as opposed to 54% of CR obtained when applying combined treatment in the second session.

The average tumor size in the control group was 99.9 cm³, while it was 58.5 cm³ in the combined group. In general, the patients were at a lower stage of the disease in the control group compared with the combined group.

Discussion

ECT is based on a physical phenomenon, electroporation, which acts directly on cell membranes, which accounts for its effectiveness in practically all histological types of tumors. In our experience with veterinary patients, we found that large tu-

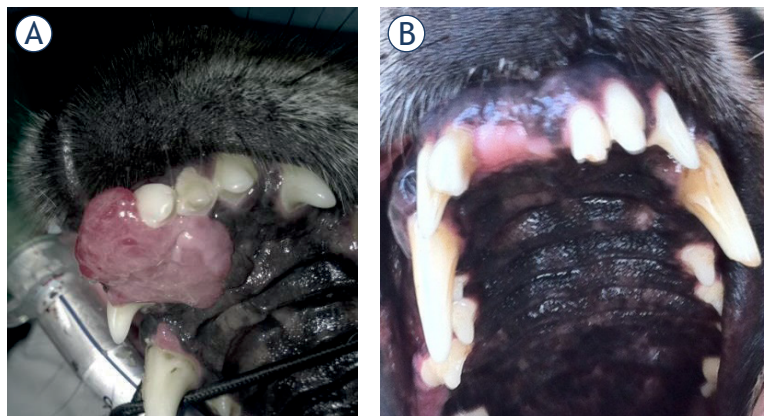


FIGURE 1. Case number 6. (A) before combined treatment, a fibrosarcoma which failed to respond to the first ECT treatment. (B) CR was obtained after combined treatment.

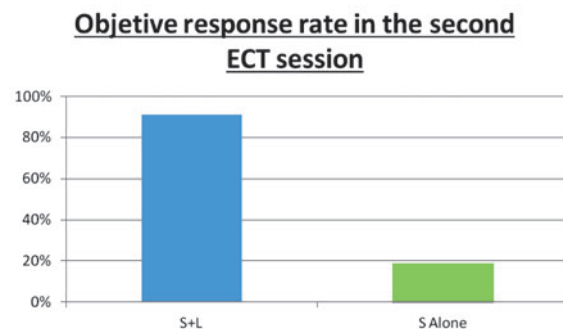


FIGURE 2. Graph shows the objective response rate obtained in the second session, in a comparison between combined bleomycin administration, both systemic and local (S+L), and systemic alone (S Alone).

ECT = electrochemotherapy

TABLE 2. List of group 2 patients (control) treated using a repetition of the first session

Patient	Breed	Location of the tumor	Weight (kg)	Histology	Stage	Size (cm ³)	Response 1 (ECT)	Response 2 (ECT)
12	Cross-breed	Oral	30	Melanoma	I	158.2	PR	SD
13	Cross-breed	Oral	21	Sarcoma	III	79.76	PR	SD
14	Cross-breed	Oral	20	Carcinoma	III	96.5	PR	SD
15	Toy Poodle	Oral	5	Fibrosarcoma	II	23.23	PD	PD
16	Cross-breed	Oral	11	Melanoma	II	73.8	PR	SD
17	Cross-breed	Oral	16	Schwannoma	II	467.02	PD	SD
18	Cross-breed	Oral	6	Squamous cell carcinoma	II	12.32	SD	SD
19	Labrador retriever	Oral	32	Fibrosarcoma	II	40	PR	SD
20	Rottweiler	Oral	34	Melanoma	II	33	PR	PR
21	German Shepherd	Oral	39	Fibrosarcoma	II	101.18	PR	PD
22	Cross-breed	Oral	14	Melanoma	II	14.4	PR	PR

CR = complete response; ECT = electrochemotherapy; PD = progressive disease; PR = partial response; SD = stable disease; S+L = systemic + local

mors have poorer responses and require further sessions to obtain an objective response. Our hypothesis was that the abnormal vasculature of large tumors impedes proper drug distribution when it is administered intravenously, even though this route of drug administration is prescribed for tumors of this size in standard operating procedure (SOP).¹³

Based on this hypothesis, we decided to make an approach by combining both systemic and local bleomycin administration to improve drug distribution in the tumor. In this way, local administration can cover areas where vasculature proves insufficient. There are many reasons against considering using a local injection alone to improve results. According to literature, in tumors above 2 cm in diameter, intravenous administration is recommended.¹³ It is highly challenging to provide proper drug distribution in the tumor by using local administration only, because during its local application, it is easy to leave sections without the adequate drug concentration, and sometimes it is even impossible to reach the base of the lesion.

It is worth mentioning that some authors obtained good response rates with several treatment repetitions. These repetitions lead to changes in the tumor that can improve drug distribution in later applications.^{12,19-22} Here, we obtained good results with only one repetition.

Tamzali *et al.* obtained very good results with a local injection of cisplatin in multiple applications treating sarcoids. It is important to take into account that this kind of tumors behave like benign tumors, thus giving a veterinarian time to perform

multiple treatments. Our scenario is different since these kinds of tumors are significantly large, and the survival of the patients is compromised, so we need to reduce the tumor as fast as possible in order to improve their quality of life. Frequently, patients with large tumors are in bad clinical shape, so it is important to reduce the number of treatment sessions in order to reduce the risk of anesthetic procedures. On the other hand, costs are also a very important issue, as performing many sessions of treatment increases the cost of the procedure, and makes it rather impossible with our resources.

The fact that the tumors in the combined group were smaller could contribute to better responses achieved, but we also have to consider that the stages were higher. Tumor size rather than disease stage is likely to be a better prognostic factor in ECT, but this speculation is yet to be confirmed.

Further study is needed in order to determine in difficult cases whether practitioners should firstly try ECT with systemic bleomycin alone, or directly apply ECT with its combined systemic and local administration. Since the dose of bleomycin used is very low, the greatest risk of the ECT procedure lies in the application of anesthesia. Reducing anesthesia procedures outweighs the risk of adverse reactions related to the accumulated dose of bleomycin.^{23,24}

Acknowledgment

F. Maglietti holds a fellowship from the Consejo Nacional de Investigaciones Científicas y Técnicas

(CONICET), S. Michinski is CPA-CONICET, N. Olaiz and G. Marshall are researchers at CONICET. This work was supported by grants from CONICET (PIP 2012), Universidad de Buenos Aires (UBACyT 2014) and the International European Cooperation in Science and Technology (COST Action TD 1104). The funders had no role in the study, design, data collection and analysis, decision to publish, or preparation of the manuscript. This article was proof read by YasminTranslations.com

The paper was presented at the 1st World Congress on Electroporation and Pulsed Electric Fields in Biology, Medicine, and Food & Environmental Technologies, September 6 to 10, 2015, Portoroz, Slovenia (wc2015.electroporation.net) organized by COST TD1104 Action (www.electroporation.net), supported by COST (European Cooperation in Science and Technology)".

References

1. Yarmush ML, Golberg A, Serša G, Kotnik T, Miklavcic D. Electroporation-based technologies for medicine: principles, applications, and challenges. *Annu Rev Biomed Eng* 2014; **16**: 295-320.
2. Marty M, Sersa G, Garbay J, Gehl J, Collins C, Snoj M, et al. Electrochemotherapy - a simple, highly effective and safe treatment of cutaneous and subcutaneous metastases: results of ESOPE (European Standard Operating Procedures for Electrochemotherapy) study. *EJC Suppl* 2006; **4**: 3-13.
3. Mali B, Jarm T, Snoj M, Sersa G, Miklavcic D. Antitumor effectiveness of electrochemotherapy: a systematic review and meta-analysis. *Eur J Surg Oncol* 2013; **39**: 4-16.
4. Spugnini EP, Baldi F, Mellone P, Feroce F, D'Avino A, Bonetto F, et al. Patterns of tumor response in canine and feline cancer patients treated with electrochemotherapy: preclinical data for the standardization of this treatment in pets and humans. *J Transl Med* 2007; **5**: 48.
5. Cemazar M, Tamzali Y, Sersa G, Tozon N, Mir LM, Miklavcic D, et al. Electrochemotherapy in veterinary oncology. *J Vet Intern Med* 2008; **22**: 826-31.
6. Spugnini EP, Fanciulli M, Citro G, Baldi A. Preclinical models in electrochemotherapy: the role of veterinary patients. *Future Oncol* 2012; **8**: 829-37.
7. London CA. Abstract SY28-01: Spontaneous cancer in dogs: Opportunities for preclinical evaluation of novel therapies. *Cancer Res* 2011; **71**: SY28-01.
8. Spugnini EP, Dragonetti E, Vincenzi B, Onori N, Citro G, Baldi A. Pulse-mediated chemotherapy enhances local control and survival in a spontaneous canine model of primary mucosal melanoma. *Melanoma Res* 2006; **16**: 23-7.
9. Tamzali Y, Borde L, Rols M, Golzio M, Lyazrhi F, Teisse J. Successful treatment of equine sarcoids with cisplatin electrochemotherapy: a retrospective study of 48 cases. *Equine Vet J* 2012; **44**: 214-20.
10. Spugnini EP, Citro G, Dotsinsky I, Mudrov N, Mellone P, Baldi A. Ganglioneuroblastoma in a cat: a rare neoplasm treated with electrochemotherapy. *Vet J* 2008; **178**: 291-3.
11. Valpione S, Campana LG, Pigozzo J, Chiarion-Sileni V. Consolidation electrochemotherapy with bleomycin in metastatic melanoma during treatment with dabrafenib. *Radiol Oncol* 2015; **49**: 71-4.
12. Campana LG, Mocellin S, Basso M, Puccetti O, De Salvo GL, Chiarion-Sileni V, et al. Bleomycin-based electrochemotherapy: clinical outcome from a single institutional experience with 52 patients. *Ann Surg Oncol* 2009; **16**: 191-9.
13. Mir LM, Gehl J, Sersa G, Collins CG, Garbay JR, Billard V, et al. Standard operating procedures of the electrochemotherapy: instructions for the use of bleomycin or cisplatin administered either systemically or locally and electric pulses delivered by the Cliniporator TM by means of invasive or non-invasive electrodes. *EJC Suppl* 2006; **4**: 14-25.
14. Jain RK. Normalization of tumor vasculature: an emerging concept in antiangiogenic therapy. *Science* 2005; **307**: 58-62.
15. Padera TP, Stoll BR, Tooredman JB, Capen D, di Tomaso E, Jain RK. Pathology: cancer cells compress intratumour vessels. *Nature* 2004; **427**: 695.
16. Kumar V, Abbas AK, Aster JC. Robbins basic pathology. Elsevier Health Sciences; 2012.
17. Warren BA. The vascular morphology of tumors. In: Peterson HI, editor. *Tumor blood circulation: angiogenesis, vascular morphology and blood flow of experimental and human tumors*. Boca Raton FL: CRC Press Inc.; 1979. p. 1-47.
18. WHO handbook for reporting results of cancer treatment. Geneva, Switzerland: WHO Offset Publications; 1979; **48**: 22-7.
19. Jaroszeski M, Gilbert R, Perrott R, Heller R. Enhanced effects of multiple treatment electrochemotherapy. *Melanoma Res* 1996; **6**: 427-33.
20. Testori A, Tosti G, Martinoli C, Spadola G, Cataldo F, Verrecchia F, et al. Electrochemotherapy for cutaneous and subcutaneous tumor lesions: a novel therapeutic approach. *Dermatol Ther* 2010; **23**: 651-61.
21. Matthiessen LW, Johannesen HH, Hendel HW, Moss T, Kamby C, Gehl J. Electrochemotherapy for large cutaneous recurrence of breast cancer: a phase II clinical trial. *Acta Oncol* 2012; **51**: 713-21.
22. Sersa G, Cufer T, Paulin SM, Cemazar M, Snoj M. Electrochemotherapy of chest wall breast cancer recurrence. *Cancer Treat Rev* 2012; **38**: 379-86.
23. Jules-Elysee K, White D. Bleomycin-induced pulmonary toxicity. *Clin Chest Med* 1990; **11**: 1-20.
24. Cohen IS, Mosher MB, O'Keefe EJ, Klaus SN, De Conti RC. Cutaneous toxicity of bleomycin therapy. *Arch Dermatol* 1973; **107**: 553-5.